

# Dermatlas:An Online Collaborative Education Tool

C Lehmann, B Cohen

## Citation

C Lehmann, B Cohen. *Dermatlas:An Online Collaborative Education Tool*. The Internet Journal of Dermatology. 2001 Volume 1 Number 2.

DOI: [10.5580/1fe](https://doi.org/10.5580/1fe)

## Abstract

The World Wide Web was envisioned and designed as a shared information space for collaborative projects across geographical and institutional borders. However, in the area of medical education, the potential for collaboration has not yet been fully realized. One example of a successful collaborative educational project on the World Wide Web is the Dermatlas at Dermatlas.com or Dermatlas.org. It started as a static pediatric dermatology website and blossomed into an interactive multidisciplinary destination for physicians, fellows, residents, medical students, other health care professionals, parents and patients. We would like to describe the development, use, and growth of this rapidly expanding online resource.

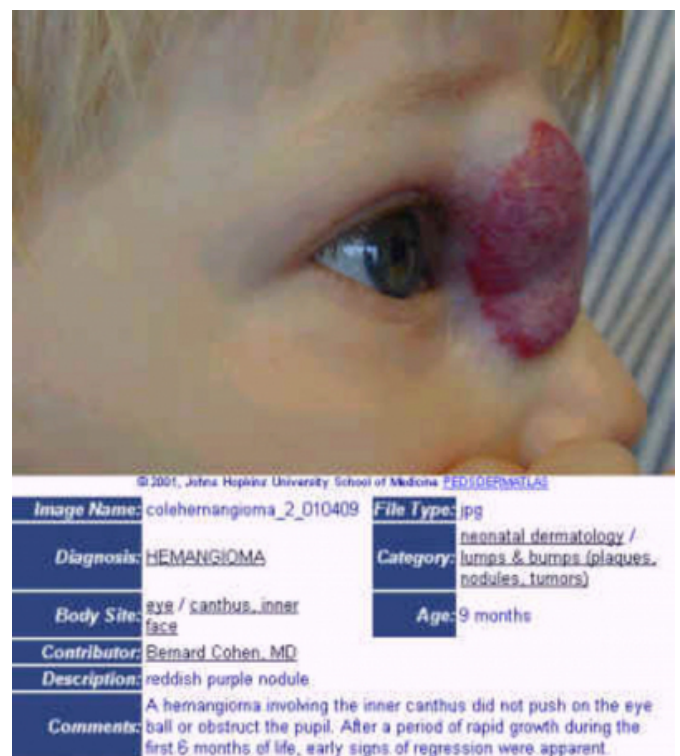
## DERMATLAS

The Dermatlas (2) was designed as a learning and reference tool for students, residents and physicians. Medical education in specialties like pathology (3) and dermatology (4) is dependant on image materials that students may review to understand and recognize the quality, pattern and extend of lesions. Educational research has demonstrated the impact of visual material on recall and retention of taught information (5). In the past web-based computer assisted learning has been demonstrated to be an effective medium for education in dermatology (6).

The Dermatlas was designed to provide high quality dermatology clinical and histologic images as well as detailed descriptions of the patient and the associated disease processes. Organized by disease categories and diagnosis, visitors may use Dermatlas to review images, learn about clinical findings or review pertinent disease specific information. (Figure 1) Visitors have multiple ways to find images of interest in the Dermatlas. Besides searching for category or disease in an alphabetized index list or pull-down menu, they may search by body area, age of patient, skin pigmentation, contributor, image name or any combination thereof. All text entries are completely indexed and allow keyword searches.

## Figure 1

Figure 1: Patient with facial hemangioma



All images that are found to be pertinent to a visitors query are displayed as thumbnails (small images) with accompanying information. By selecting the thumbnail (Figure 2), the user is served the full size image as well as additional information and thumbnails of related images (same patient or similar disease). Every diagnosis is

connected via hypertext link to a query of the National Library of Medicine's Pubmed for articles relevant to this diagnosis.

## Figure 2

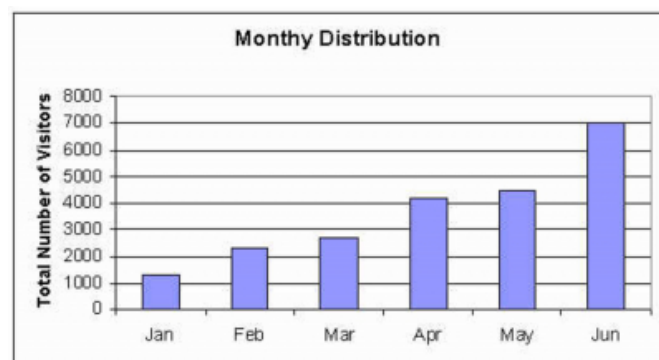
Figure 2: Partial results of a search for "Hemangioma";

	<p>Image Name: cunnahemangioma_1_010612</p> <p>File Type: jpg</p> <p>Diagnosis: HEMANGIOMA</p> <p>Category: neonatal dermatology / bumps &amp; bumps (plaques, nodules, tumors)</p> <p>Body Site: face / cheek</p> <p>Age: 4 months</p> <p>Contributor: Bernard Cohen, MD</p> <p>Description: red plaque overlying a compressible soft nontender subcutaneous mass</p> <p>Comments: This hemangioma grew quickly for 3 months after appearing at 1-2 weeks of age. For the last 3-4 weeks there was little growth. There was no visual impairment, so no treatment was initiated.</p> <p>Images with: hemangioma</p>
	<p>Image Name: childhemangioma_1_010612</p> <p>File Type: jpg</p> <p>Diagnosis: HEMANGIOMA</p> <p>Category: bumps &amp; bumps (plaques, nodules, tumors) / neonatal dermatology</p> <p>Body Site: eye lid / face</p> <p>Age: 3 months</p> <p>Contributor: Bernard Cohen, MD</p> <p>Description: soft compressible blue subcutaneous mass</p> <p>Comments: A rapidly growing hemangioma that appeared at 1 month of age decreased markedly with oral steroids (3 mg/kg/d prednisone). The left pupil is completely exposed, visual acuity was not impaired, and the steroids are being tapered.</p> <p>Images with: hemangioma</p>
	<p>Image Name: strima5</p> <p>File Type: jpg</p> <p>Diagnosis: HEMANGIOMA</p> <p>Category: bumps &amp; bumps (plaques, nodules, tumors) / neonatal dermatology</p> <p>Body Site: face / lip</p> <p>Age: 14 months</p> <p>Contributor: Cherry Arima, BS</p> <p>Description: red plaques with central clearing</p> <p>Comments: Although regression was well underway after her first birthday, she continued to experience episodes of stridor with tapering of the oral steroids below 0.5 mg/kg/day.</p>

Currently the Dermatlas contains more than 2100 images, 645 diagnosis and 58 categories and continues to grow rapidly. An average of 700 visitors come to the site every day (Figure 3) with the majority (75%) of visitors originating from locations in North America. Since its online debut in December 2000, more than 300,000 searches of the image database have been performed. The most commonly used keywords for image retrieval include eczema, hemangioma, scabies, psoriasis, measles, impetigo, acne, atopic dermatitis, varicella, kawasaki, rubella and herpes. We are able to record and monitor all user searches, which allows us to identify specific user interests and to add images to Dermatlas based on relevance to our users.

## Figure 3

Figure 3: Visitors to Dermatlas by month



What differentiates Dermatlas from other resources is the speed and ease of its development, its pace of growth, and

most of all its collaborative nature and the addition of online contributors and editors. The website was developed within 2 weeks and expanded from 30 original images to over 1,000 images in 6 months. Initially most of the images were added by Dr. Cohen. However, the proportion of images from other contributors at Johns Hopkins, nationally, and internationally has grown quickly. Providing from the onset a critical mass of images increased the credibility of the Dermatlas and helped to convince potential contributors to submit their images. Parents and patients have also actively contributed to the website by transmitting digital images and allowing the publication of sequential images demonstrating the course of cutaneous lesions such as hemangiomas, xanthogranulomas, and congenital nevi. These images provide parents and patients with means to assess clinical progress by accessing the images online. They also can also be used to counsel parents of other children and allow students to see the natural progression of skin lesions over weeks and months.

Dermatlas was developed using a database design enabling us to continuously update the Dermatlas with new images without the need for any additional programming, link management or page updating. This design frees the developer (CUL) from maintenance tasks and allows him to continuously add novel features.

The pages of Dermatlas are generated automatically every time a user visits the site based on the most current information contained in the database. Any addition or change to the database is instantly available on the web site. A series of simple web forms allows potential contributors to provide information about themselves and the image they would like to submit. They can then upload the image to our server where it is processed. The database entry for any image submitted this way does not become active until it was approved by one of the editors.

An additional feature of the Dermatlas is the Quiz. If a user selects this mode, an image is randomly selected from the database (no duplications during a session) and displayed. The user is offered a choice of up to 20 multiple diagnosis options (extended multiple choice design) based on the body site. Once a user selects an answer, it is evaluated for correctness and he has the option to review the correct answer, to retry or to move on to the next image. As long as a user stays in the quiz mode, the number of questions tried and the number of correct answers are tracked and stored in a separate database.

During the last 2 months we have appointed special editors for dentistry, dermatopathology, oral pathology, and dermatology resident clinic, and we recruiting additional editors for areas such as neonatology, dermatimmunology, and genodermatology. We are in the process of developing an interactive continuing medical education (CME) program that will allow participants to view a series of cases and answer questions about them online using images from our database and/or to contribute their own CME cases to the database.

## **CONCLUSION**

In summary, using a dynamic design based on a database approach, we quickly generated an educational tool, which has been well received by a large and diverse audience. Allowing editors and contributors to manipulate the database resulting in immediate changes in the web page resulted in fast growth, up-to-date content as well as significant satisfaction for contributors who can review their submissions immediately after the database has been updated.

The expanding database, quiz, and planned CME cases provide a good review for students, residents, fellows, and clinicians in pediatrics, medicine, dermatology, pediatric

dermatology, dermatopathology, and oral pathology. Parents and patients can use Dermatlas as an educational resource and as a site to follow their own skin lesions or the lesions of their children.

## **CORRESPONDENCE TO**

Christoph U. Lehmann, MD Assistant Professor Department of Pediatrics Johns Hopkins University 600 N. Wolfe St., CMSC 210 Baltimore, MD 21287-3200 Tel.: 410-955-4582 Fax: 410-955-0298 E-Mail: clehmann@jhmi.edu

## **References**

1. Moschovitis CJP, Poole H, Schuyler T, Senft TM. History of the Internet: A Chronology, 1843 to the Present. Santa Barbara, Calif.: ABC-CLIO, 1999]
2. Lamberg L. Advances in Pediatric Dermatology. JAMA, April 25, 2001; 285(16): 2066
3. Kronz JD, Silberman MA, Allsbrook WC Jr, Bastacky SI, Burks RT, Cina SJ, et al. Pathology residents' use of a Web-based tutorial to improve Gleason grading of prostate carcinoma on needle biopsies. Hum Pathol. 2000 Sep;31(9): 1044-50.
4. Hartmann AC, Cruz PD Jr. Interactive mechanisms for teaching dermatology to medical students. Arch Dermatol. 1998 Jun;134(6):725-8.
5. Dwyer FM. Strategies for Improving Visual Learning. State College, Pa: Learning Services; 1978;1-20
6. Curran VR, Hoekman T, Gulliver W, Landells I, Hatcher L. Web-based continuing medical education. (II): Evaluation study of computer-mediated continuing medical education. J Contin Educ Health Prof. 2000 Spring;20(2):106-19.

**Author Information**

**Christoph U Lehmann, MD**

Department of Pediatrics, Eudowood Neonatal Pulmonary Division, Johns Hopkins University School of Medicine

**Bernard A Cohen, MD**

Department of Pediatrics, Division of Pediatric Dermatology, Johns Hopkins University School of Medicine