

Adenomyosis With Extremely Elevated CA 125 Levels

S Goh, N Chua, B Chern

Citation

S Goh, N Chua, B Chern. *Adenomyosis With Extremely Elevated CA 125 Levels*. The Internet Journal of Gynecology and Obstetrics. 2008 Volume 10 Number 2.

Abstract

Raised CA 125 levels have been shown to be associated with various etiologies, notably ovarian cancer and endometriosis. We report a case of adenomyosis in a 53 year-old woman who presented with menorrhagia. The uterus was enlarged and she had a preoperative CA 125 level of > 6000 IU/ml. A total abdominal hysterectomy and bilateral salpingoophorectomies was done with an intraoperative frozen section. It showed adenomyosis and paraffin sections of the specimen confirmed no malignancy. The extremely elevated CA 125 level returned to the normal range postoperatively.

Paper was presented at The 9th World Congress of Endometriosis, Maastricht, The Netherlands, 2005.

CASE REPORT

Raised CA 125 levels in adenomyosis are very common and should be considered an important differential in a patient who presents with a palpable pelvi-abdominal mass. Radiology investigations are helpful in making the diagnosis. However, most patients with adenomyosis also have concurrent ovarian cysts, mostly endometriotic in nature. We describe a patient who presented with menorrhagia and extremely elevated CA 125 levels.

CASE SUMMARY

A 53 year-old Chinese lady, Para 2, presented with 2 months' duration of irregular, painful and heavy menses. Her previous medical and surgical history included hypertension, hyperlipidemia and postpartum sterilization. On examination, she had an enlarged uterus of 20 weeks' size and her cervix was healthy. A pap smear done was negative for dyskaryotic or malignant cells. The ultrasound scan of the pelvis showed an enlarged uterus, measuring 15.7x11.0x9.8cm, with the anterior uterine wall markedly thickened and inhomogenous with cystic spaces seen suggestive of adenomyosis. The endometrial thickness was 23mm with a poorly defined outline suggestive of either hyperplasia or neoplasia. There was a 3.6cm left ovarian cyst and the right ovary was not seen. Serial serum CA 125 ranged from 567.9 to 6675.5 IU/ml (Normal reference ranges = 0-35 IU/ml). A hysteroscopy was done and a directed endometrial sampling showed simple endometrial hyperplasia without atypia, with superimposed secretory

changes.

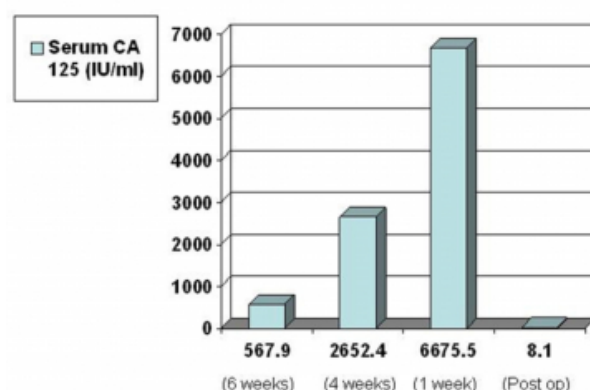
The patient was offered a total abdominal hysterectomy with bilateral salpingoophorectomies (TAHBSO) for adenomyosis and simple endometrial hyperplasia. The patient was advised regarding the need for an intraoperative frozen section, with a view for a full staging if ovarian or uterine malignancy was confirmed.

Intraoperatively, the uterus was 17cmx15cmx10cm, with the anterior wall myometrium of 10cm in maximum dimension, and showed haemorrhagic cystic areas of adenomyosis. A 2cm left ovarian cyst was noted and the right ovary was normal. Frozen section of the uterus, cervix, ovaries and tubes showed adenomyosis.

The patient recovered uneventfully from the surgery and was discharged on postoperative Day 3. The final histology confirmed adenomyosis with a large adenomyoma and a benign serous cystadenoma of the left ovary. There was no endometrial hyperplasia or malignancy in the operative specimen. A CA 125 level was done at 2 months' postoperatively showed a decline to normal values (Fig. 1).

Figure 1

Fig. 1 Patient's CA 125 levels at 6, 4 and 1 week(s) preoperatively (3 values) and at 2 months' postoperatively



DISCUSSION

CA 125 is a tumour marker, used commonly for management in benign as well as malignant gynaecological conditions. It is present in 80% of epithelial ovarian cancers and has a proven use in the treatment and subsequent follow up in ovarian cancer management. However, in premenopausal women, it is known to be elevated in the presence of endometriosis, pelvic inflammatory disease, pregnancy, smoking, tuberculosis and cirrhosis of the liver¹. High levels of CA125 over 1,000 IU/ml, may be showed in other gynecologic conditions with no malignancy. So, other clinical and imaging data are helpful in differentiating these diagnoses in these patients². Patients with adenomyosis have a higher CA125 positive rate than those with leiomyoma and for these patients with adenomyosis, the CA125 levels are positively correlated with uterine size. Thus, serum CA125 assay is of great assistance to the diagnosis of uterine adenomyosis as well as to the differential diagnosis between adenomyosis and leiomyoma of uterus³. There have been previous multiple case reports of extremely raised CA 125 levels with ovarian endometriotic cysts^{2,3,4,5,6,7,8,9} and one case of adenomyosis¹⁰. However, this is the first case reported of extremely elevated serum CA 125 (of more than 6000 IU/ml) from adenomyosis alone. The patient had no concomitant ovarian endometriosis, noted intraoperatively as well as on paraffin sections of the final TAHBSO specimen.

A previous retrospective review¹¹ of diagnoses of patients with raised serum CA 125 showed that gynecologic cancers, nongynecologic cancers and non-malignant conditions constituted 89%, 7% and 3% of diagnoses respectively in patients with serum CA 125 of more than 1000 IU/ml.

Hence, subspecialty consultation should be considered before embarking on surgery, as the possibility of malignancy and need for staging should ideally be discussed with the patient prior to surgery. The accuracy of using only CA-125 testing for diagnosis is still limited. Serum CA-125 testing can be done during initial screenings of women with possible endometriosis¹².

CONCLUSION

This case illustrates that adenomyosis can be associated with extremely elevated and rapidly rising CA 125 levels, akin to that of ovarian cancer, and the possibility of uterine and ovarian malignancies must always be considered during counseling of the patient.

CORRESPONDENCE TO

Dr Shen Li GOH Associate Consultant, Department of Obstetrics and Gynaecology Basement One, Women's Tower, KK Women's and Children's Hospital, 100 Bukit Timah Road, Singapore 229889 Email: goh.shen.li@kkh.com.sg Tel: +65 62934044 Facsimile: +65 62986343

References

1. Meden H, Fattahi-Meibodi A. CA 125 in benign gynecologic conditions. *Int J Biol Markers*. 1998; 13: 231-7.
2. Ghaemmaghami F, Karimi Zarchi M, Hamed B. High levels of CA125 (over 1,000 IU/ml) in patients with gynecologic disease and no malignant conditions: three cases and literature review. *Arch Gynecol Obstet*. 2007; 276: 559-61.
3. Zhou Y, Wu B, Li H. The value of serum CA125 assays in the diagnosis of uterine adenomyosis. *Zhonghua Fu Chan Ke Za Zhi*. 1996; 31: 590-3.
4. Phupong V, Chen O, Ultchawadi P. High level of CA 125 due to large endometrioma. *J Med Assoc Thai*. 2004; 87: 1108-11.
5. Shiau CS, Chang MY, Chiang CH, et al. Ovarian endometrioma associated with very high CA-125 levels. *Chang Gung Med J*. 2003; 26: 695-9.
6. Yilmazer M, Sonmezer M, Gungor M, et al. Unusually elevated serum carbohydrate antigen 125 (CA 125) and CA 19-9 levels as a result of unruptured bilateral endometrioma. *Aust N Z J Obstet Gynecol*. 2003; 43: 329-30.
7. Gasmen A, Karaca M, Tarakcioglu M. A ruptured ovarian endometrioma mimicking ovarian malignancy: case report. *Eur J Gynecol Oncol*. 2003; 24: 445-6.
8. Kashyap RJ. Extremely elevated serum CA 125 due to endometriosis. *Aust N Z J Obstet Gynecol*. 1999; 39: 269-70.
9. Kahraman K, Ozguven I, Gungor M, Atabekoglu CS. Extremely elevated serum CA-125 level as a result of unruptured unilateral endometrioma: the highest value reported. *Fertil Steril*. 2007; 88: 968.
10. Kammerer-Doak DN, Magrina JF, Nemiro JS, Lidner TK. Benign gynecologic conditions associated with a CA-125 level > 1000U/ml. A case report. *J Reprod Med*. 1996; 41: 179-82.
11. Eltabbakh GH, Belinson JL, Kennedy AW, et al. Serum

CA-125 measurements > 65U/mL. J Reprod Med 1997; 42: 617-24.
12. Kitawaki J, Ishihara H, Koshiba H, et al. Usefulness and

limits of CA-125 in diagnosis of endometriosis without associated ovarian endometriomas. Hum Reprod. 2005; 20:1999-2003.

Author Information

Shen Li Goh, MBBS(S'pore), MRCOG(UK), FAMS (O & G)

Associate Consultant, Department of Obstetrics and Gynaecology, KK Women's and Children's Hospital

Natalie WL Chua, MBBS(S'pore)

Medical Officer, Department of Obstetrics and Gynaecology, KK Women's and Children's Hospital

Bernard SM Chern, MBBS(S'pore), M Med (O&G), MRCOG (UK), MRANZCOG, FAMS

Head and Senior Consultant, Department of Obstetrics and Gynaecology, KK Women's and Children's Hospital