

Habitual Centric: A Case Report

Manisha, N Kathuria, A Gupta, N Gupta

Citation

Manisha, N Kathuria, A Gupta, N Gupta. *Habitual Centric: A Case Report*. The Internet Journal of Geriatrics and Gerontology. 2010 Volume 6 Number 2.

Abstract

Continuous wearing of an ill fitting denture has a negative effect on residual ridge form due to resorption. Wearing a complete denture that functions poorly and impairs masticatory function could be a negative factor with regard to maintenance of adequate muscle function. Prosthodontic management of such a patient is a challenging task. The present case report discusses the sequelae of wearing such a denture and its management procedure.

INTRODUCTION

Continuous wearing of ill fitting complete denture leads to excessive residual ridge resorption(1) and occlusal wear resulting in positioning the mandible forward in relation to the maxilla even producing cross bite relationship. Prosthodontic management of such patients is a challenging task due to limitations of restoring lost vertical height, recording accurate centric relation and providing adequate stability.

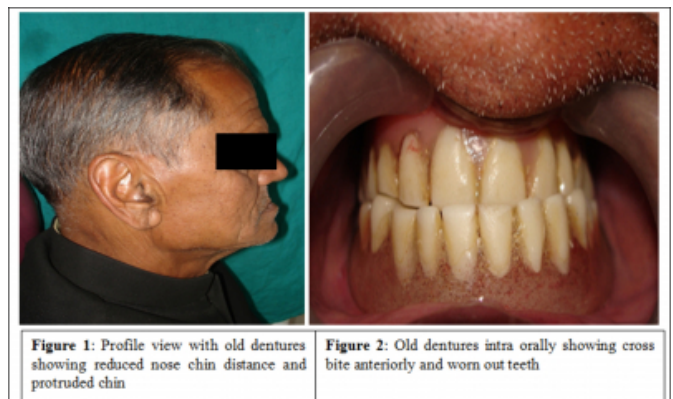CASE REPORT

A 62-year old male reported with the complaint of inability to chew with the existing dentures to the Department of Prosthodontics, D.J. College of Dental Sciences and Research, Modinagar. The patient had worn successively 2 sets of dentures day and night in a span of 25 years. The first one was worn for about 10 years and the existing dentures were being used for the past 15 years.

Extra Oral Examination with Dentures (Figure 1) revealed reduced nose chin distance, protruded chin, lack of lip support in maxillary region ,partially everted lower lip, minimal visibility of teeth during speech and use of tongue to retain the maxillary denture during function. The physiologic age of the patient appeared to be 70 plus.

Intra Oral Examination with Dentures (Figure 2) showed 3mm short posterior extension of the maxillary denture. The mandibular denture was short in buccal, lingual and retromolar pad areas with completely worn out occlusal surfaces, about 3mm cross bite relationship of the dentures in the anterior region and inter occlusal gap of about 11mm.

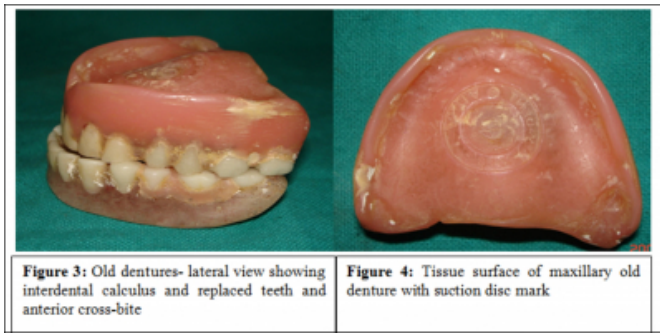
Figure 1



Intra Oral Examination without Dentures revealed grossly resorbed mandibular ridge, flabby maxillary ridge in the anterior region, depression mark of the suction disc in the palate, no redness of oral mucosa inspite of wearing dentures throughout day and night over a protracted period of about 25 years

Examination of the Dentures Showed (Figure 3 & 4) replacement of few teeth in mandibular denture and unduly heavy dentures

Figure 2



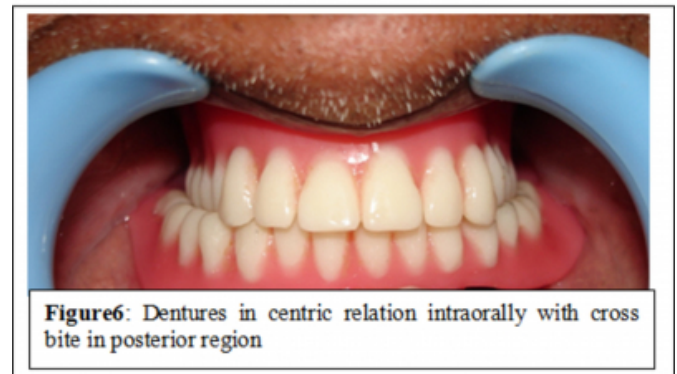
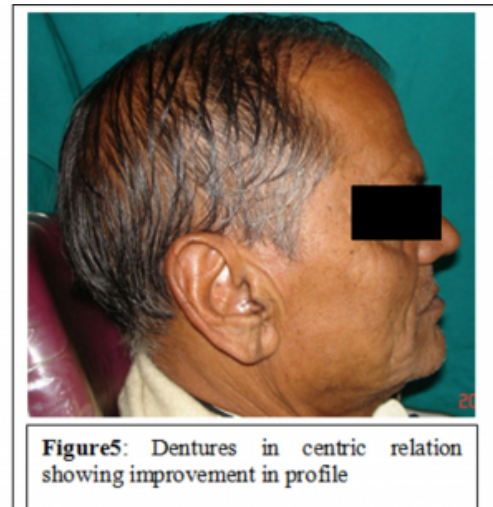After evaluation and diagnosis, new complete dentures were planned to provide masticatory efficiency, retention and stability, to restore vertical height, correct centric relation and eliminate the cross bite relation in the anterior region

PROCEDURE

The impression of the resorbed mandibular ridge using a lead tray well extended sublingually in the premylohyoid area intentionally limiting some tongue movement within permissible limits to overcome the problem of retention was made in impression compound. The maxillary impression was made in irreversible hydrocolloid to record flabby tissue in the resting state.

Border moulding was done and final impressions were made in zinc oxide eugenol impression paste. Centric relation was recorded with 8mm interocclusal gap in the most retruded position of the mandible which was achieved easily. Teeth arrangement was done in crossbite relation in posterior segment to conform to ridge relation and try- in was done. The dentures were processed, finished, polished and inserted giving relevant instructions. (Figures 5 & 6)

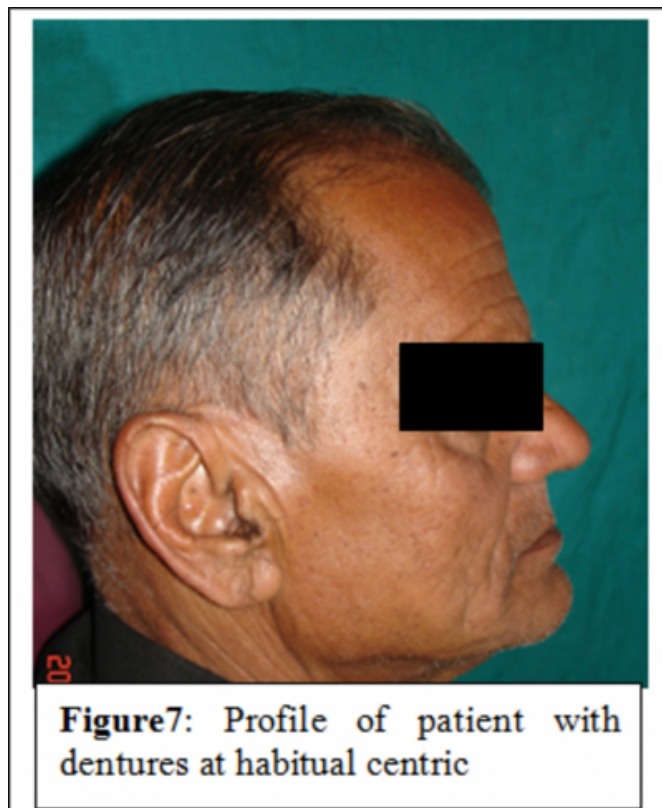
Figure 3



Post insertion adjustments were made at 24 hour, one week and 3 weeks. The patient kept complaining about his inability to chew from posterior teeth. Occlusal adjustments were made to provide some freedom in centric. 6 weeks post insertion when the patient again complained of inability to chew; it was decided to reconstruct the lower denture at patient's habitual closing position and further restoring the vertical relation of occlusion providing an interocclusal gap of 4mm only

At 24 hour post insertion, the patient was comfortable, satisfied and happy with new dentures and almost immediately started chewing with it without any need for further adjustments. (Figure 7)

Figure 4



DISCUSSION

As the dentures age, the teeth wear and the residual ridges that support the denture resorb, causing the distance between the nose and chin to collapse(2-9). As constant wearing of posterior denture teeth continues, creating space between them leading to premature contact on the anterior teeth bringing the lower jaw come forward. The present patient also suffered from the same sequelae of denture wearing. To add to this, day and night wearing of dentures also could have led to severe resorption of the residual ridges. The denture flanges were already short, so dentures did not appear overextended inspite of severe ridge resorption.

Usually, continuous wearing of dentures leads to redness of underlying oral mucosa which was not seen in the patient which may be due to lack of intimacy of tissue contact due to excessive resorption leading to lack of retention which was evident as patient kept using his tongue to retain the dentures during function. For the same reason, there appeared no need to provide rest to the tissues which is usually required prior to construction of new dentures.

The vertical was slightly increased initially as too much decrease in interocclusal gap would not have been tolerated by the patient. Also the leverage action would have

compromised the stability of the lower denture. The interocclusal gap was reduced further to 4mm on the premise that by this time patient got acclimatized to the new vertical which is also related to chewing efficiency.

Patient was initially informed that dentures will be made at correct jaw relation and was convinced to cooperate. So the dentures were made in the most retruded position which could be easily established. However, he could not chew efficiently inspite full cooperation and giving almost 6 weeks during which twice he was persuaded to chew on back teeth with conscious effort.

In complete dentures, centric relation and occlusion are made to coincide and many patients adapt to this new position¹. In this case, the patient was able to retrude the mandible easily into centric relation by command or manually but, due to long term denture wearing, was unable to adapt to the retruded position. Consequently, new mandibular denture had to be made at his habitual closing position with mostly restored vertical which proved very satisfactory.

SUMMARY AND CONCLUSION

In long term ill fitting denture wearing patients, the muscles are sometimes unable to adapt to the new position provided, necessitating reconstruction of the dentures at habitual position only, though effort should always be made to make centric relation and centric occlusion coincide.

References

1. Zarb Bolender: sequelae caused by wearing complete dentures, Prosthodontic treatment for edentulous patients;12th edition; 2004
2. Atwood DA. Some clinical factors related to rate of resorption of residual ridges. J Prosthet Dent. 1962; 12:441-444.
3. Tallgren A. The effect of denture wearing on facial morphology. A 7-year longitudinal study. Acta Odontol Scand. 1967; 25:563-592.
4. Carlsson GE, Persson G. Morphologic changes of the mandible after extraction and wearing of dentures. Odontol Rev. 1967; 18:27-54.
5. . Tallgren A. Positional changes of complete dentures. A 7-year longitudinal study. Acta Odontol Scand. 1969; 27:539-561.
6. Tallgren A. Alveolar bone loss in denture wearers as related to facial morphology. Acta Odontol Scand. 1969; 28:251-270.
7. Tallgren A, Lang BR, Walker GF, Ash MM Jr. Roentgen cephalometric analysis of ridge resorption and changes in jaw and occlusal relationships in immediate complete denture wearers. J Oral Rehabil. 1980; 7:77-94.
8. Tuncay OC, Thomson S, Abadi B, Ellinger C. Cephalometric evaluation of the changes in patients wearing complete dentures. A 10-year longitudinal study. J Prosthet Dent. 1984; 51:169-180.

9. Tallgren A, Lang BR, Miller RL. Longitudinal study of soft tissue profile changes in patients receiving immediate

complete dentures. Int J Prosthodont. 1991; 4:9–16.

Author Information

Manisha, M.D.S Prosthodontics, including Crown, Bridge and Implantology

Senior Lecturer , Dept. of Prosthodontics, PDM Dental College and Research Institute

NIDHI Kathuria, M.D.S Prosthodontics

Senior Lecturer, Dept. of Prosthodontics, PDM Dental College and Research Institute

Ajay Gupta, M.D.S Prosthodontics

Dept. of Prosthodontics, DJ College of Dental Sciences and Research

Neelam Gupta, M.D.S Prosthodontics

Reader, Dept. of Prosthodontics, PDM Dental College and Research Institute