Cutaneous Mucinosis As Metastatic Lesions In A Young Woman With Visceral Malignancy

R Makkar, A Monga, A Gupta, S Jain, S Jain

Citation

R Makkar, A Monga, A Gupta, S Jain, S Jain. *Cutaneous Mucinosis As Metastatic Lesions In A Young Woman With Visceral Malignancy*. The Internet Journal of Dermatology. 2002 Volume 2 Number 1.

Abstract

Mucigenous skin eruptions are an exceedingly rare form of cutaneous metastasis and have been reported in very few cases. We hereby report a young woman who presented with multiple "mucinous" papulonodular eruptions on the skin as evidence of distant metastasis from an unknown visceral primary site. The presence of such lesions in cancer patients may be a sign of widespread metastases foreboding a grave prognosis.

Place of work: Sitaram Bhartia Institute of Science and Research, New Delhi, India

CASE REPORT

A 31-year-old woman was brought to the emergency in a poor general condition with history of generalized weakness, anorexia, weight loss and progressive distension of abdomen for 2-3 months. She had developed multiple skin nodules all over the body over last 2 months that were subcutaneous papulonodular eruptions. The eruptions, initially misdiagnosed as ‘xanthomas', were chiefly distributed over face, neck, chest, back, arms and thighs (Figure 1 and 2).

Figure 1

Figure 1 and 2: Multiple metastatic subcutaneous fleshy ‘mucigenous' nodular eruptions seen over the skin of the face and neck.

Figure 2

The lesions were shiny in appearance, firm and fleshy in consistency and were mildly tender to touch. The overlying skin was dry and not fixed to the underlying tissue. She also had multiple firm but discrete cervico-axillary lymph nodes. Chest and abdominal examination showed bilateral pleural effusion and ascites, respectively. The pleural fluid and ascitic fluid examination, both showed atypical cells suggestive of internal malignancy. A CT scan of the abdomen revealed bilateral tubo-ovarian masses along with the ascites. Cervical lymph node biopsy (Figure 3) suggested metastatic mucin-secreting carcinoma lymph node.

Figure 3

Figure 3: Lymph node biopsy showing tumor cells, which have either vacuolated or pale mucin filled cytoplasm. Many signet ring cells are seen and occasional mitoses are present. Also seen are tiny pools of mucin along with the tumor cells. Normal lymph node tissue is seen at the right upper corner (Hematoxylin and Eosin stain, x 250).

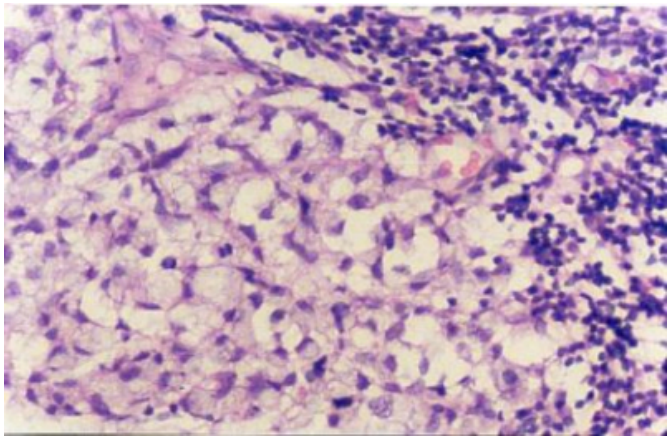

Biopsy from the skin nodule (Figure 4 and 5) also showed carcinomatous deposits of ‘mucin' type. The raised CA-125 (52 U mL^{-1} , normal <30 U mL^{-1}) levels in the presence of tubo-ovarian masses suggested a primary mucinous carcinoma of the ovary, but a metastatic mucin-secreting cancer from the gastrointestinal tract (Krukenberg tumor) could not be ruled out in view of bilateral ovarian involvement. The disease showed a very rapid and fulminant course and the patient expired on the third day of admission. An autopsy to look for the primary site of the malignancy was refused by the husband.

Figure 4

Figure 4: Section from a skin nodule biopsy showing tumor cells with pale cytoplasm as if containing mucin. The nuclei are shifted to one side. Also in some areas colloid like spaces of mucin are present. Many signet ring cells are seen in the deeper dermis (arrow, Hematoxylin and Eosin stain, x 150). The histological picture is suggestive of carcinomatous deposits of mucin type.

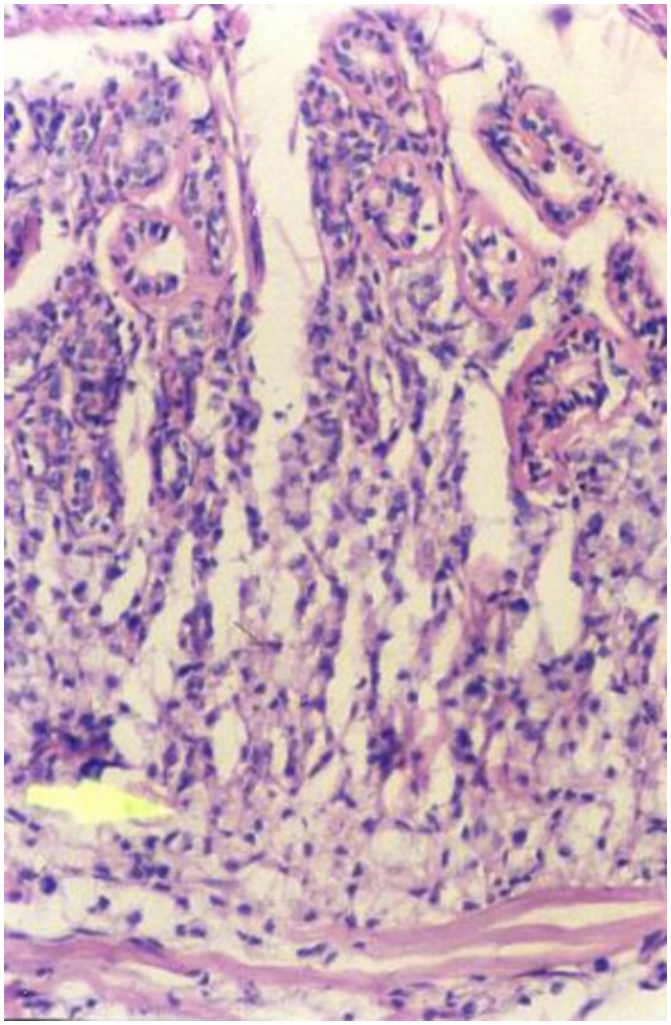

Figure 5

Figure 5: Biopsy of the skin nodule showing classical signet ring cells (Hematoxylin and Eosin stain, x 250).

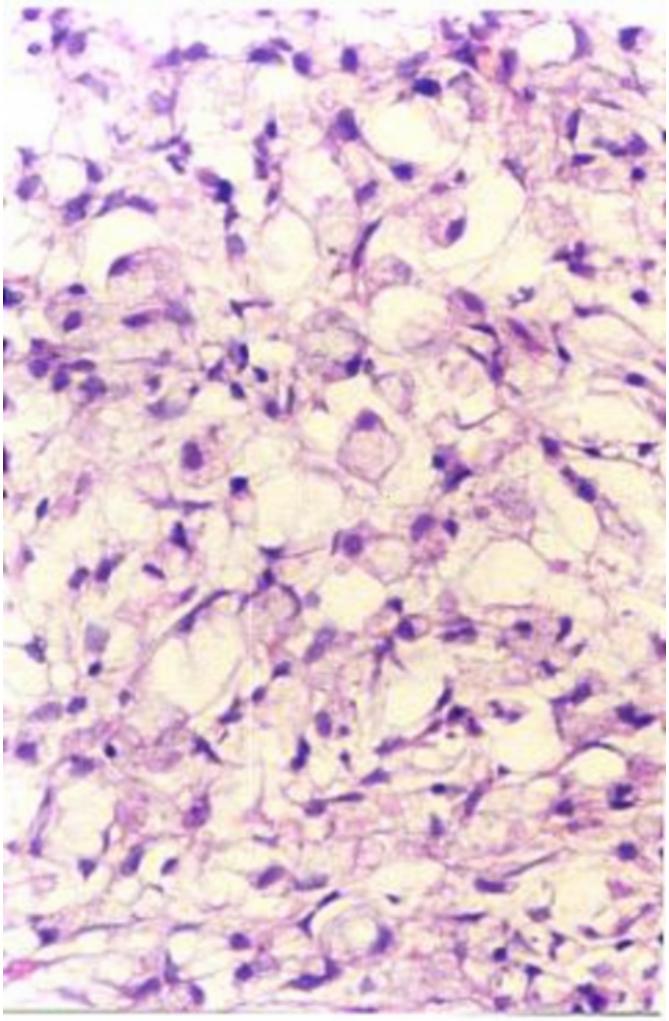

DISCUSSION

Cutaneous mucinoses are a heterogenous group of conditions in which ‘mucin' accumulates in the skin. They have been reported in the past in diseases such as lichen-myxedematosus, lupus-erythematosus, scleredema, dysthyroidotic mucinoses (mucinoses associated with thyroid diseases), reticular erythematous mucinosis, acral persistent mucinosis, juvenile cutaneous mucinosis, cutaneous mucinosis of infancy, cutaneous toxic-oil mucinoses, neuropathy-related cutaneous mucinosis, urticaria-like mucinosis, hereditary mucinous histiocytosis and primary mucinous skin (sebaceous and sweat glands) carcinomas. [1,2]

The appearance of ‘mucigenous skin deposits' as a sign of internal malignancy is an extremely rare phenomenon (given the fact that skin is the site of metastases in only 3-5% cases

among those with any evidence of metastases). [3] Though, such lesions have been reported in very few cases in the past [4,5], to the best of our abilities, we could not find any clinical picture/photograph showing 'metastatic' ‘mucigenous skin lesions' in the medical literature.

The new occurrence of these lesions may be a sign of ‘mucin-producing' ovarian or gastrointestinal malignancy. We believe that every practitioner should be aware of this possibility in order to make a timely diagnosis of the underlying malignancy as the presence of such lesions in these patients may entail a very poor prognosis.

CORRESPONDENCE TO

Ravinder PS Makkar, MD D-40, Preet Vihar, New Delhi-110092, India Tel: 91-11-22545183, Fax: 91-11-23352701 E-mail: makkar_r@yahoo.com

References

1. Steigleder GK, Kuchmeister B. Cutaneous mucinous deposits. J Cutan Pathol 1985; 12(3-4): 334-47.
2. Rongioletti F, Rebora A. Cutaneous mucinosis. Ann Dermatol Venereol. 1993; 120(1): 75-87.
3. Krathen RA, Orengo IF, Rosen T. Cutaneous metastasis: a meta-analysis of data. South Med J. 2003; 96(2): 164-7.
4. Merimsky O, Chaitchik S, Inbar M. Skin metastasis of ovarian cancer: report of three cases. Tumori 1991; 77(3): 268-70.
5. Stolp A, Wiesner M. Mucigenous skin metastases of a gastric adenocarcinoma. Dermatol Monatsschr 1975; 161(1): 46-51

Author Information

Ravinder Makkar, MD
Department of Medical Assistance, International SOS

Amitabh Monga, MD
Department of Medicine, Tan Tock Seng Hospital

Ajay Gupta, MD
Dept of Medicine, Sitaram Bhartia Institute of Science & Research

SK Jain, DM
Dept of Gastroenterology, Sitaram Bhartia Institute of Science and Research

Shama Jain, MD
Dept of Pathology, Maulana Azad Medical College