

# Dysgerminoma arising in Swyer Syndrome

M Tayfur, R Kocabas, A Kaygisiz, S Tiryaki, M Polat, K Cefle

## Citation

M Tayfur, R Kocabas, A Kaygisiz, S Tiryaki, M Polat, K Cefle. *Dysgerminoma arising in Swyer Syndrome*. The Internet Journal of Pathology. 2007 Volume 7 Number 2.

## Abstract

Swyer syndrome is a pure gonadal dysgenesis associating with 46 XY karyotype and primary amenorrhea in a phenotypic female. In this syndrome, there is an abnormality in testicular differentiation. Patients with specific disorders in sexual differentiation have an increased risk for development of genital malignancies.

A 23 years old female admitted to the hospital with the complaint of primary amenorrhea. The clinical and laboratory investigations revealed Swyer syndrome and dysgerminoma developed from left ovary. Left gonadectomy was applied to the patient. There was neither a family history of primary amenorrhea nor genital tract tumor.

The early diagnosis of the patients with Swyer syndrome is very important because of the increased risk for the development of malignancy. The early surgical treatment and if required, convenient chemotherapy will lengthen survival.

## INTRODUCTION

Swyer syndrome is a pure gonadal dysgenesis associating with 46 XY karyotype, primary amenorrhea, presence of female internal genital tract and bilateral streak gonads in a phenotypic female (1). There is a testicular differentiation abnormality in Swyer syndrome. The patients are characterized by impuberism with a female phenotype without genital ambiguity and stigmas of Turner syndrome (2). They have also elevated gonadotropins and hypoplastic gonads without germ cells (3). The incidence of Swyer syndrome is 1:100.000 (4). The diagnosis is usually made at adolescence when the primary amenorrhea is investigated (1).

Patients with specific disorders in sexual differentiation have an increased risk for development of genital malignancies. The patients with Swyer Syndrome have streak gonads and an age related increased risk for development of malignancies.

The most frequent malignant genital tumors in Swyer syndrome are gonadoblastoma and dysgerminoma. The calculated risk of malignancy in such patients is approximately 30% (3, 5, 6). Additionally, 5% of dysgerminomas are developed in patients with phenotypically female and 46 XY karyotype (7). We report here a rare case of dysgerminoma with Swyer syndrome in a 23 years old female.

## CASE PRESENTATION

A 23 year old virgin female admitted to the hospital with the complaint of primary amenorrhea. She was 173 cm height and 52 kg weight. Physical examination revealed a female with normal external genitalia. The developments of breasts and vagina were hypoplastic. The pubic and axillary hairs were sparse. The serum levels of LH, FSH, estradiol and testosterone were out of the reference ranges; but, the levels of tumor markers were within the normal ranges (Table 1).

## Figure 1

Table 1 : Serum hormone and tumor markers levels.

Tests	Results	Flags	Reference Values	Units
LH	44.6	High	0.8 – 7.6 *	mIU/mL
FSH	>170	High	0.7 – 11.1 *	mIU/mL
Estradiol	< 20.0	Low	20 – 534 *	pg/mL
Testosterone	0.361	Low	2.8 – 8.0 *	ng/dL
beta-hCG	0.677	Normal	0 – 2.7	mIU/mL
AFP	1.44	Normal	0 – 7	ng/mL
CA 125	8.98	Normal	0 – 35	U/mL

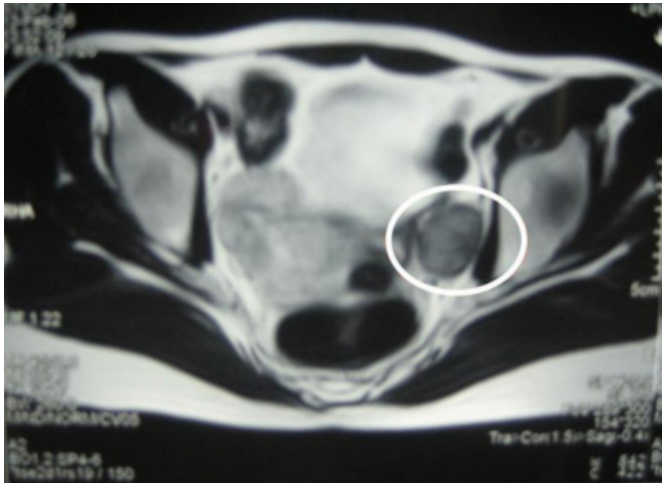\*References values changes to sex and menstrual cycle.

Thus, the patient was thought to be simple hormonal insufficiency and applied hormonal replacement therapy [0.15 mg of levonorgestrel and 0.03 mg of ethinyl estradiol (Lo-Ovral) for three months and then 17β-estradiol and noretisteronacetat (Trisequens) for six months]. The menstrual bleeding was obtained after hormonal replacement therapy which was fairly scanty with respect to normal bleeding quantity and the physicians decided to perform further investigation.

The pelvic ultrasonography showed a solid mass measured 34x27mm in left pelvis. The right gonad couldn't have been found. There was a hypoplastic uterus with a rudimentary cervix. The magnetic resonance image (MRI) of the pelvis showed a solid hypointens mass measured 35x31x26 mm in the left pelvis (Image 1) and a hypoplastic uterus (Image 2).

**Figure 2**

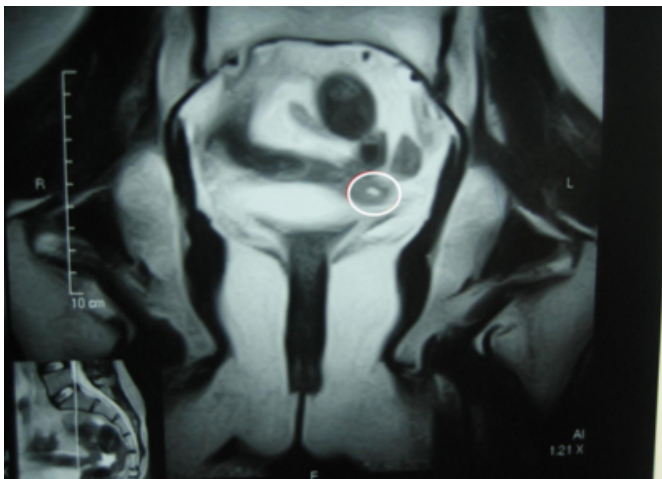
Image 1 : MRI, gonadal mass within the left pelvis (in white circle).



The uterus was 20x16x15 mm in dimension. There was not any image about right gonadal tissue.

**Figure 3**

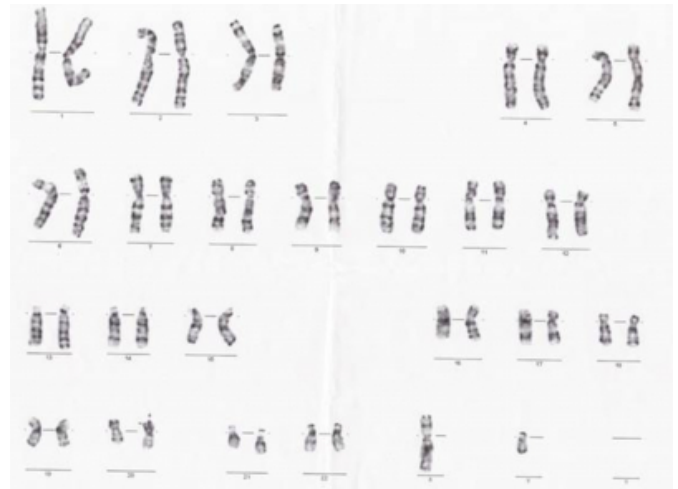
Image 2 : MRI, rudimentary uterus (in white circle).



A karyotype analysis was performed in Istanbul Medical Faculty which revealed a 46 XY complement (Image 3).

**Figure 4**

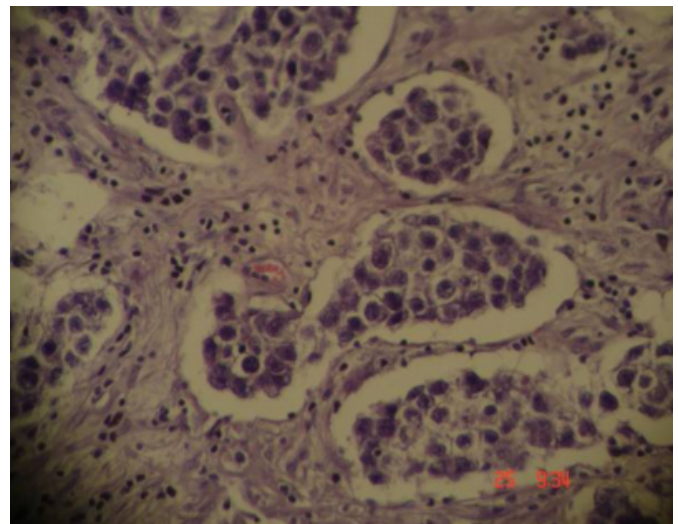
Image 3 : Karyotype of the patient with 46 XY complement.



Left gonadal mass was removed in Erzinçan State Hospital and right gonad was not detected during laparotomy. Left gonadal mass was measured as 36x32x28 mm. It was evaluated as dysgerminoma histopathologically in Erzinçan State Hospital (Image 4).

**Figure 5**

Image 4 : Microscopic view of dysgerminoma. (Hematoxylen-Eosine; x400)



There were granulomatous changes in the stroma. The entire gonad was replaced by tumor but there was not any invasion on the gonadal surface. Tumor was formed by well delimited nests of tumor cells separated by fibrous strands containing inflammatory cells. Tumor cells had abundant clear cytoplasm with well defined cell margins. Tumor was classified as stage I A according to FIGO grading system; because it was limited to left ovary, the capsule was intact, no tumor on gonadal surface and no malignant cells in

ascites or peritoneal washings.

### **DISCUSSION**

XY gonadal dysgenesis is characterized by streak gonads in phenotypic females without somatic abnormalities (<sup>8</sup>). The existence of uterus is important in definition of gonadal dysgenesis. In Swyer syndrome, uterus is present and it is generally hypoplastic. The absence of uterus has been regarded by a number of authors as a criterion for the diagnosis of androgen insensitivity syndrome (<sup>9</sup>).

There was a hypoplastic uterus in our patient (Image 2). Her vagina and breasts were immature. There was not a family history of primary amenorrhea, genital tract tumor or Swyer syndrome. Because of the existence of uterus it was not thought as androgen insensitivity syndrome. It was defined as Swyer syndrome.

Swyer syndrome is the most unusual form of gonadal dysgenesis with respect to androgen insensitivity syndrome and Turner syndrome. While the incidence of Swyer syndrome is 1:100.000; the incidences of Turner syndrome and androgen insensitivity syndrome are 1:2.000 and 1:20.000-64.000, respectively (<sup>4, 10, 11, 12</sup>).

The etiology of 46XY gonadal dysgenesis is thought to be a short arm Y chromosome deletion involving SRY, a mutation in other genes that leads to inhibition of SRY function or mutation of SRY function (<sup>13</sup>). To date, 20% of 46 XY pure gonad dysgenesis are explained by a mutation or a deletion in SRY. In 80%, SRY is apparently normal. A female patient with an XY karyotype who has a palpable müllerian system, normal female testosterone levels and lack of sexual development is considered to be Swyer syndrome. (<sup>7</sup>)

In our case, gonadotropin levels were over the postmenopausal level (FSH>170 mIU/L, LH: 44.6 mIU/L) and estradiol was under the lowest measurable range (20-534 pg/mL) in reproductive ages. Also, testosterone level was measured under the lowest range. The lack of menstruation or breast development was related with insufficiency of gonadotropins.

The germ cells of the dysgerminoma seem the most likely source of the HCG; additionally, they can produce CA-125 and AFP (<sup>14</sup>). But, in our case; beta-hCG, AFP and CA-125 levels were normal. Therefore, further investigations are necessary in a patient with primary amenorrhea as well as tumor markers are between normal ranges.

The patients with Swyer syndrome are usually normal or more frequently tall in stature (<sup>15</sup>). Our patient was 173 cm height and 52 kg weight.

Dysgerminoma is the most frequently seen tumor in female genital tract. The incidence for dysgerminoma within the whole female genital tract tumors is 32.8 % (<sup>16</sup>). A recent study about the ovarian malignant tumors in young girls and teenagers revealed that the left ovary was affected in 75% of cases. The most frequent histological subtype was dysgerminoma (56%) (<sup>17</sup>). In our patient, similarly, the left ovary was affected and histological subtype was dysgerminoma. However, the tumor usually develops in Swyer syndrome is gonadoblastoma. Dysgerminoma associated with Swyer syndrome is in the second rank and relatively a rare condition (<sup>3, 6</sup>).

About 65% of dysgerminomas are stage I (confined to one or both ovaries) at diagnosis. About 85% to 90% of stage I tumors are confined to one ovary; 10-15% are bilateral. The treatment of patient with early dysgerminoma is primarily surgical, including resection of the primary lesion and proper surgical staging. Chemotherapy and/or radiotherapy are administered to patients with metastatic disease (<sup>18</sup>). Since the stage of the tumor in our patient was IA, surgery was admitted as the sufficient therapy and the patient was advised to perform periodical controls.

The early diagnosis of the patients with Swyer syndrome is very important because of the increased risk for the development of malignancy in gonads. Thus, in an adolescent patient with primary amenorrhea, karyotype analysis and investigation of gonads is recommended. The prophylactic early surgical resection of gonads and if required, the convenient chemotherapy will lengthen survival.

### **CORRESPONDENCE TO**

Name: Mahir TAYFUR Postal address: Erzincan Devlet Hastanesi Patoloji Laboratuvarı Postal Code: 24040 Erzincan / TURKEY e-mail: drmahirtayfur@gmail.com Telephone: +904462241224 -1167, 1164 Fax number: +904462233786

### **References**

1. Nisolle M, Kridelka F, Fridman V, Claudon A, Lorquet S, Foidart JM. A bilateral dysgerminoma: a rare presentation of the Swyer syndrome. *Rev Med Liege*. 2005;60:703-6.
2. Marrakchi A, Belhaj L, Boussouf H, Chraïbi A, Kadiri A. Pure gonadal dysgenesis XX and XY: observations in fifteen patients. *Ann Endocrinol*. 2005;66:553-6.
3. Ben Romdhane K, Bessrouer A, Ben Amor MS, Ben Ayed M. Pure gonadal dysgenesis with 46 XY karyotyping

(Swyer's syndrome) with gonadoblastoma, dysgerminoma and embryonal carcinoma. *Bull Cancer*. 1988;75:263-9.

4. Vollrath D, Foote S, Hilton A, Page DC. The human Y chromosome Swyer GIM. Male Pseudohermaphroditism: A Hitherto Underscribed Form. *Br. Med* 1995;2:709-12
5. Holder M, Hecker W. Intersexuality and malignancy. Case report of an unreported association between a malignant disease in a child with androgen resistance syndrome in comparison with the most frequently expected malignant tumors in children with intersexuality. *Klin Padiatr*. 1994;206:50-4
6. Coutin AS, Hamy A, Fondevilla M, Savigny B, Paineau J, Visset J. Pure 46XY gonadal dysgenesis. *J Gynecol Obstet Biol Reprod (Paris)*. 1996;25:792-6
7. Behtash N, Karimi Zarchi M. Dysgerminoma in three patients with Swyer syndrome. *World J Surg Oncol*. 2007;5:71.
8. Kahyaoglu S, Turgay I, Ertas E, et al. Swyer syndrome with SRY + Y chromosome and rudimentary internal genitalia demonstrating temporary action of antimullerian hormone in utero: a case report. *J Reprod Med*. 2006;51:510-2.
9. Dapunt O, Platzer W, Gleispach H, Millonig-Ganner B. Rudimentary uterus in testicular feminization (author's transl). *Wien Klin Wochenschr*. 1975;87:498-506.
10. Quigley CA, De Bellis A, Marschke KB, El-Awady MK,

- Wilson EM. Androgen receptor defects: historical, clinical and molecular perspectives. *Endocr Rev*. 1995;16:271-321.
11. Bangsbøll S, Qvist I, Lebech PE, Lewinsky M. Testicular feminization syndrome and associated gonadal tumors in Denmark. *Acta Obstet. Gynecol. Scand*. 1992;71:63-6.
  12. Gravholt CH. Clinical practice in Turner syndrome. *Nat Clin Pract Endocrinol Metab*. 2005;1:41-52.
  13. Speroff L, Feritz MA. *Clinical Gynecologic Endocrinology and Infertility* 2005; seventh edition: 322-5, 348-9, 386-7.
  14. Scully RE. Gonadoblastoma: a review of 74 cases. *Cancer*. 1970;25:1340-56.
  15. Kawamura M, Owada M, Kimura Y, Fujiwara T, Sasaki A, Tajima T et al. 46, XY pure gonadal dysgenesis: a case with Graves' disease and exceptionally tall stature. *Intern. Med*. 2001;40:740-3.
  16. Smith HO, Berwick M, Verschraegen CF, Wiggins C, Lansing L, Muller CY et al. Incidence and survival rates for female malignant germ cell tumors. *Obstet Gynecol*. 2006;107:1075-85.
  17. Quero HA, Estrada CR, Tenorio RH, et al. Malignant germ cell ovarian tumors: clinical characteristics, treatment and outcome. *CirCir*. 2007;75:81-5.
  18. Berek JS, Hacker NF. *Clinical Gynecology*, Fourth edition, 2004: Chapter 23:514-8.

**Author Information**

**Mahir Tayfur, M.D.**

Department of Pathology, Erzincan State Hospital

**Ramazan Kocabas, M.D.**

Department of Biochemistry, Erzincan State Hospital

**Ahmet Zeki Kaygisiz, M.D.**

Department of Anesthesiology and Reanimation, Erzincan State Hospital

**Saban Tiryaki, M.D.**

Department of Radiology, Erzincan State Hospital

**Mesut Polat, M.D.**

Department of Obstetrics and Gynecology, Erzincan State Hospital

**Kivanc Cefle, M.D.**

Ass. Professor, Department of Internal Medicine, Division of Medical Genetics, Medical Faculty of Istanbul, Istanbul University