

Columella Reconstruction With Elbaz's Flap: A Case Report And Litterature Review

L Ndiaye, A Sankale, A Ndiaye, L Foba

Citation

L Ndiaye, A Sankale, A Ndiaye, L Foba. *Columella Reconstruction With Elbaz's Flap: A Case Report And Litterature Review*. The Internet Journal of Plastic Surgery. 2016 Volume 12 Number 1.

DOI: [10.5580/IJPS.36880](https://doi.org/10.5580/IJPS.36880)

Abstract

Columella reconstruction remains a challenging problem for reconstructive surgeons. We report a 28-year-old patient with complete columella defect following human bite, successfully reconstructed by an edge nasal flap according to Elbaz. No complications occurred and result was assessed as very good after two years follow up. Elbaz's flap can be a good and safe option for columella reconstruction.

INTRODUCTION

The columella is one of the key elements of the aesthetic of the nose's tip. Etiologies of columella loss of substance have different causes dominated by surgical tumor resection [1]. The columella has repeatedly proven to be one of the most complex nasal subunits to reconstruct and therefore has prompted several techniques to be published in literature [2, 3, 4]. Through this clinical case, we report a columella reconstruction by an edge nasal flap as described by Elbaz [5].

CASE REPORT

A 28-year-old man was referred for columella loss of substance after a human bite. Clinical examination showed a complete defect of the columella with collapse and widening of the nostrils (figure 1). Columella reconstruction by Elbaz's flap was therefore planned. Operative technique: Surgical procedure was performed under general anesthesia. The flap was drawn with a width of 3mm at the 2/3 proximal end of the nostril. A transfixing incision was made to the nostril edge. The flaps were elevated, pediculated on the tip, and the donor sites were closed primarily. The mucosa of the nasal septum was incised vertically and decollated in each side of it. The nasal edge flaps were translated and sutured medially together in front of and behind in continuity of the septum (figures 2,3). A dressing was made with ointment and the stitches were removed at day 7. No complications occurred and the flaps survived completely. After two years follow up, cosmetic result was judged as

good (figure 4).

Figure 1

Columella defect before surgery

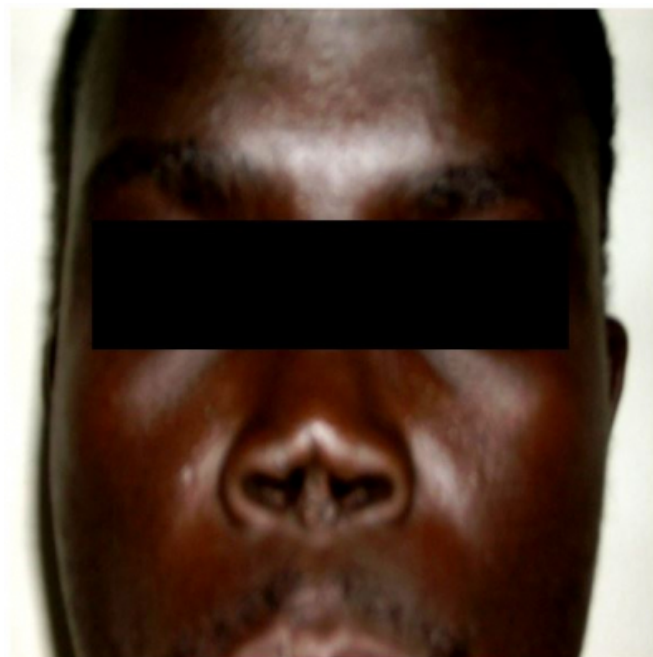


Figure 2

Surgical procedure

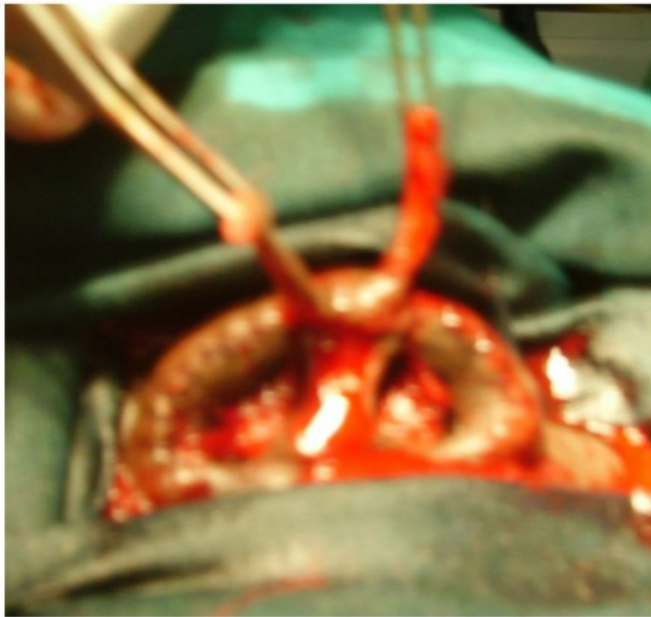


Figure 3

After surgery

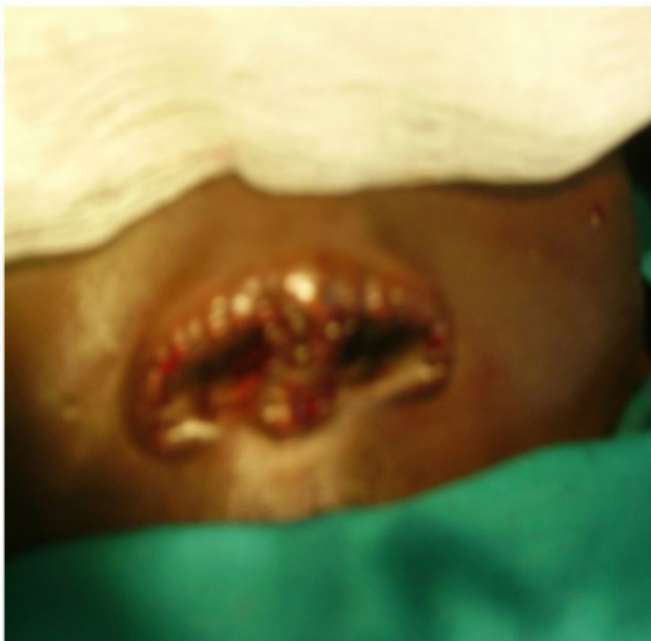
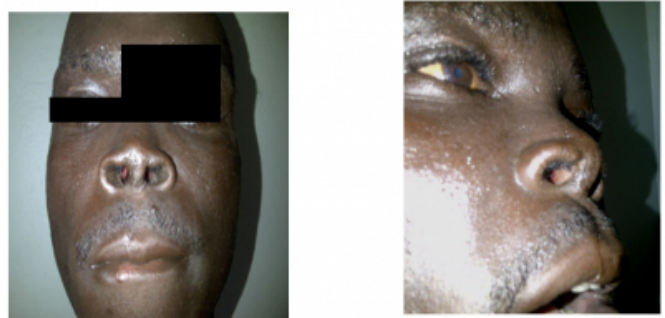

Figure 4

Results after 11 months



DISCUSSION

Columella defects are of diverse origin and those secondary to carcinomas resection are the main cause of the defect [1]. These etiologies are more represented in the elderly of white races. Specific etiologies can be noted such as sequelae of Carcinoma oris and syphilis [6] as well as leprosy, especially in developing countries. Columella defect following human bite is very rare or even unique. It occurs in circumstances of brawl in young people as in most traumatic etiologies. The columella defects are rarely isolated and often associated with those of the lower third of the nose and or upper lip [7, 8]. Columella reconstruction is a difficult problem, because of its three-dimensional aspect, located at the crossroads of the tip of the nose, the septum and the labial philtrum [9]. In the isolated defect repair must obey the law of the third [3]. For defect less than a third, composite graft of the helix can be realized [10,11], between two-thirds and one-third, repair notes of a local tummy by shreds of upper lip or wing flaps; beyond the two-thirds, the reconstruction by flaps initial for the skin recovery must be performed [1,7]. We opted in our case to perform reconstruction of total columella defect by an edge nasal flap as described by Elbaz [5]. This flap was chosen according to multiple reasons. Locally, the nostril was large in its transversally diameter allowing for removal of the nasal flap. The described technique left minimal scarring on the face. The tip of the nose is well shaped flap and in a few weeks good color adaptation with nasal skin occurred. The risk of hypertrophic scar in young people did not support a decision to make a loco-regional flap. This technique has an advantage to be carried out in a surgery with little aesthetic involvement [5]. It is especially indicated in patients with broad nostrils like negroid types because it reduces the negroid shape and then improves the aesthetic of the nose [5].

CONCLUSION

Edge nasal flap is a good, safe, and reliable technique for

columella repair. Reconstruction is made in a single surgery with minimal aesthetic requirement. It can be proposed as first consideration to reconstitute the columella in people with large nostrils because it can provide sufficient tissue to replace total columella loss.

References

1. Bouguila J, Zairi I, Yacoub K, Ben Neji N, d'Hauthuille C, et al. Les pertes de substance de la columelle : encore un défi ! Columella defects: Yet a challenge! *Annales de chirurgie plastique esthétique* 2008 ; 53 : 504 -512.
2. A. Motamed S, Kalantar-Hormozi AJ. Columella reconstruction with the Washio flap. *Br Assoc Plastic Surg* 2003; 56:829 - 31.
3. B. Burget GC, Menick FJ. The subunit principle in nasal reconstruction. *Plast Reconstr Surg* 1985; 76(2):239 -47.
4. C. Demir Z, Ozdil K, Karamursel S, Yuce S, Oktem F, Celebioglu S. Reconstruction of the columella with bilateral nostril sill flaps. *Ann Otol Rhinol Laryngol* 2006; 115(3):239-42.
5. Elbaz JS. Columella repair by a simple 1-stage procedure (apropos of a case seen more than 4 years later). *Ann Chir Plast*. 1971; 16(1): 25-9.
6. Revol M, Guinard D, Bardot J, Texier M. La réparation des parties de substances du nez chez l'adulte. 38e congrès de la Société française de chirurgie plastique, reconstructrice et esthétique 1994.
7. Kaluzinski E, Crasson F, Alix T, Labbé D. Le lambeau nasogénien en reconstruction de la columelle. *Rev Stomatol Chir Maxillofac* 2004; 105:171 - 6.
8. Cantarella G, Mazzola RF, Pagani D. The fate of an amputated nose after replantation. *Am J Otolaryngol Head Neck Med Surg* 2005; 26: 344 -7.
9. Martin D, Pinsolle V, Casoli V, Kakas P, Pelissier P, Baudet J. Rhinopoièses complexes : techniques d'hier, d'aujourd'hui et de demain. *Rev Stomatol Chir Maxillofac* 2003; 104 :149-58.
10. Burm JS. Reconstruction of the nasal tip including the columella and soft triangle using a mastoid composite graft. *J Plast Reconstr Aesthet Surg* 2006; 59:253- 6.
11. Kim YO, Park BY, Lee WJ. Aesthetic reconstruction of the nasal tip using a folded composite graft from the ear. *Br Assoc Plastic Surgeons* 2004; 57:238 - 44.
12. Bianchi A, Galli S, Ferroni M. Personal technique for columella reconstruction. *Laryngoscope*, 1984; 94 : 1613-5.
13. Mazauric FX. Une technique de réfection autoplastique des pertes de substance columellaires post-traumatiques anciennes. *Ann Chir Plast*, 1970; 15 :121-5.
14. Meyer R. Aesthetic aspects in reconstructive surgery of the nose. *Aesthetic Plast Surg*, 1988; 12 : 195-201.
15. Stricker M. Les mutilations de la columelle. *Rev Stomatol*, 1996; 73: 485-94.

Author Information

L Ndiaye

Department of Plastic Reconstructive and Aesthetic Surgery, Aristide Le Dantec Hospital
Dakar, Senegal
drIndiaye@yahoo.fr

AA Sankale

Department of Plastic Reconstructive and Aesthetic Surgery, Aristide Le Dantec Hospital
Dakar, Senegal

A Ndiaye

Department of Plastic Reconstructive and Aesthetic Surgery, Aristide Le Dantec Hospital
Dakar, Senegal

L Foba

Department of Plastic Reconstructive and Aesthetic Surgery, Aristide Le Dantec Hospital
Dakar, Senegal