

Primary Umbilical Adenocarcinoma - A Case Report

R Atri, A Dhull, P Kaur, G Singh, A Chauhan

Citation

R Atri, A Dhull, P Kaur, G Singh, A Chauhan. *Primary Umbilical Adenocarcinoma - A Case Report*. The Internet Journal of Third World Medicine. 2009 Volume 9 Number 1.

Abstract

Primary adenocarcinoma arising from the umbilicus is an uncommon malignancy, with only a handful of cases reported in the modern medical literature. The diagnosis is however, important because metastatic tumors of umbilicus are much commoner. A case of primary adenocarcinoma of umbilicus is being described in a 28 year male patient treated with surgical excision of nodule followed by combination chemotherapy.

INTRODUCTION

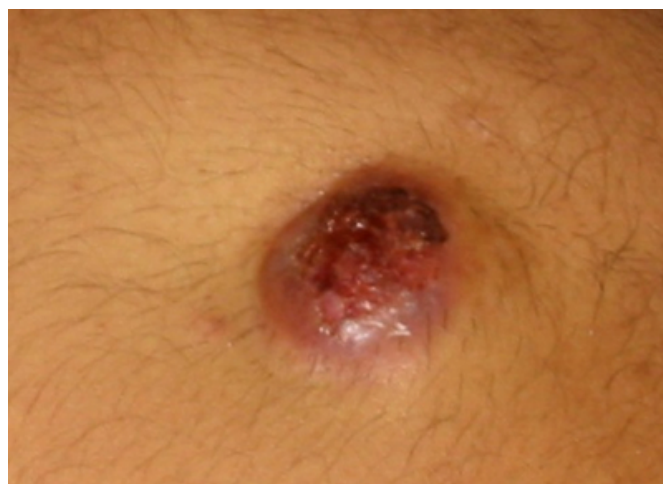Metastatic tumors of the umbilicus are much commoner than primary neoplasms¹. Primary malignancies of umbilicus accounts one fourth or one sixth of the metastatic tumors at this location². A primary adenocarcinoma arising at the umbilicus is a very rare occurrence³.

CASE REPORT

A 28 year male presented with complaints of discharge from umbilicus for one year duration. Discharge was thick and purulent in nature, associated with off-on pain abdomen which was mild to moderate in intensity and non referred type. There were no complaints of vomiting and diarrhea. There was no significant past medical and surgical history. Physical and general examination of the patient was normal. On local examination there was a reddish brown swelling of 2.5 x 3.0 cm in size present in the umbilical region which was subcutaneous, round, tender, mobile and hard in consistency (Fig.1).

Figure 1

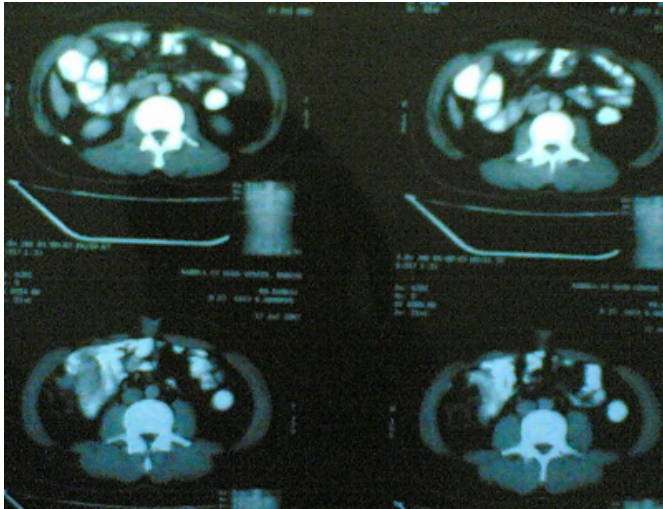
Figure 1: Reddish brown swelling of 2.5 x 3.0 cm in size present in the umbilical region



On examination, there was no other similar swelling anywhere else in the body. Abdominal Ultrasonography showed irregular hypo echoic mass with micro calcification seen in the umbilical region not extending into peritoneal cavity. CT scan showed a tiny soft tissue nodule at posterior aspect of the umbilicus, abutting linea alba which was compressing and displacing linea alba by extending inside it. There was no communication with bowel loops (Fig.2).

Figure 2

Figure 2: CT scan showed a tiny soft tissue nodule at posterior aspect of umbilicus



There was no significant regional and retroperitoneal lymphadenopathy. Fine needle aspiration cytology of the nodule revealed malignancy. The initial diagnosis of this lesion was being thought as metastatic deposit and an x ray chest, barium enema, upper gastrointestinal endoscopy, and colonoscopy were performed but all were normal and no other primary was detected. Carcino embryonic antigen (CEA) was found to be 2.81ng/ml. (Normal <3.00)

Then patient underwent surgical excision of the swelling. Per operative findings revealed an ulcerated nodule of 5 x 5 cm on the umbilicus. Swelling was not seen extending to peritoneum and adjacent structures were not infiltrated. Histopathology of excised nodule was suggestive of adenocarcinoma of umbilicus (Fig.3, Fig.4). Followed by this, patient received six courses of combination chemotherapy with carboplatin and doxorubicin at three weekly intervals.

Figure 3

Figure 3: Photomicrograph showing skin with underlying malignant cells arranged in glandular fashion H&E (40x).

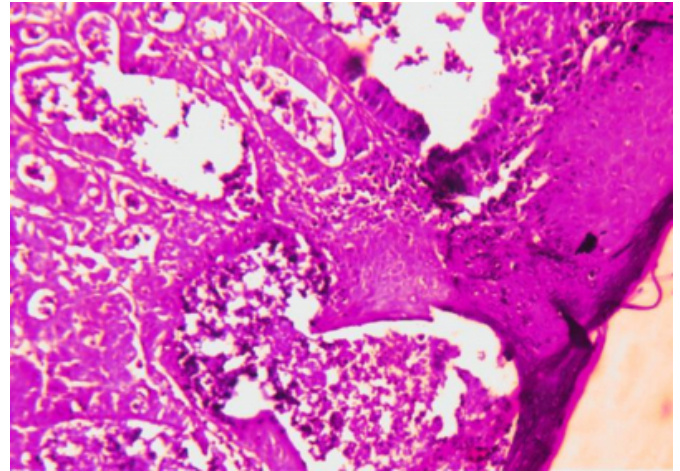
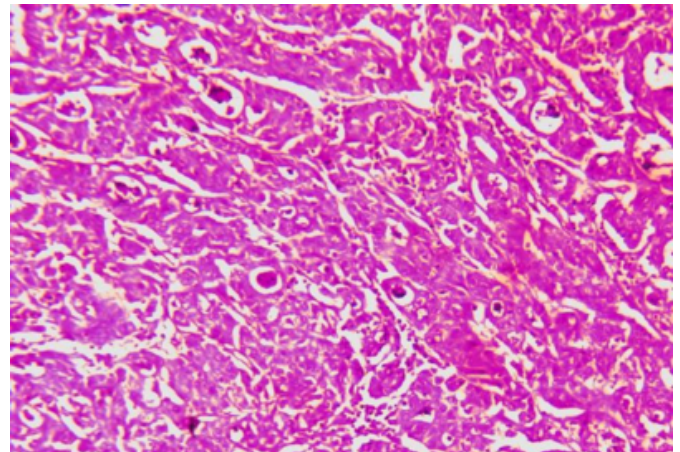


Figure 4

Figure 4: Photomicrograph showing malignant cells arranged in glandular fashion H&E (100x).



DISCUSSION

The umbilicus has been found to show a wide variety of tumors and is predisposed to metastasis from visceral tumors because of its relationship and generous vascular and embryonic connections. The superficial lymphatic drainage of the periumbilical region connects with the axillary nodes above and the inguinal nodes below. Deep lymphatic drainage is into the internal thoracic, external iliac, abdominal and paraaortic nodes.

Cancer of the umbilicus accounts for more than one tenth of all malignant tumors that affects the skin of the anterior abdominal wall ⁴. Approximately 80% of these are metastatic to umbilicus (Sister Marry Joseph Nodule), and primary tumor representing for 20% at this location ⁵. A primary adenocarcinoma arising at the umbilicus is very rare

³. Adenocarcinoma represents over half of these reported cases ⁶. In a study of 112 cases of umbilical tumors Steck and Helwig found 64 benign and 48 malignant lesions, in which only 7 were primary tumors of umbilicus ⁴. Primary tumors may arise within skin, soft tissue or congenital rests that are peculiar to the umbilical region ^{2,7}.

Two possible explanation of origin of adenocarcinoma from this site have been given in published literature; one is glandular embryologic remnants deriving from omphalomesenteric (vitello – intestinal) duct or the urachus and other metaplasia from squamous epithelium. In our case possibility of urachus tumor is ruled out, as these tumors are found below the umbilicus, commonly related to micturition and at the time of presentation suprapubic mass is palpable in around 80% of cases. Glazer et al reported primary adenocarcinoma at umbilicus in a 46 year old female, arose from a vitello- intestinal duct remnant, (also gave two sites of origin) a primary adenocarcinoma at this site can only arise from a pre-existing endometrioma or an embryological remnant ³. Metastasis from the umbilicus is a simpler phenomenon than metastasis to the umbilicus, considering lymphatics of the abdominal wall ⁴.

The predominant clinical presentation is a hard, irregularly nodular or exfoliative umbilical mass with an ill-defined induration and the lesion occasionally ulcerated with coloration. Symptoms of these patients vary from nausea, vomiting, weight loss, constipation, pain and malena ⁴. The present patient experienced mainly pain and discharge from the umbilicus. Differential diagnosis of umbilical swelling

includes endometrioma, keloid, hernia, papillomas, fibromas and epithelial inclusion cyst ⁸.

Management of primary umbilical tumors are surgical excision, a radical local surgery is indicated. Radiotherapy is always given in cases of metastatic tumors because of poor prognosis ³. An aggressive approach may be suggested in some patients, especially because once metastasis occurs, prognosis becomes more guarded.

In conclusion, primary adenocarcinoma of the umbilicus is an uncommon neoplasm that may behave more aggressively. It must be taken into account when making the differential diagnosis of any umbilical mass.

References

1. Brady LW, O'Neill EA, Farber SH. Unusual site for metastases. *Semin Oncol* 1977; 1113-7.
2. Hernandez N, Medina V, Alvarez-Arguelles H. Primary papillary psammomatous adenocarcinoma of the umbilicus. *Histol Histopathol* 1993; 8: 593-8
3. Glazer G. Primary adenocarcinoma arising in a vitellointestinal duct remnant at the umbilicus. *Br J Surg* 1973; 60: 247-9.
4. Steck WD, Helwig EB. Tumors of the umbilicus. *Cancer* 1965; 18: 907-15.
5. Meine JG, Bailin PL. Primary melanoma of the umbilicus: Report of a case and review of the relevant anatomy. *Dermatol Surg* 2003; 29: 405-7.
6. Charoenkul V, DelCampo A, Derby A. Tumors of the umbilicus. *Mt Sinai J Med* 1977; 44: 257-62.
7. Ross JE, Hill RB Jr. Primary umbilical adenocarcinoma. A case report and review of literature. *Arch Pathol* 1975; 99: 327-9.
8. Olcay A, Yeliz E, Gulen D, Sabri E. Primary Umbilical Adenocarcinoma: Case Report and Review of the Literature : *The American Surgeon* 2007; 73: 923-5(3).

Author Information

Rajeev Atri, MD

Assistant Professor, Pt BD Sharma Post Graduate Institute of Medical Sciences

Anil Kumar Dhull, MD

Medical Officer, Pt BD Sharma Post Graduate Institute of Medical Sciences

Paramjeet Kaur, MD

Assistant Professor, Pt BD Sharma Post Graduate Institute of Medical Sciences

Gajender Singh, MD

Assistant Professor, Pt BD Sharma Post Graduate Institute of Medical Sciences

Ashok Chauhan, MD

Senior Professor & Head, Pt BD Sharma Post Graduate Institute of Medical Sciences