

Images in Clinical Medicine: Moyamoya

N Sethi, C Choi, P Douyon, S Staicu, J Torgovnick, B Zablow, A Hirschfeld, E Robilotti

Citation

N Sethi, C Choi, P Douyon, S Staicu, J Torgovnick, B Zablow, A Hirschfeld, E Robilotti. *Images in Clinical Medicine: Moyamoya*. The Internet Journal of Radiology. 2004 Volume 4 Number 1.

Abstract

Moyamoya disease is a progressive occlusive disease of the cerebral vasculature with a predilection for involvement of the circle of Willis and its arterial feeders. Moyamoya (Japanese for "puff of smoke" or "haze") characterizes the appearance on angiography of abnormal vascular collateral networks that develop adjacent to the stenotic vessels. Pathologically, there is intimal thickening of the distal internal carotid arteries and/or proximal anterior and middle cerebral artery trunks leading to varying degrees of stenosis. The exact etiology of the disease remains unknown; an autosomal recessive inheritance pattern has been described 1.

CASE REPORT

A-28-year old Pakistani male previously diagnosed with Moyamoya, presented to our hospital with subarachnoid hemorrhage. A four vessel angiogram showed the characteristic angiographic appearance of Moyamoya (Fig 1, 2).

Figure 1

Figures 1 and 2: Angiogram showing the characteristic "puff" of Moyamoya

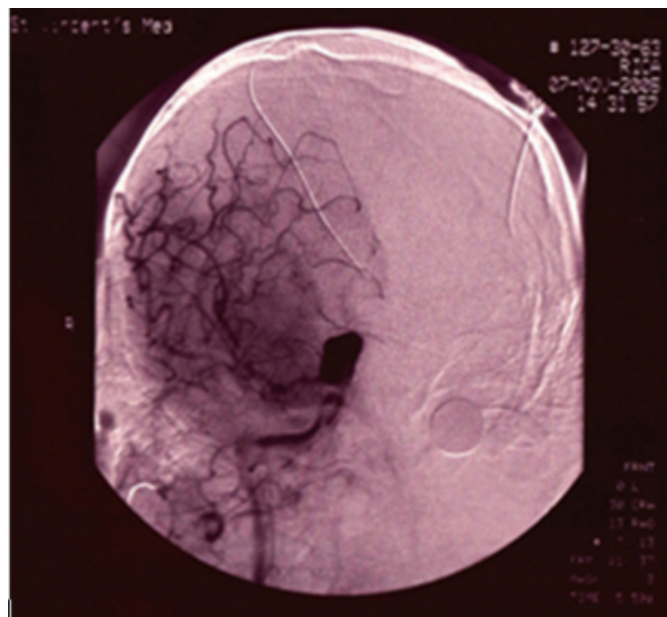
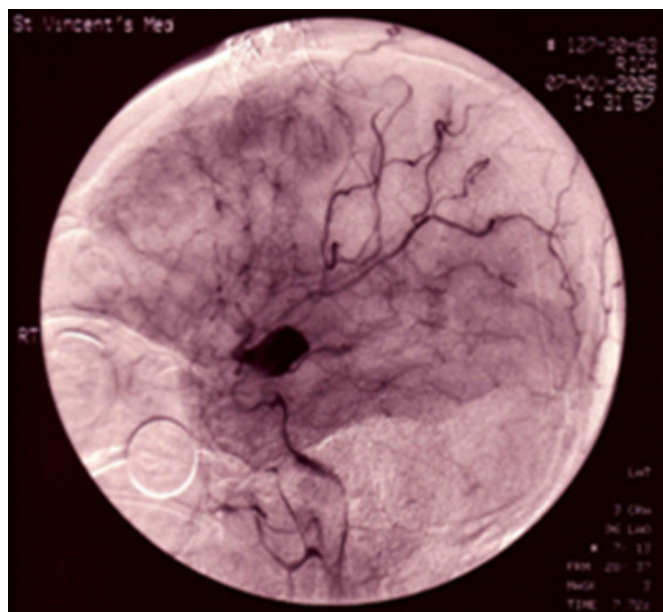


Figure 2

Figures 1 and 2: Angiogram showing the characteristic "puff" of Moyamoya



DISCUSSION

Moyamoya disease is more common in females as compared to males. The disease presents with ischemic strokes in children, while intracerebral and subarachnoid hemorrhage occur more commonly in adults. More than half of patients experience gradual cognitive deficits from recurrent ischemic strokes. Therapy is directed primarily at complications of the disease. Various pediatric neurosurgical procedures have been described, the most favored been

EDAS (encephaloduroarteriosynangiosis), EMS (encephalomyosynangiosis) and STA-MCA (superficial temporal artery-middle cerebral artery), all with the aim of bypassing the obstructions and increasing the blood supply to the brain. Our patient's hospital course was complicated by ARDS and sepsis and at the time of this writing, he is intubated and on mechanical ventilation.

CORRESPONDENCE TO

Nitin Sethi, M.D. Chief Resident, Neurology Saint Vincent's Hospital and Medical Centers 153 West, 11th Street New York, NY 10011 Email: sethinitinmd@hotmail.com

References

1. Familial occurrence of moyamoya disease: report of three Japanese families.
Kitahara T, Ariga N, Yamaura A, Makino H, Maki Y. J Neurol Neurosurg Psychiatry. 1979 Mar; 42(3):208-14.

Author Information

N. K. Sethi, M.D.

Department of Neurology, Saint Vincent's Hospital and Medical Centers

C. Choi

Medical Students, New York Medical College

P. Douyon

Medical Students, New York Medical College

S. Staicu

Medical Students, New York Medical College

J. Torgovnick, M.D.

Department of Neurology, Saint Vincent's Hospital and Medical Centers

B. Zablow, M.D.

Department of Neurosurgery, Saint Vincent's Hospital and Medical Centers

A. Hirschfeld, M.D.

Department of Neurosurgery, Saint Vincent's Hospital and Medical Centers

E. Robilotti

Medical Students, New York Medical College