

Progressive Multifocal Leukoencephalopathy Partial Weber's Syndrome and Global Cerebellar Syndrome in a HIV-Positive Patient: A Case Report

H Foyaca-Sibat, L Ibanez-Valdes

Citation

H Foyaca-Sibat, L Ibanez-Valdes. *Progressive Multifocal Leukoencephalopathy Partial Weber's Syndrome and Global Cerebellar Syndrome in a HIV-Positive Patient: A Case Report*. The Internet Journal of Neurology. 2006 Volume 7 Number 2.

Abstract

INTRODUCTION

The polyomavirus JC (JCV) infects 85% of healthy individuals, and its reactivation in a limited number of immuno-suppressed people causes progressive multifocal leukoencephalopathy (PML), a severe demyelinating disease of the central nervous system. Pasquier et al¹ hypothesized that JCV-specific cytotoxic T lymphocytes (CTLs) might control JCV replication in healthy individuals, blocking the evolution of PML and they determined that the frequency of JCV VP1 epitope-specific CTLs varied from less than 1/100,000 to 1/2,494 peripheral blood mononuclear cells. Therefore more individuals had JCV VP1-specific than cytomegalovirus-specific CTLs (8 of 11 subjects [73%] versus 2 of 10 subjects [20%], respectively). These results showed that a CD8⁺-T-cell response against JCV is commonly found in immuno-competent people and suggest that these cells might protect against the development of PML.

PML is described for the first time in 1958, at the Massachusetts General Hospital in Boston by Richardson and his colleagues² in three patients who presented with multiple demyelinating lesions on the central nervous system (CNS), rapid fatal outcome and underlying chronic lymphocytic leukemia (CLL) and Hodgkin's disease. Last report about PML and CLL made by Rayid Abdulqawi et al³ is available on The Internet Journal of Neurology.

The genus of polyomavirus belongs to the family of Papovavirus. There are 3 polyomaviruses, the JC, BK and SV40 viruses. They are all viruses with double-stranded DNA. In almost all cases of PML, the JC virus (JCV) is the etiologic agent, although in isolated reports, BK and SV40

viruses have been implicated. Both JC and BK are initials of patients from whom the respective virus was first isolated. JCV is difficult to isolate, requiring long term cultures in glial cells. There are 4 genotypes numbered from 1 to 4, of which genotypes 1 and 2 are associated with the disease of PML.⁴ PML is a demyelinating disease of the central nervous system, resulting from infection of oligodendrocytes and astrocytes. The pathologic hallmark is the triad of discrete foci of demyelination, enlarged nuclei of oligodendrocytes, and bizarre-shaped astrocytes. This is consistent with the in vitro viral tropism to glial cells. Neurons are generally spared, but recently it was observed that the granule cell neuron in the cerebellum could also be infected in PML. In one case report, the granule cell neuron was infected exclusively.^{5,6}

Weber's syndrome was first described in 1863 by the German physician Hermann Weber,⁷ Weber's Syndrome occurs when a midbrain lesion gives rise to an ipsilateral third nerve palsy (resulting in an ipsilateral loss of pupillary light reflex and accommodation, ptosis, pupillary dilatation, and lateral deviation of the eye) plus a contralateral hemiplegia. Partial Weber's Syndrome has been described where pupillary reflexes remain intact through sparing of the Edinger-Westphal nucleus in the upper mid-brain.^{8,9} However, to our knowledge this is the first case of a partial Weber's syndrome with sparing of the contralateral upper limb.

Neurological disease associated with Human immunodeficiency virus -1 (HIV-1) infection is becoming more common as antiretroviral therapy improves patient survival.¹⁰

Isolated cerebellar symptoms in HIV infection have been reported rarely^{11,12} and usually result from lesions due to neoplasm or opportunistic infections¹². In HIV dementia complex cerebellar syndrome has been reported as an early sign preceding cognitive decline in 30% of cases¹³. Primary cerebellar degenerations in the absence of and toxic, metabolic or nutritional abnormality or genetic predisposition is exceedingly rare^{11,12}.

Cerebellar syndrome as a direct effect of HIV infection has been postulated¹¹. Animal studies have shown that rat cerebellar granular cells exposed to HIV coat protein gp 120, had a markedly increased rate of cell death¹⁴.

The aim of this study is to report a HIV-positive patient with a partial Weber's Syndrome affecting the right eye and left lower limb secondary to demyelinating lesion on the midbrain and bilateral cerebellar syndrome in the absence of signs of hematological malignancy or other causative agent.

CASE REPORT

We report a 23 year-old-male presented to the Nelson Mandela Academic Hospital, Umtata, South Africa with a non-productive cough of one month duration and an inability to walk of seven months duration which has begun with paresthesia and pain affecting the hands and feet.

On examination there were bilateral cerebellar signs including bilateral horizontal vestibular nystagmus, bilateral dysidiadochokinesia, bilateral intentional tremor, bilateral dysmetria, ataxic gait, positive Romberg test (falling forward/backward), positive postural reflex, and pendular reflexes. He was hypotonic in both upper limbs and the right lower limb with hyperreflexia, normal power. The left lower limb showed spasticity, hyperreflexia (+ + +), ankle clonus and an extensor plantar response. Power was 4/5 proximal and distally. There was incomplete right sided third nerve palsy (weakness of inferior oblique, middle rectus and inferior rectus) with an incomplete palpebral ptosis and mild dilation of the right pupil (6.0 mm) no reactive to light. All other cranial nerves were intact. All sensory modalities were normal and cognition was intact. The patient had oral candidiasis, and apical crepitations were noted on auscultation of the chest.

The patient was a known WHO stage IV HIV positive patient (diagnosed 7 months before current presentation) on HAART (Stavudine 30 mg. lamivudine 150 mg. efavirenz 600 mg.) On presentation his CD4 count was 164. The

patient had also been treated for pulmonary tuberculosis (TB) in 2005 for 9 months. He had no family history of hereditary cerebellar disorders. He had no history to taking phenytoin or other drugs with known cerebellar toxicity. He admitted to drinking alcohol moderately but hadn't consumed any since his problems had started. Blood test on admission showed mildly elevated liver enzymes thought to be due to his ARV therapy, normal white cell count and low red cell count and haemoglobin (3.2 and 10.4 respectively). CSF examination was normal and negative for Cryptococcus. A CT scans showed generalized brain atrophy and MRI revealed a hyperintense lesion in the midbrain, interpreted by radiologist as tuberculoma (Figure 1-2). He was commenced on anti TB therapy (rifampicin, isoniazide, pyrazinamide, and ethambutol), vitamin B12 and thiamine and continued with HAART. Patient presented an important epistaxis and looked critically ill and severally deteriorated; the liver enzymes became very high and INR was 4.5. All medications were discontinued and patient gradually improved but all cerebellar and partial Weber signs remained unchanged

Figure 1

Figure 1: T2-weighted MRI brain coronal view, revealing well demarked hyperintense enhancing nodule in the midbrain at the base of the right cerebral peduncle (white arrow), no perilesional oedema is seen.

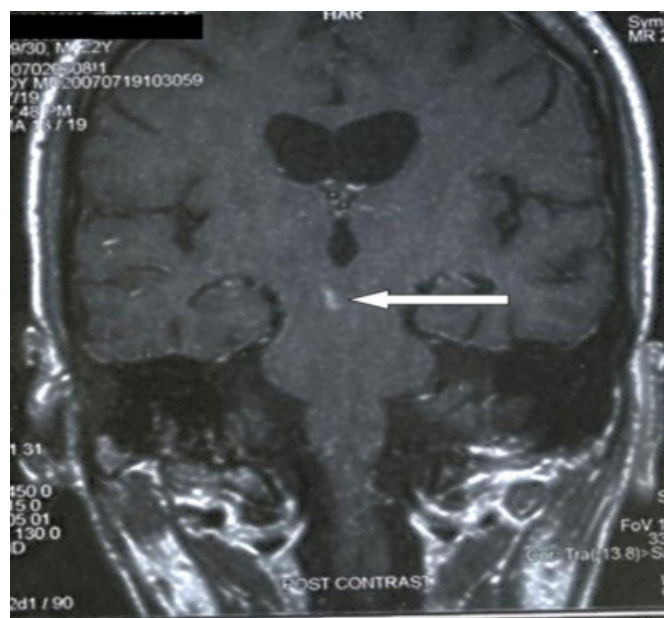


Figure 2

Figure 2: T2-weighted MRI brain scanner axial view revealing marked increase in the size of the hyperintense signals (white arrow) on the right cerebral peduncles and several hyperintensities are seen in the white matter on the flair images, non-enhancing and without perilesional oedema at the parietal and occipital lobes.

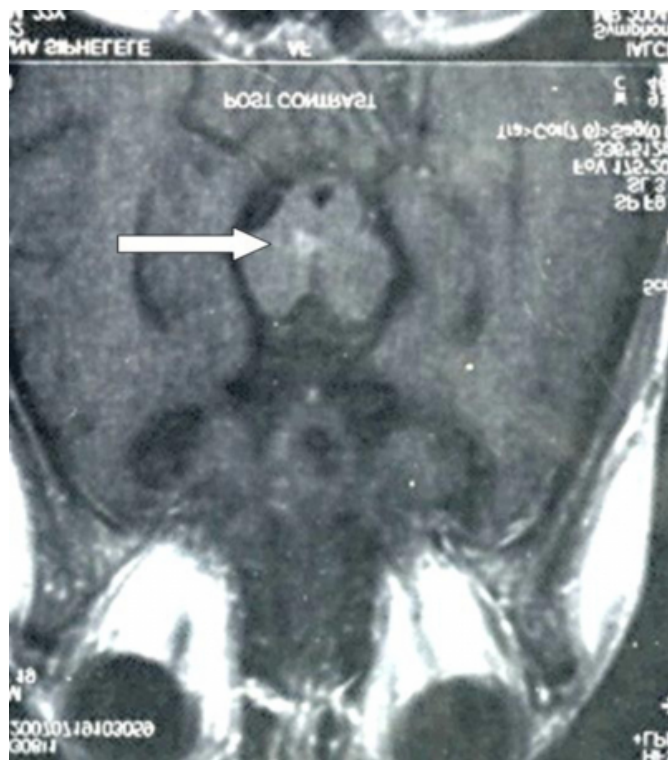
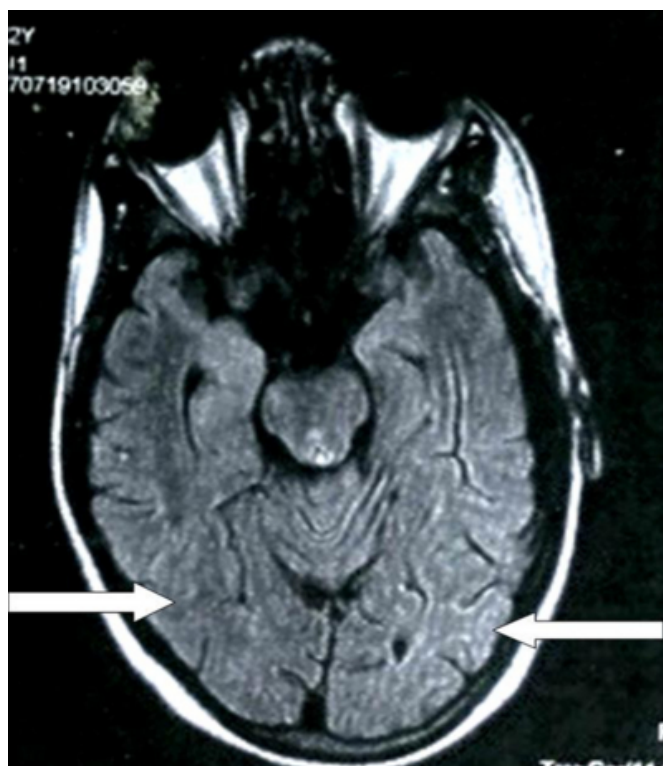
Figure 3

Figure 3: T2-weighted MRI scanner of the brain showing several hyperintensities in the white matter without perilesional edema on the parietal and occipital lobes.



DISCUSSION

CNS disease can result from opportunistic infection, drug toxicity, malignancy, cerebrovascular disease and direct HIV-1 infection.

PML classically has a sub acute clinical presentation with focal neurological deficits, such as weakness, speech difficulties, unsteady gait and hemiparesis. Ophthalmic symptoms are relatively common, occurring as homonymous hemianopia which progresses to cortical blindness; clinical variations can be seen related with the underlying process (CLL, Hodgkin, or AIDS) but the outcome does not show remarkable differences and the natural course of disease is one of inexorable progression to death in a median of 4 months, often punctuated by additional opportunistic infections. In our patient, the cerebellar manifestations corresponded with those described in the medical literature secondary to damage on the granular layer of the cerebellum. This patient showed a partial Weber's Syndrome affecting the right eye and left lower limb related to a midbrain demyelinating lesion commonly caused by JVC. A working diagnosis of PML is generally based on the clinical presentation supported by the radiographic picture or a

positive PCR test for JCV in the CSF, which is relatively specific for PML but sensitivity is inadequate and very dependent on the primers employed, which is probably related to the widespread use of HAART. In places where PCR is not available, diagnosis is made by identification of the typical lesions of demyelination on MRI (MRI is superior to CT scan in the diagnosis of PML); in any case definitive diagnosis requires a brain biopsy. Like our patient, with the use of HAART, PML may progress or present differently.

Because the patient symptoms started after he had started HAART we considered it as part of the immune reconstitution inflammatory syndrome. In this regards, is important to remember that PML may not manifest until after the start of HAART and signs of immune recovery or significant viral suppression are present. Its diagnosis can be difficult and opportunistic infections should be ruled out but as was before-mentioned in all cases brain biopsy has the last word and when it is not possible then this diagnosis should be considered if an unpredictable clinical course and associate drop in viral load, elevated CD4 count, development of JCV-specific CTL₁₄, and temporal relationship with the initiation of HAART is present.

For the other hand, with effective antiretroviral therapy, the prognosis for those who develop PML has improved dramatically, with long-term remission being fairly common therefore decision to stop HAART should be taken by very experienced doctors. Rather to follow guidelines without proper adaptation to each patient, each patient should be assessed individually and decision should be taken accordingly.

References

1. Pasquier RA, Schmitz JE, Jean-Jacques J, Zheng Y,

- Gordon J, Khalili K, Letvin KL, Koralknik IJ. Detection of JC Virus-Specific Cytotoxic T Lymphocytes in Healthy Individuals. *J Virol* 2004;78(18):10206-10210
2. Astrom KE, Mancal EL, Richardson EP Progressive Multifocal Leukoencephalopathy. *Brain* 1958;81:93-127
3. Rayid Abdulqawi R, Ashawesh K, Newman P. Progressive multifocal leukoencephalopathy in a patient with chronic lymphocytic leukaemia. *The Internet J Neurol*. 2007;7(2) Available on URL <http://www.isup.com>
4. Dubois V, Moret H, Lafon ME, et al. JC virus genotypes in France: molecular epidemiology and potential significance for progressive multifocal leukoencephalopathy. *J Infect Dis* 2001;183:213-7.
5. Koralknik IJ, Wuthrich C, Dang X, et al. JC virus granule cell neuronopathy: A novel clinical syndrome distinct from progressive multifocal leukoencephalopathy. *Ann Neurol* 2005;57:576-80.
6. Du Pasquier RA, Corey S, Margolin DH, et al. Productive infection of cerebellar granule cell neurons by JC virus in an HIV+ individual. *Neurology* 2003;61:775-82.
7. Silverman IE, Liu GT, Volpe NJ, et al. The Crossed Paralysis. The Original Brain-Stem Syndromes of Millard-Gubler, Foville, Webe and Raymond-Cestan. *Archives of Neurology*. 1995;52:635-638.
8. Umasankar U, Huwez FU. A patient with reversible pupil-sparing Weber's syndrome. *Neurology India*. 2003;51:388-389.
9. Huwez FU, Umasankar U, Aggrawal D. An elderly lady with collapse. *Post Med J* 2002;78:105-109.
10. Skiest DJ. Focal neurological disease in patients with acquired immunodeficiency syndrome. *Clin Infect Dis* 2002;34:103-15.
11. Tagliati M, Simpson D, Morgello S, Clifford D, Schwatz RL, Berger JR. Cerebellar degeneration associated with human immunodeficiency virus infection. *Neurology* 1998;50:244-251.
12. Kwakwa HA and Ghobrial MW. Primary cerebellar degeneration and HIV. *Archives of Internal Medicine*. 2001;161:1555-1556.
- 13.- Graus F., Ribalt T, Abols J, et al. Subacute cerebellar syndrome as the first manifestation of AIDS dementia complex. *Acta Neuro Scand*. 1990;81-118-120.
13. Savio T, Levy G. Neurotoxicity of HIV coat protein gp120, NMDA receptors, and protein kinase C; a study with rat cerebellar granule cell cultures. *J Neuroscience Res*. 1993;34:265-272.
14. Tyler KL. The uninvited guest: JC virus infection of neurons in PML. *Neurology* 2003;6134-735.

Author Information

H. Foyaca-Sibat

Division of Neurology, Nelson Mandela Academic Hospital, Faculty of Health Sciences, Walter Sisulu University

Lde F. Ibanez-Valdes

Division of Neurology, Nelson Mandela Academic Hospital, Faculty of Health Sciences, Walter Sisulu University