

# Use of Percutaneous Transtracheal Jet Ventilation (PTJV) during Difficult Airway Management

R Patel

## Citation

R Patel. *Use of Percutaneous Transtracheal Jet Ventilation (PTJV) during Difficult Airway Management*. The Internet Journal of Anesthesiology. 1998 Volume 3 Number 2.

## Abstract

A life threatening situation can occur if tracheal intubation and bag-mask-valve ventilation are unable to be performed in restoring adequate gas exchange during acute respiratory failure. Under these circumstances, percutaneous transtracheal jet ventilation (PTJV) using a large bore needle provides immediate oxygenation and ventilation. In the present case, PTJV proved to be a life saving procedure by providing adequate gas-exchange and ensuring the patency of the airway until a definitive procedure such as oral intubation with bronchoscopy followed by surgical tracheostomy was performed. Therapeutic indications and complications of PTJV are discussed.

## INTRODUCTION

Incidence of laryngeal edema following extubation is reported to be 4.2% with only 1% of patients requiring re-intubation for acute respiratory failure (1). The inability to view the glottic opening during direct laryngoscopy makes endotracheal intubation difficult. A life threatening situation can occur if intubation and bag-mask-valve ventilation are not performed to restore adequate gas exchange. Under these circumstances, percutaneous transtracheal jet ventilation (PTJV) using a large bore angiocath at the cricothyroid membrane is a life saving procedure. The objective of this report is to increase physician awareness of the potential benefit from PTJV as a temporary life saving procedure in cases of difficult or failed endotracheal intubation in the adult intensive care unit.

## CASE REPORT

A 67-year old male was admitted to a community hospital with an acute stroke and respiratory failure, and transferred to the medical intensive care unit for mechanical ventilation. He was orally intubated with an 8 mm Internal Diameter (I.D.) endotracheal tube without any difficulty on admission. Past medical history was significant for radiation therapy for laryngeal carcinoma 4 years prior to this admission. He was weaned from mechanical ventilation and extubated on day 14. Following extubation, he developed respiratory distress

and oxygen desaturation. Non-invasive face-mask continuous positive airway pressure failed to provide adequate oxygenation. Several attempts at oral intubation with direct laryngoscope were attempted, but proved unsuccessful because of inability to visualize the supraglottic and glottic structures. Pulse oxygen saturation could not be maintained with bag-mask-valve ventilation with 100% oxygen. In addition, his heart rate decreased to 30 beats/minute and systolic blood pressure was 70 mm of Hg. Immediately the cricothyroid membrane was cannulated with a 6 French (2 mm I.D., Cook Co., IN) angiocath and high-pressurized oxygen was provided with a jet ventilator (BE 183-SUR, Instrumentation Industries, Inc., Bethel Park, PA). While maintaining 100% oxygen saturation with manual trigger jet ventilator at 12 – 20 times per minute, an attempt at oral intubation was done with an 8 mm ID endotracheal tube. PTJV was discontinued. However, bronchoscopy evaluation was required because of oxygen desaturation, which confirmed esophageal intubation. The cricothyroid membrane was recannulated with an angiocath. He was ventilated and oxygenated with PTJV until oral intubation with a 7-mm ID endotracheal tube over bronchoscopy was performed using the jet bubbles coming from the glottic aperture as a guide. This was followed by tracheostomy. PTJV was discontinued. He was subsequently weaned from mechanical ventilation over 48 hours, and

transferred from the medical intensive care unit with a tracheostomy collar to the ward.

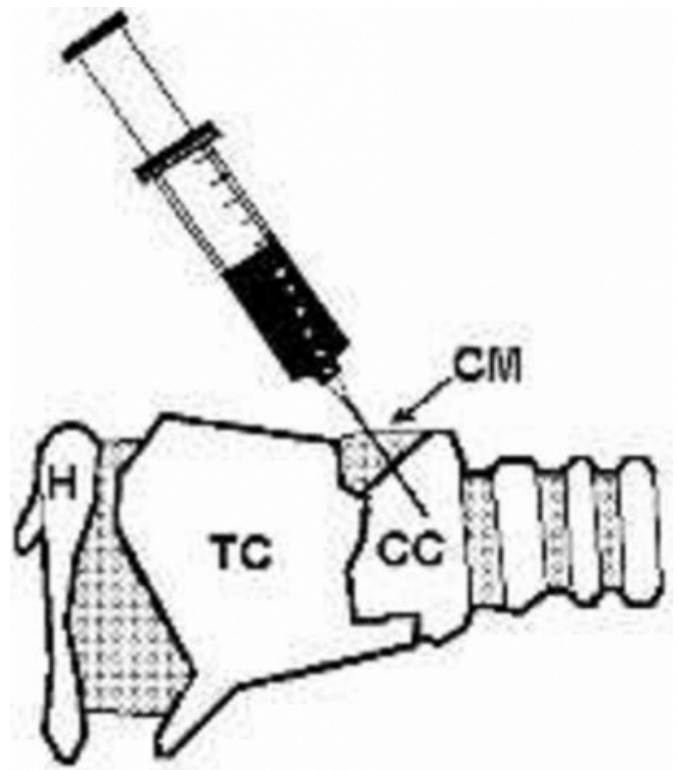
### DISCUSSION

Resuscitation with the use of PTJV during difficult intubation is not a new concept for the anesthesiologist (2, 3, 4), otolaryngologist (5, 6), and emergency room physician (7, 8). PTJV is not popular in the medical intensive care unit where the majority of endotracheal intubations in critically ill patients are managed by non-anesthesiologists. Familiarity with PTJV for immediate oxygenation during difficult or failed intubation can be life saving.

PTJV is relatively safe, simple, and requires little experience (9). Puncture of the trachea at the cricothyroid membrane with a large bore angiocath can be done readily with little trauma (figure 1). The pressurized oxygen can be delivered directly from the wall outlet. Inspiration is achieved by insufflation of pressurized oxygen with the jet ventilator. Expiration is passive secondary to the elastic recoil of the lungs and the chest wall. Air escapes through the glottic aperture creating a jet of bubbles at the oropharyngeal structure. This offered two advantages in the present case. First, escape of the high-pressurized air prevented the closure of the glottic aperture and secondly, jet of bubbles at the oropharyngeal structure guided the bronchoscope to the glottic aperture.

**Figure 1**

Figure 1. Insertion of the angiocath through the cricothyroid membrane into the trachea (H- hyoid bone; TC – thyroid cartilage; CC – cricoid cartilage; CM – cricothyroid membrane)



The most important benefit of PTJV in our case was immediate availability of oxygenation and ventilation. This was followed with an attempt of direct laryngoscope intubation that resulted in esophageal intubation. Subsequent recannulation of the cricothyroid membrane could have been avoided with the use of bronchoscope guided intubation or surgical airway during PTJV. In this case, arterial saturation greater than 90 % was maintained with the use of PTJV until bronchoscope guided intubation and bedside tracheostomy were performed. There are a variety of procedures that can be performed for immediate airway protection. These include – cricothyroidotomy, tracheostomy, fiberoptic intubation, use of stylet, and laryngeal mask airway. However, all these procedures require experience and are time-consuming. Even emergency tracheostomy takes a few minutes, which might have severe immediate and long-term consequences.

Several studies have documented the efficacy of PTJV. In the early fifties, Jacoby et al punctured the cricothyroid membrane with a 14-gauge needle in 5 patients during difficult intubation (2). Oxygen was insufflated intermittently through the needle while the surgeon or the

anesthesiologist proceeded with a tracheostomy or tracheal intubation. Later, Spoerel and his colleagues combined transtracheal ventilation with high-pressure jet ventilation in 12 patients during elective anesthesia (3). These authors demonstrated that normal blood gas levels could be maintained despite the induction of respiratory paralysis if patients were ventilated transtracheally with intermittent jets of oxygen through a 16-gauge needle. Yealy and colleagues have suggested the use of 12 – 16 gauge angiocath and 50psi oxygen will provide adequate tidal volume to maintain oxygenation and ventilation in apneic adults (7). In addition to ensuring adequate oxygenation (or even hyperoxygenation), this technique produces normocapnia or hypocapnia (5, 6, 8, 10).

There are other beneficial uses of PTJV beside the difficult or failed intubation. These include anticipated difficult or failed intubation (4), during cardiac arrest (10), and endoscopic laryngeal surgery (11). The complication rate with the use of PTJV is lower when performed as an elective than as an emergent procedure (4). Monnier and associates used PTJV in 65 patients who underwent laser endoscopic treatment of laryngeal and subglottic lesions (6). Only 1 patient developed a complication, which was cervico-mediastinal emphysema due to the dislodgment of the cannula; this was treated successfully with needle aspiration. Other complications with the use of PTJV are kinked catheters, lack of coordination of respiratory effort, acute hypoventilation, pneumothorax, and soft tissue emphysema (5).

### **CONCLUSION**

PTJV using a large bore needle to provide immediate oxygenation and ventilation is a fast, effective, simple and life-saving procedure when bag-mask-valve-ventilation and direct laryngoscope endotracheal intubation are ineffective

in critically ill patients. PTJV must be viewed as a temporary procedure to provide oxygenation and ventilation until a permanent airway can be secured. Standard intubation methods are preferable whenever they can be performed safely and rapidly. A unique feature in this case was PTJV proved to be a life saving procedure by providing adequate gas-exchange and ensuring the patency of the airway until a definitive procedure such as oral intubation with bronchoscopy followed by surgical tracheostomy was performed.

### **References**

1. Darmon JY, Rauss A, Dreyfuss D, et al: Evaluation of risk factors for laryngeal edema after tracheal extubation in adults and its prevention by dexamethasone. A placebo-controlled, double-blind, multicenter study. *Anesthesiology* 1992;77:245-251
2. Jacoby JJ, Hamelberg W, Ziegler CH, et al: Transtracheal resuscitation. *JAMA* 1956; 162:625-628
3. Spoerel WE, Narayanan PS, Singh NP: Transtracheal ventilation. *Br J Anaesth* 1971;43:932-939
4. Benumof JL, Scheller MS: The importance of transtracheal jet ventilation in the management of the difficult airway. *Anesthesiology* 1989;71:769-778
5. Weymuller EA, Pavlin EG, Paugh D, et al: Management of difficult airway problems with percutaneous transtracheal ventilation. *Ann Otol Rhinol Laryngol* 1987;96:34-37
6. Monnier PH, Ravussin P, Savay M, et al: Percutaneous transtracheal ventilation for laser endoscopic treatment of laryngeal and subglottic lesion. *Clin Otolaryngol* 1988;13:209-217
7. Yealy DM, Stewart RD, Kaplan RM: Myths and pitfall emergency translaryngeal ventilation: Correcting misimpressions. *Ann Emerg Med* 1988;17:690-692
8. Smith RB, Babinski M, Klain M, et al: Percutaneous transtracheal jet ventilation. *J Am Coll Emerg Physicians* 1976;5:765-770
9. Patel RG, Norman JR: The technique of transtracheal ventilation. *J Crit Illness* 1996;11:803-808
10. Jacobs HB, Smyth NPD, Witorsch P: Transtracheal catheter ventilation: Clinical experience in 36 patients. *Chest* 1974;65:36-40
11. Spoerel WE, Greenway RE: Technique of ventilation during endolaryngeal surgery under general anesthesia. *Can Anaesth Soc J* 1973;20:369-377

**Author Information**

**Rajesh G Patel, MD, FCCP**

Assistant Professor of Medicine, Department of Medicine, Medical Service, University of Mississippi Medical Center and G. V. (Sonny) Montgomery V. A. Medical Center