

Renal Angiomyolipoma Causing Pyonephrosis

M Wasif, M Rashid, H Haris, I Khan, S Abbas

Citation

M Wasif, M Rashid, H Haris, I Khan, S Abbas. *Renal Angiomyolipoma Causing Pyonephrosis*. The Internet Journal of Surgery. 2007 Volume 15 Number 1.

Abstract

A 35-year-old male presented with the complaints of pain in the left flank and fever. He was found to have a large septated pyonephrotic kidney due to uretral obstruction caused by a large angiomyolipoma at the middle and lower pole. The patient was operated and left nephrectomy was done. He recovered well after the operation with resolution of pain and fever. Patients with angiomyolipoma may suffer from complications like pyonephrosis; therefore, they should be monitored closely so that more conservative management in the form of transarterial embolisation and open partial nephrectomy could be employed rather than going for more radical treatments like total nephrectomy.

INTRODUCTION

Renal angiomyolipoma is a rare benign hamartomatous tumour of the kidney. Although histologically benign, these lesions can rupture spontaneously and result in retroperitoneal hemorrhage owing to their aneurysmal, tortuous blood vessels that constitute the angiogenic component of the tumor (1, 2). They are seen in two distinct clinical populations – a) tuberous sclerosis, b) sporadic form (3). Patients with tuberous sclerosis tend to have bilateral disease and are generally asymptomatic whereas those with sporadic form tend to have unilateral and symptomatic disease. It is characterized by three major histologic components: mature fat cells, smooth muscle cells and blood vessels. We report a case of a patient with angiomyolipoma presenting as pyonephrosis due to unilateral uretral obstruction. To our knowledge, pyonephrosis due to angiomyolipoma has not been previously reported.

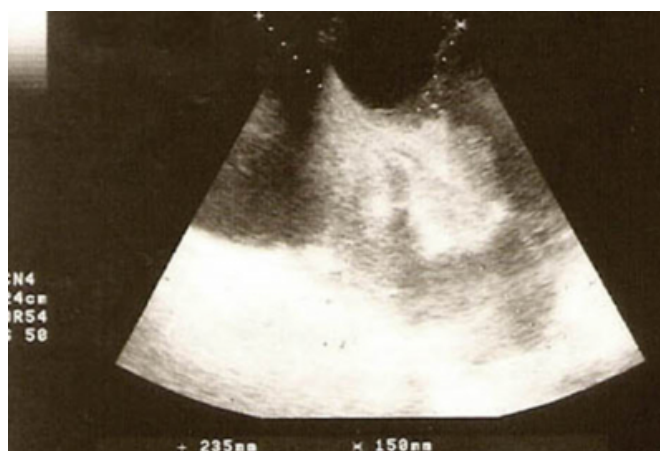CASE REPORT

A 35-year-old male patient presented to us with complaints of slowly growing mass and pain in the left flank for six months and fever for ten days. The examination of the patient revealed a large cystic lump in the left lumbar region extending into the left hypochondrium, iliac fossa and crossing the midline. The laboratory investigations showed Blood Urea of 65mg/dl and Serum Creatinine 2.2meq/dl. Ultrasonography showed a large septated cystic mass involving the left lumbar region reaching up to the right paraumbilical region (235 x 150mm) with the hyperechoic focus measuring 50 x 40mm in the center of the mass (Fig

1).

Figure 1

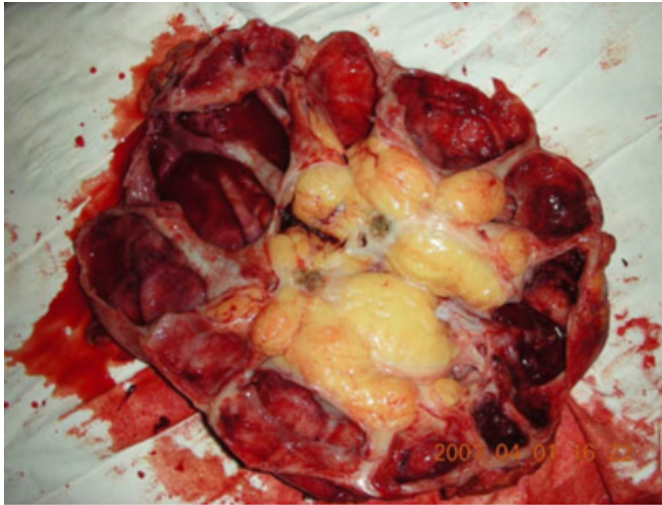
Figure 1: USG of left lumbar region showing a cystic mass replacing the whole of left kidney with an echogenic focus at the center.



The CECT of the abdomen and pelvis revealed a hypodense lesion of 5.3 x 4.2cm at the inferomedial aspect of the left kidney with non-functioning left kidney. The patient was operated through midline incision and a large multiloculated kidney filled with pus was found. There was a mass at the medial and inferior portion of the kidney. This had compressed the ureter leading to hydronephrosis which later got infected forming pyonephrosis. Total nephrectomy (Fig 2) was done and tissue was sent for histopathology.

Figure 2

Figure 2: Surgical specimen showing pyonephrotic kidney with angiomyolipoma at the middle and inferior pole.



The histopathological report was consistent with the diagnosis of angiomyolipoma with chronic pyelonephritis. The patient recovered satisfactorily and was followed up to a period of one month.

DISCUSSION

Renal angiomyolipoma was once considered to be a rare benign disorder but is now becoming a fairly common diagnosis often discovered incidentally with more widespread use of USG and CT scan (4). Flank pain, due to localized hemorrhage and/or inflammation, is both the most common presenting symptom and indication for intervention. The management of angiomyolipoma historically has been correlated with symptoms. Lesions less than 4cm can be followed up with yearly CT or USG.

Patients with asymptomatic or mildly symptomatic lesions greater than 4cm should be followed up with semiannual USG (3). Patients with lesions greater than 4cm with moderate to severe symptoms (bleeding or pain) should undergo renal sparing surgery or renal arterial embolization.

Although patients with angiomyolipomas may develop renal insufficiency or failure due to chronic compression and replacement of normal renal parenchyma by angiomyolipoma lesions, ureteral obstruction leading to pyonephrosis has not been described. We report the use of total nephrectomy in the treatment of pyonephrosis resulting from angiomyolipoma and recommend routine close follow-up of known patients with angiomyolipoma so that appropriate management could be employed in the form of nephron sparing surgery or transarterial embolization prior to the onset of irreversible renal damage.

CORRESPONDENCE TO

Dr. MUDDASSIR RASHID 301 RIFA APARTMENTS
MEDICAL ROAD DODHPUR ALIGARH, U.P, INDIA
202002 Phone: +919760014447 Email ID -
beighmuddassir@yahoo.com , beighmuddassir@gmail.com

References

1. Van Baal JG, Smith NJ, Keeman JN, Lindhout D, Verhoef S. The evolution of renal angiomyolipoma in patients with tuberous sclerosis. *J Urol* 1994; 152: 35-38
2. Mourikis D, Chatziioannou A, Antoniou A, Kehagias D, Gikas D, Vlahos L. Selective arterial embolization in the management of symptomatic renal angiomyolipoma. *Eur J Radiol* 1999; 32: 153-159
3. Steiner MS et al.: The natural history of renal angiomyolipoma. *J Urol* 1993; 150: 1782
4. Adilson Prando. Radiological Classification of renal lipomas based on 127 tumors. *International Braz J Urol* 2003; 29: 208-216

Author Information

Mohd Wasif, M.S.

Senior Resident, Dept. of Surgery, JN Medical College, AMU

Muddassir Rashid, M.D.

Resident, Dept. of Radiodiagnosis, JN Medical College, AMU

Hasan Haris, M.S.

Consultant, Dept. of Surgery, JN Medical College, AMU

Intezar Ahmad Khan, M.S.

Resident, Dept. of Surgery, JN Medical College, AMU

S. Naseer Abbas, D.M.R.D.

Resident, Dept. of Radiodiagnosis, JN Medical College, AMU