

# A case with patent ductus arteriosus and coarctation of aorta where aberrant right subclavian artery originates from the coarcted segment: Our successful surgical approach

A GURBUZ, B LAFCI, M AKSUN, T MESE, U YETKIN

## Citation

A GURBUZ, B LAFCI, M AKSUN, T MESE, U YETKIN. *A case with patent ductus arteriosus and coarctation of aorta where aberrant right subclavian artery originates from the coarcted segment: Our successful surgical approach*. The Internet Journal of Pediatrics and Neonatology. 2009 Volume 12 Number 1.

## Abstract

About 1% of live born children have congenital heart defects. In this study we present a case with patent ductus arteriosus and coarctation of aorta where aberrant right subclavian artery originates from the coarcted segment and our successful surgical approach.

## INTRODUCTION

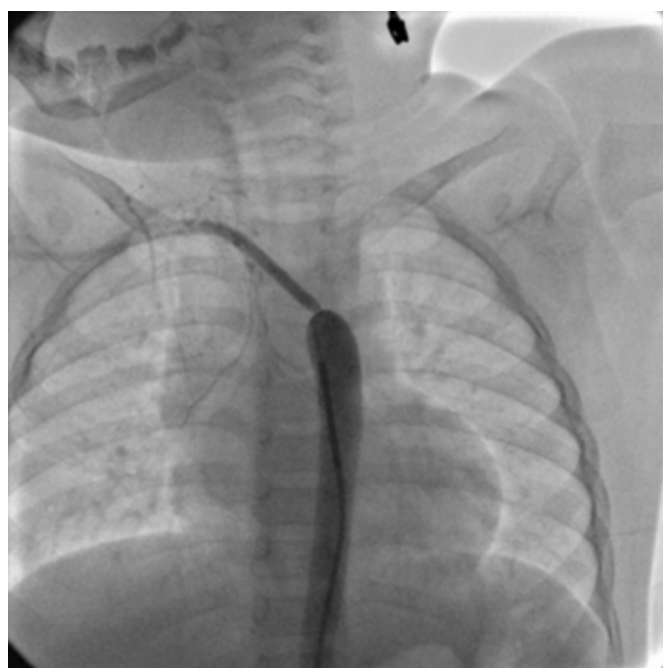
The first successful surgical repair of CoAo was performed in 1944 (1). The field of pediatric cardiac interventions has witnessed a dramatic increase (2).

## CASE PRESENTATION

Our case was a 2-year-old girl who was referred to our Pediatric Cardiology Unit after revealing a cardiac murmur during a physical examination following a fall from a chair 6 months ago. Her transthoracic echocardiography (TTE) showed patent ductus arteriosus (PDA), bicuspid aorta, coarctation of aorta (CoAo) and aortic arch anomalies. She was then prepared for cardiac catheterization. This procedure confirmed the diagnosis put via TTE. An additional finding was an aberrant right subclavian artery originating from the coarcted segment (RSCa)(Figure 1).

## Figure 1

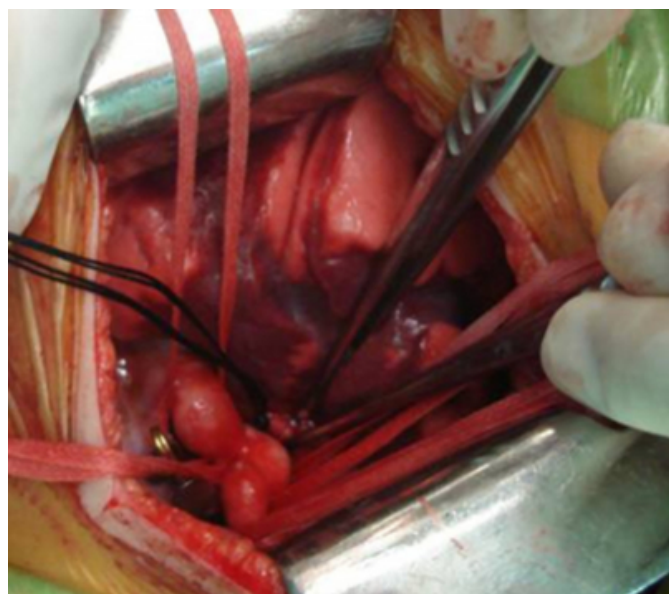Figure 1. Angiographic view showing the right subclavian artery originating from the coarcted segment



Our case was then taken to the operating room. At first, her PDA was ligated. Then, the coarcted segment was resected (Figures 2&3).

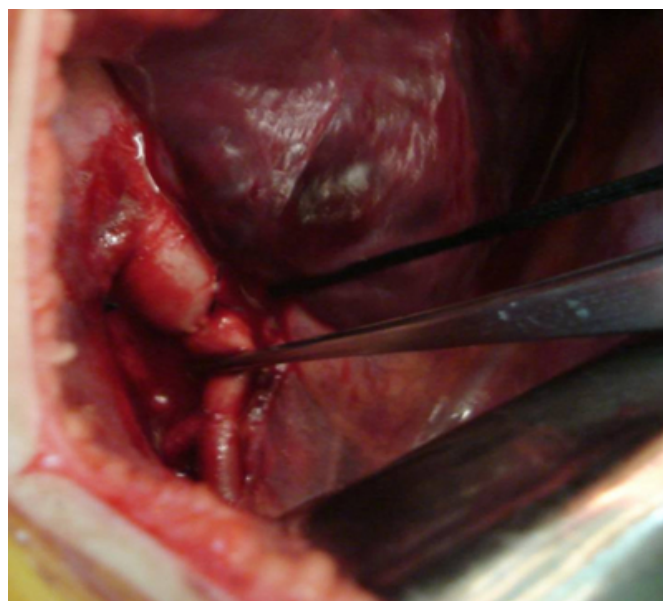
**Figure 2**

Figure 2. View of the coarcted segment and elements of the aortic arch after ligation of the PDA



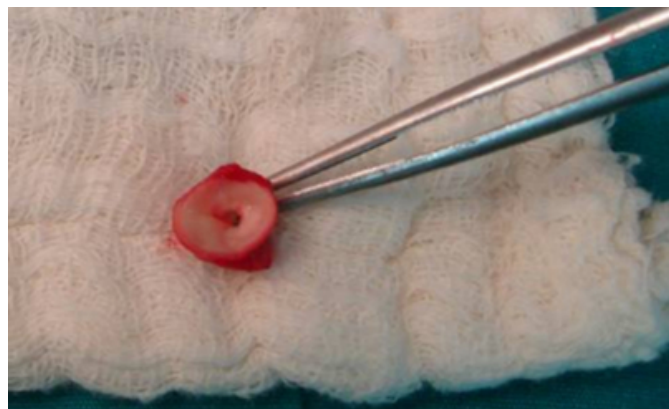
**Figure 4**

Figure 4. Translocation of the right subclavian artery onto the left subclavian artery



**Figure 3**

Figure 3. Extirpated coarcted segment



Afterwards, aortic arch and descending aorta were anastomosed in an end-to-end fashion. RSCa was then translocated and end-to-side anastomosed to the left subclavian artery (Figure 4).

During this procedure, right upper extremity pulses were monitored by sonic Doppler while continuously monitoring the viability of the extremity with pulse oximetry. The post-operative course was uneventful with successful correction. Postoperative echocardiographic data confirmed that coarctation gradient decreased from 26 to 6 mmHg after surgical correction and complete occlusion of the ductus arteriosus was achieved without any complication.

## DISCUSSION

In the study of Liu et al, most of the coarctation is complicated by PDA; 49% of their patients were complicated with PDA (3). Echocardiography is the first choice in the diagnosis of CoAo; however, angiography is still necessary in some cases. The outcome of the surgical correction is good and the majority of the patients have no symptoms (4).

## References

1. Backer CL, Paape K, Zales VR, Weigel TJ, Mavroudis C. Coarctation of the aorta. Repair with polytetrafluoroethylene patch aortoplasty. *Circulation* 1995 ;92(9 Suppl):II132-6.
2. Hijazi ZM, Awad SM. Pediatric cardiac interventions. *JACC Cardiovasc Interv* 2008 ;1(6):603-11.
3. Liu F, Huang GY, Liang XC, Sheng F, Lu Y, Wu L, Xu SM, Ning SB. Clinical features of coarctation of aorta: analysis of 96 cases. *Zhonghua Yi Xue Za Zhi* 2006 Jul 11;86(26):1854-6.
4. Stephensen SS, Sigfússon G, Eiríksson H, Sverrisson JT, Torfason B, Haraldsson A, Helgason H. Congenital heart defects in Iceland 1990-1999. *Laeknabladid* 2002 ;88(4):281-287.



**Author Information**

**Ali GURBUZ**

Clinic Chief, Assoc. Prof. in CVS, Department of Cardiovascular Surgery(CVS), Izmir Ataturk Training and Research Hospital

**Banu LAFCI**

Specialist, Assoc. Prof. in CVS, Department of Cardiovascular Surgery(CVS), Izmir Ataturk Training and Research Hospital

**Murat AKSUN**

Specialist in Anesthesiology, Department of Cardiovascular Surgery(CVS), Izmir Ataturk Training and Research Hospital

**Timur MESE**

Specialist in Pediatric Cardiology, Department of Cardiovascular Surgery(CVS), Izmir Ataturk Training and Research Hospital

**Ufuk YETKIN**

Clinical Deputy Chief, Assoc. Prof. in CVS, Department of Cardiovascular Surgery(CVS), Izmir Ataturk Training and Research Hospital