

# Maternal Mortality In Aortic Stenosis: Case Report With Review Of Literature

D Maurya, P Dasari, P P

## Citation

D Maurya, P Dasari, P P. *Maternal Mortality In Aortic Stenosis: Case Report With Review Of Literature*. The Internet Journal of Gynecology and Obstetrics. 2009 Volume 14 Number 2.

## Abstract

Aortic stenosis is uncommon during pregnancy as most patients with bicuspid valves who develop stenosis do so after the age of 50-60 yrs. Contrary to this majority of pregnant women who develop aortic stenosis have congenital stenotic valves as rheumatic disease most often affects mitral valve first and later aortic and other valves<sup>1</sup>. The maternal as well as perinatal mortality are reported to be high, 17.4% and 31.6% respectively<sup>2</sup>. The management policies vary as the condition is uncommon and there is some evidence that aortic valve replacement during pregnancy results in good maternal and perinatal outcome. Here we report a case severe aortic stenosis which resulted in maternal death due to lack of consensus regarding management.

## INTRODUCTION

Aortic stenosis is uncommon during pregnancy as most patients with bicuspid valves who develop stenosis do so after the age of 50-60 yrs. Contrary to this majority of pregnant women who develop aortic stenosis have congenital stenotic valves as rheumatic disease most often affects mitral valve first and later aortic and other valves<sup>1</sup>. The maternal as well as perinatal mortality are reported to be high, 17.4% and 31.6% respectively<sup>2</sup>. The management policies vary as the condition is uncommon and there is some evidence that aortic valve replacement during pregnancy results in good maternal and perinatal outcome. Here we report a case severe aortic stenosis which resulted in maternal death due to lack of consensus regarding management.

## CASE

A 24 year second gravida with a prior Caesarean section attended antenatal OPD at 29+3 weeks of gestation. She was a known case of Aortic stenosis diagnosed 3 yrs back during her first trimester of previous pregnancy. Her pregnancy was managed in a teaching hospital and she underwent elective caesarean section because of heart disease, most probably severe aortic stenosis. Her baby was alive, low birth weight 1.9 kg and there was no history of significant post-operative problems. She did not practice any contraception after this delivery.

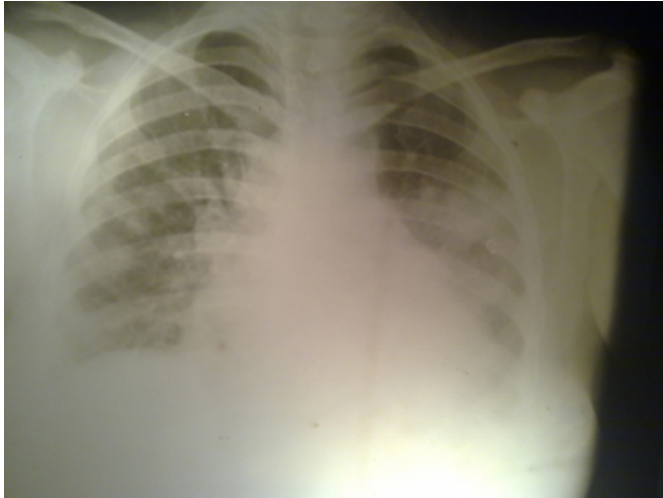
During the present pregnancy she was evaluated in the same

Institution during her second trimester of pregnancy. Echo was reported as congenital bicuspid stenotic aortic valve, severe AS, severe PAH with adequate LV function. USG evaluation of pregnancy reported as single live fetus of 23 weeks gestation without any anomalies.

When she attended our antenatal OPD she gave history of cough with expectoration and difficulty in breathing of 2 weeks duration. Her pulse was regular with a rate of 110 per minute and there was a systolic murmur of Grade III. She was not on any cardiotonics. She was hospitalised and was referred to Cardiologist for further evaluation. ECHO performed the next day of admission showed severe AS of Bicuspid valve, Pressure gradient (PG) was 109 mm Hg with a mean of 59 mm Hg, the right ventricular systolic pressure (RVSP) was 60 mm Hg, the mitral valve was normal and the left ventricular (LV) function was normal. She was advised to review in Cardiology 6 weeks post-partum. However, she was not discharged as she had orthopnea and tachycardia. Her cough was thought to be due to URI and she was treated with tablet Azithromycin for 5 days for which she did not respond and developed high grade fever 10 days after admission and there were wide spread bilateral crepitations and ronchi. Sputum culture and blood culture were sent and she was started empirically on injection ceftriaxone 1 gm 12 hrly. As the patient did not show the expected response after 48 hrs of antibiotics an X Ray chest P/A was performed (with abdominal shielding) which showed patches of pneumonia ( Fig 1) especially in the left mid zone.

**Figure 1**

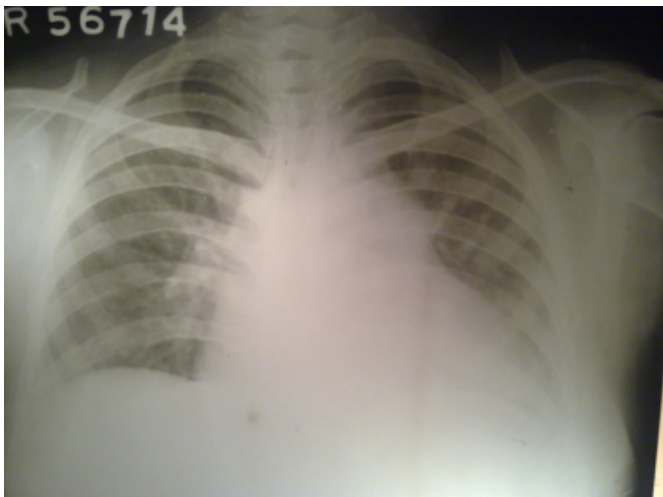
Fig 1 A



Sputum culture and blood culture were sterile, HIV was non reactive and AFB smear was negative. Chest Physician consultation was sought after this and they opined it to be cardiogenic pulmonary oedema. Repeat consultation with Cardiologists was undertaken who opined the same as that of Chest Physicians and advised to treat with tablet Frusemide 20 mg daily and she was started on this and continued Ceftriaxone for 7 days after which her fever subsided but the crepitations and ronchi persisted for 2 weeks and she continued to have Orthopnea. A repeat X-Ray chest was performed which showed resolving pneumonia (Fig 1 B)

**Figure 2**

Fig 1 B



The case was discussed again with Cardiologists with a request for valvotomy. ECHO was repeated at this point of time which was reported as severe AS, PG equal to 55 mm Hg, RSVP equal to 60 mm Hg, severe TR and normal left

ventricular function and the opinion regarding valvotomy was deferred. She was later treated symptomatically with asthalin nebulisation and was on tablet Furesemide. She was counselled and decided for elective LSCS with sterilisation at 37 completed weeks

At 35+2 weeks at 1 AM she developed leaking for vaginum and had tachycardia and tachypnoea (NYHA class IV). and gone in to preterm labour. She was managed by the Emergency labour room team. She was kept in propped up position and was given nasal oxygen and started on Infective Endocarditis prophylaxis. and was continuously monitored. Her condition which gradually deteriorated was shown in table 1. She developed hypotension and tachycardia after 3 hrs and fetal distress after 4 hrs and was decided for emergency CS. Because of the poor general condition, anaesthetists deferred and delayed in discussing to give anaesthesia for more than 2 hrs and the fetal heart was absent on OT table. Anaesthetists made efforts to bring the Cardiologists to OT to consider for emergency valvotomy as it was decided to proceed with LSCS for maternal indication. Emergency ECHO on table showed vegetation of 1.7x 2cm on aortic valve. Aortic valve doming and subaortic membrane was visualised, Dilatation of ascending aorta up to 4 cm without any dissection or coarctation. IVC dilatation was also present. There was evidence of severe TR with right ventricular systolic pressure of 40 mm Hg. No vegetations on mitral or tricuspid valves and there was no evidence of pericardial effusion. The oxygen saturation was not picked up by the pulse oxymeter and only heart rate was monitored and the BP was between 80-85/50-55 mm Hg. Pervaginal examination after 3 hrs of shifting to the OT was 9 cm and delivery was effected with vaccum application without any complications. The third stage was normal and the previous scar felt intact. She sustained a cardiac arrest after half an hour on the OT table from which she could not be revived.

**Figure 3**

Table 1

Hours since in labour	Consciousness	Pulse	BP	RR & SpO2	SPO2	Uterine action	FHR	Cervix dilatation	Expert opinion	Other
9 hr (2 AM)	Conscious	120/min	120/80	30/min R-Clear	98%	acting mildly	140/min	2 cm	OBG-consistant to monitor progress	
2 hr (2 AM)	"	120/min	"	"	"	"	140/min	"	"	
3 hr (4 AM)	"	120/min	100/60	32/min	98%	"	150/min	"	"	
4.30 AM	"	140/min	90/60	40/min	"	moderate	"	"	Medicine reference-CCU reference	
5.30 AM	"	140/min	not recordable	40	"	"	120/min	"	"	
5 hr (6 AM)	"	120/min	"	40/min	98%	"	120/min	"	cardiology reference	Dopamine infusion
6.30 AM	"	120/min	"	"	"	moderate	120/min	"	"	
6 hr (7 AM)	"	140/min	"	40/min	98%	"	80/min	"	Em Of Anaesthesia discussion call sign sent	
7 hr (8 AM)	"	"	"	44/min	"	moderate	60/min	"	"	
8 hr (9 AM)	conscious	flexible	85/55	42/min	NPP	abrupt	"	"	shifted to OT table	O2 by mask
8 hr (9 AM)	"	HR-140-150	80/50	40/min	"	"	"	"	arterial line in aorta	Cardiologist called to OT
10 AM-11 AM	"	"	"	42/min R-Clear	"	moderate	"	"	ECHO by Cardiologist	Vegetation on aortic valve
9 hr (11 AM)	"	"	"	44/min	"	good	"	3 cm	"	
12-12.30 AM	"	"	"	44/min	"	"	"	"	Vacuum delivery	Uterine tear intact
22.50 AM	unconscious	HR-151	85/55	46/min	"	"	"	"	aspirin parition	"
(10 hrs) 12 Noon	"	"	"	"	"	"	"	"	"	Cardiac arrest

CPR by anaesthetic team

NPP- O2 saturation not picked up by Pulse Oxymeter

## DISCUSSION

Bicuspid aortic valve is more common in men than in women and is diagnosed in 2 to 3 % of the population and this is one of the reasons why AS is uncommon in pregnancy. AS produces obstruction to the left ventricular outflow resulting in pressure overload and overwork on the part of the left heart which in turn results in left ventricular hypertrophy. Symptoms are usually not related to the degree of stenosis as patients with severe stenosis i.e., aortic valve area less than 1 cm<sup>2</sup> may be asymptomatic. But once symptoms develop the mortality is as high as 50 % in 2 years and in asymptomatic younger individuals. The documentation of severe stenosis should be an indication for intervention as it is frequently a progressive disease, the severity increasing over time. Later, as the severity of AS increases progressively, the cardiac output remains within the normal range at rest, but, on exercise, it no longer increases in proportion to the amount of exercise undertaken or does not increase at all (fixed cardiac output)<sup>3</sup>. This situation prevails during labour as labour is considered to be equal to severe exercise. During each contraction, the cardiac output increases by 20% in addition to the increase in cardiac output caused by the physiological expansion of blood volume during pregnancy.

A residual gradient greater than 20 mmHg or persistent left ventricular hypertrophy are considered to be contraindications to vigorous physical activity.<sup>3</sup> This fact needs to be applied to a patient with AS who is pregnant. In

the present case her first pregnancy was managed optimally and delivery was affected by CS thus avoiding the change of haemodynamics that occur with vigorous exercise such as labour contractions. The course of her symptoms worsened with the duration of disease and as well as during labour (Table). Asymptomatic women with mild aortic stenosis and normal left ventricular function can successfully carry pregnancy to term and have vaginal delivery.<sup>4</sup>

Valve replacement has to be undertaken in severe stenosis with calcified valves and pregnancy is not a contraindication for this. Improvement of the hemodynamic status and subsequent vaginal delivery in a 36 years old patient was reported by Mooij PN and colleagues after valve replacement during second trimester of pregnancy<sup>5</sup> Significant morbidity and mortality occurs if valve replacement is delayed to the postpartum period<sup>6</sup>.

Aortic valve replacement may also be undertaken during third trimester with good maternal and fetal outcome,<sup>7,8</sup> or it may be combined with caesarean section when good neonatal facilities are available<sup>4</sup>. Percutaneous balloon valvotomy also can be undertaken as a palliative procedure in severe aortic stenosis until after delivery in selected cases<sup>4</sup> as the operative mortality for aortic valve replacement itself was reported to be 7%±1%<sup>9</sup>. Presence of infective endocarditis further adds to mortality in aortic stenosis. But challenging management includes valve replacement in such a situation combined with emergency caesarean can save life.<sup>10,11</sup> Presence of vegetations on the aortic valves in the present case led to giving up of hope even in resuscitating this patient where as the case reported by Nyawo B and colleagues impending cardiac collapse made them to proceed with emergency caesarean section and aortic valve replacement which resulted in good outcome<sup>11</sup>.

In preventing maternal mortality due to aortic stenosis one has to keep in mind the progressive nature of severe aortic stenosis and the fixed cardiac output which does not increase during uterine contraction thus throwing the patient in to severe decompensation and sudden cardiac death. As it was reported that haemodynamically symptomatically severe aortic stenosis and regurgitation have very poor prognosis and require immediate valve surgery<sup>12</sup>, pregnancy and labour should not be contraindications for such an approach. The benefits of valve replacement in asymptomatic patients with severe aortic stenosis may also to be thought of prior to pregnancy and labour as the omission of surgical treatment in severe aortic stenosis results in late mortality<sup>13</sup>. The

reasons for maternal mortality in the present case include omitting the valvotomy or valve replacement early after admission and allowing the patient to go through the severe exercise of uterine contractions for a period of approximately 10 hrs and the delay and the reluctance of the anaesthesiologists to anaesthetise the patient for almost 5 hours after a decision for emergency caesarean was made. This is a typical delay contributing to maternal mortality at the level of Institute mainly because of lack of consensus in the management.

### CONCLUSION

This case illustrates the severity of aortic stenosis and the complications during pregnancy and labour. Elective caesarean section during her first pregnancy saved her life but omission of the same in emergency has taken her life during the second pregnancy leaving behind her first child as motherless. The literature reviewed reveals the benefits of early valve replacement in severe aortic stenosis and its life saving nature even in the presence of bacterial endocarditis. Patients with mild aortic stenosis can have safe vaginal delivery but severe aortic stenosis warrants valve replacement prior to labour to save maternal and fetal life.

### References

1. Easterling TR, Otto C. Chapter 29: Heart Disease in Gabbe Obstetrics-Normal and problem pregnancies. 4th edition. Churchill Livingstone. 2002; 1005-1032.
2. Arias F, Pineda J. Aortic stenosis and pregnancy. J Reprod Med. 1978;20:229-32.
3. Mathews R. Cardiology [rjm.md@rjmatthewsmd.com](mailto:rjm.md@rjmatthewsmd.com).
4. Datt V, Tempe DK, Viramani S, Datta D, Garg M, Banerjee A, Tomar AS. Anaesthetic management for emergency cesarean section and aortic valve replacement in a parturient with severe bicuspid aortic valve stenosis and congestive cardiac failure. Ann Card Anaesth 2010;13:64-68.
5. Mooij PN, de Jong PA, Bavinck JH, Korsten HH, Bonnier JJ, Berendes JN. Aortic valve replacement in second trimester of pregnancy: a case report. Eur J Obstet Gynecol Reprod Biol. 1988;29:347-52.
6. Easterling TR, Chadwick HS, Otto CM, Benedetti TJ. Aortic stenosis during pregnancy. Obstet Gynecol. 1988;72:113-118.
7. Eilen B, Kaiser IH, Becker RM, Cohen MN. Aortic valve replacement in the third trimester of pregnancy. Case report and review of literature.
8. Ben-Ami M, Battino S, Rosenfeld T, Marin G, Shalev E. Aortic valve replacement during pregnancy. Case report and review of literature. Acta Obstet Gynecol Scand 1990;69:651-653.
9. Scutt WC, Miller DC, Haverich A, et al. Determinants of operative mortality for patients undergoing aortic valve replacement. Discriminant analysis of 1,479 operations. J Thorac Cardiovasc Surg 1985;89:400-413.
10. Vincelj J, Sokol I, Pevec D, Sutlic Z. Infective endocarditis of aortic valve during pregnancy. a case report. Int J Cardiol. 2008;126(1):e-10-2.
11. Nyawo B, Shoaib RF, Evemy K, Clark SC. Infective endocarditis during pregnancy- a case report. Heart Surg Forum. 2007;10(6):E480-1.
12. Tiruna J, Hess O, Sepulcri F, Kräyenbühl HP. Spontaneous course of aortic valve disease. Eur Heart J. 1987;8:471-83.
13. Brown ML, Pellikka PA, Schaff HV et al. The benefits of early valve replacement in asymptomatic patients with severe aortic stenosis. J Thorac Cardiovasc Surg. 2008;135:308-315.

**Author Information**

**Dilip Kumar Maurya, MD**

Assistant Professor, Dept of OBS&GYN, JIPMER

**Papa Dasari, MD,DGO, FICOG**

Professor, Dept of OBS&GYN, JIPMER

**Pallavi P, MD**

Senior Resident, Dept of OBS&GYN, JIPMER