

# Initial Experience Using 4D Electromagnetic Navigation Bronchoscopy System With Tip Tracked Instruments For Localization of Peripheral Lung Nodules

E L Flenaugh, K H Mohammed

## Citation

E L Flenaugh, K H Mohammed. *Initial Experience Using 4D Electromagnetic Navigation Bronchoscopy System With Tip Tracked Instruments For Localization of Peripheral Lung Nodules*. The Internet Journal of Pulmonary Medicine. 2016 Volume 18 Number 1.

DOI: [10.5580/IJPM.37993](https://doi.org/10.5580/IJPM.37993)

## Abstract

We performed a retrospective analysis of an initial forty-four consecutive patients recommended for localization and sampling of small peripheral pulmonary nodules (PPN). Learning curve, patient safety, and diagnostic yield of a 4D respiratory tracking electromagnetic navigation (4D EMN) biopsy system are reported. Peripheral lung nodule average size was 22.1 mm +/- 9.8 mm. The 4D EMN system used an inspiratory and expiratory CT scan and electromagnetic (EM) patient trackers were placed on the patient to trace the patient's respiration. The 4D EMN system uses small EM sensors integrated into standard bronchoscopic instruments to provide location tracking to the clinician.

The 4D EMN system reliably provided effective yields at our facility for PPNs while reducing the risk to the patient for pneumothorax. The overall diagnostic yield was 90.2% (37/41); with no pneumothorax or other complications reported. During this period the 4D EMN system was used for precision placement of fiducials for treatment purposes in two patients.

## BACKGROUND

Lung cancer remains the number one cancer killer in the United States; causing more deaths than liver, prostate and breast cancer combined.[1] With the implementation of lung cancer screening programs across the U.S. growing, there will be significantly more solitary pulmonary nodules (SPN's) or peripheral pulmonary nodules for pulmonologists to safely diagnose and manage. Faced with the probability that greater than 96% of these nodules may be benign, [2] pulmonologist must adopt new tools to accurately localize, sample, and diagnose these nodules with a high yield and low complication rate.

Guidelines such as Lung-RADS have been developed to help physicians determine how to manage these nodules. [3]

Lung-RADS Recommendation 4A states nodules measuring 8-15 mm should be biopsied. Options for biopsy have traditionally included using CT guided transthoracic sampling which has reported diagnostic yields approaching 90%. Unfortunately for lung nodules less than 2cm in diameter the diagnostic yield of transthoracic needle aspiration (TTNA) or transthoracic needle biopsy (TTNB)

decreases significantly, approaching 50% with an increased pneumothorax rate ranging from 30-60% [4,5].

In an effort to improve diagnostic yields, decrease procedure complications, and limit patient morbidity, pulmonologists have been using electromagnetic navigated bronchoscopy (ENB) and radial EBUS (R-EBUS) systems as an alternative solution to traditional bronchoscopic biopsy of PPNs. Published results describe a high variance among studies when reporting on diagnostic yield. [5,6,7]. ENB systems not using 4D EMN technology have generally reported yields in the 70% range for lung lesions with sizes averaging 2.7cm. Unfortunately, it has been difficult to determine the yield for lesions smaller than 2cm; or, to determine if these yields are based on lesion with or without the presence of a bronchus sign. This has resulted in a practice where smaller nodules recommended for biopsy are instead followed with watchful waiting.

Over the past several years 4D EMN technology based systems have proven to be effective at sampling peripheral SPN's, while providing cost effective approaches to

diagnose patient populations [9]. The 4D EMN systems have implemented technology to compensate for respiratory motion and address the inaccuracies of older ENB systems associated with nodule motion during inspiratory and expiratory phases of the respiratory cycle. [10,11]. The use of tip tracking the sampling instrument with the 4D EMN system insures the endoscopist the ability to biopsy from the targeted nodule in real-time. We report our initial experience with this technology and the impact on clinical practice.

## **STUDY DESIGN**

We performed a retrospective chart review that included a 12 month longitudinal follow up reporting findings of diagnostic test reports, patient medical records, and surgical biopsy reports. Detailed information was collected regarding the inspiration (INSP) to expiration (EXP) nodule motion, safety and diagnostic yield. The majority of patients were followed for confirmation of final diagnosis and/or treatment. When clinically indicated, additional procedures such as CT guided fine-needle aspiration, or surgery were performed during the twelve (12) month period.

Radiological surveillance was completed and summary findings were compiled with outcome measures.

## **STUDY OBJECTIVE**

The primary objective of this study was to measure the diagnostic yield of the 4D EMN system for the first consecutive 44 patients to verify from the clinician's perspective if 4D EMN was an effective procedure. Secondary objectives included the assessment of the overall complications of the 4D EMN system, differences in diagnostic yield associated with nodule location, and differences in diagnostic yield relative to respiratory motion between INSP and EXP states. All procedures were performed by one physician at a large metropolitan hospital.

## **METHODS**

We performed a retrospective analysis of the first consecutive forty four patients referred to our interventional pulmonologist for evaluation of peripheral pulmonary nodules using a diagnostic 4D EMN system. All procedures were performed by a single interventional pulmonologist at a large metropolitan community hospital between April 2014 and December 2014. Patients provided standard procedural consent before the procedure. The protocol for retrospective analysis was reviewed by an independent Committee for Ethical Research and determined that it did not require IRB

approval. Enrollment was halted December 2014 to allow analysis of 12 month follow-up data.

## **PROCEDURE DETAILS**

### **4D Respiratory Tracking**

A patient tracker with multiple EM sensors was placed on the patient's chest to provide automatic registration between CT image space and patient space. This same patient tracker provides 4D respiratory tracking, similar to a bellows, to indicate to the user when the patient is at the same breathing state as the acquired scan. Another benefit of the patient tracker provides dynamic referencing, which allows the patient to move or cough while maintaining registration throughout the procedure. This aids in patient comfort and prevents motion artifact during the procedure.

### **4D EMN Procedure Mapping**

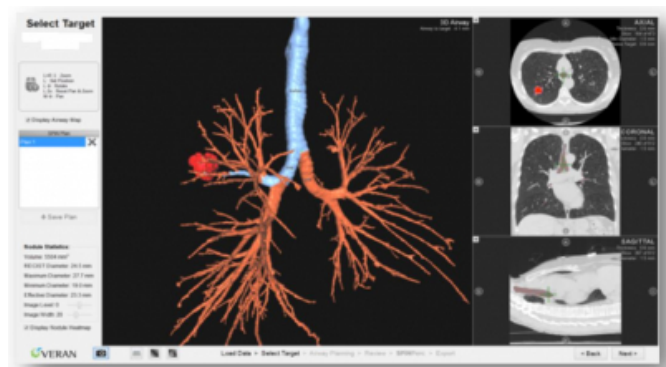
The 4D EMN system (Veran Medical Technologies SPiNDrive System, St Louis, MO) was used to gain local access to the PPN. A protocol using hybrid inspiration-expiration CT scan pairing was used to create a tidal volume expiration CT map for navigation. To validate the accuracy of the localization method we focused on the system accuracy relative to the amount of motion that was determined between INSP and EXP movement.

### **Navigation**

The 4D EMN SPiNDrive system has miniature EM sensors at the tip of our routine bronchoscopic sampling devices, including brushes, forceps and needles, as well as a steerable catheter. For nodules in the extreme periphery of the lung, and at the clinical discretion of the pulmonologist, the small 3.2mm OD View Peripheral Steerable Catheter was used with or without optics to provide a real-time EM tracked working channel. Figure 1 below illustrates a typical planning screen of the 4D EMN SPiNDrive system. Axial, Coronal and Oblique CT cut planes are provided as well as 3D rendered airway views from the perspective of flying through or flying above the airway.

**Figure 1**

SPiNDrive Planning screen.



### Biopsy Technique

All procedures were performed using a conscious sedation protocol with intravenous Versed (midazolam-HCl: 6mg) and fentanyl (75-125 mcg). Local anesthesia consisted of topical lidocaine in the oropharynx and airways as required throughout the procedure. No fluoroscopic guidance was utilized for biopsy procedures. Radial EBUS was used for real time confirmation in 20 of the procedures by inserting through the bronchoscope or steerable catheter working channel once the PPN had been localized. Procedure times ranged from 45 to 90 minutes for the total procedure. Planning times ranged from 4 to 10 minutes. Most biopsies were taken with forceps, either EM tip tracked or with conventional forceps passed through the working channel of an EM tip tracked steerable catheter. The mean number of samples was  $7.5 \pm 1.5$  with a range of 2 to 14. One procedure required completion using a percutaneous approach with a SPiNPerc tip tracked needle.

### Reporting the Findings

Pathologic reporting has established protocols at our institution where the terms negative / positive and non-diagnostic are replaced with precise histologic descriptions or normal parenchyma, respectively. Biopsies with histology showing malignant cells were categorized as true positive for malignancy. Those with histologic abnormalities (inflammation, fibrosis, etc.) that were consistent with the clinical or radiographic course, as determined during multidisciplinary follow up, were categorized as true negative for malignancy. Those with histology showing normal lung parenchyma or histology that wasn't consistent with clinical presentation were considered non-diagnostic and additional sampling was pursued during multidisciplinary follow up to determine false negative or

true negative categories.

## RESULTS

All patients were referred to the interventional pulmonologist for localization of pulmonary lesions suspicious for malignancy found on CT scans. Forty four patients included 23 males and 21 females ranging in age from 42 to 87 years with a mean age of 62.4 years. The average size of the lung lesion ranged from 9.4 to 54 mm with an average effective diameter of 22.1 mm. Forty patients received a transbronchial biopsy. One procedure completed using a percutaneous approach with the SPiNPerc tip tracked needle and was found to be malignant from two core biopsy samples. Another procedure was stopped without taking a biopsy due to the lack of a bronchoscopic pathway to the lesion. Two procedures were fiducial placements for our radiation oncology group; both procedures were found to be accurate relative to placement using the 4D EMN procedure. There were a total of 71 lesions biopsied averaging 1.6 lesions for the 44 patients.

Lung lesions were evenly distributed across the lung with 35 located in the upper lobes and 36 in the lower lobes. More specifically, 19 were located in the RUL, 16 located in the LUL, 6 located in the RML, 15 located in the RLL and 15 located in the LLL. The overall prevalence of malignancy in our study was 39.0% (16/41). Compared to recent studies 39.0% is well within findings of 37% and 42.5% malignancy rates respectively in their high risk patient populations.[21,6] This prevalence rate is emerging as a representative number of positive findings, despite the 20% finding in the NLST. Community pulmonologists may expect similar incidence of lung cancer when seeing patients who meet the USPSTF inclusion criteria, or have a positive CT referred for biopsy or surgical resection to verify suspect lung cancer. Given this higher percentage, invasive means of lung cancer detection are critical to maintain the patient's health as they progress through treatment after being diagnosed with Stage I or II lung cancer.

The average nodule movement between INSP and EXP was calculated to be  $12.3 \pm 7.3$  mm. Upper lobe movement was  $10.6 \pm 6.8$  mm, lower lobe movement was  $14.0 \pm 7.3$  mm. The maximum nodule movement was found to be 28.6 mm. When using 4D respiratory tracking and adopting a hybrid inspiration-expiration CT scan pair protocol, we identified this motion was greater than half the nodule size for 52% (37/71) of the nodules. Without using 4D respiratory tracking, the variation in inspiration/ expiration

would have contributed to completely missing the target. While significant movement relative to the size of the nodules being targeted was measured between the INSP and EXP state, we found the SPiNDrive system to be very accurate in compensating for this motion.

The 44 patients had 71 lesions that were biopsied; there were 7 nodules that were 10 mm or smaller, 16 nodules that were 11 to 15 mm in size, 24 lesions 16 to 20 mm in size, 15 nodules that were 21-30, 6 lesions 31 to 40 mm and 3 lesions larger than 41mm in size.

**Table 2**

Breakdown of Number of Lesions and Size

Size(mm)	Volume (mm <sup>3</sup> )	Number of lung lesions
<10	524	7
11-15	1767	16
16-20	4,189	24
21-25	8,181	6
26-30	14,137	9
31-40	33,510	6
41-60	113,097	3

**Table 3**

Location of Lung Lesion by Lung Quadrant

Location	Number of lung lesions
RUL	19
RML	6
RLL	15
LUL	16
LLL	15

## Findings and Patient Management

Thirty-seven of 41 (91.2%) patients had a correct diagnosis during their 4D EMN procedure. Sixteen patients were determined to have a malignancy using the 4D EMN biopsy, and 21 patients were determined to be true negative for a malignancy. There were 25 patients initially found not to have a malignancy and were managed using standard accepted protocol, focused clinical team assessment, and most were included in a longer-term patient management. This high level of specificity for a true negative finding reflects similar findings currently in press using the 4D EMN system. [19]

Among the 25 patients, 3 were diagnosed with inflammation treated with antibiotics, one had a hamatoma and one was diagnosed with a papilloma. Based on patient requests and

risk indicators, 2 patients were scheduled for a follow up TTNA biopsy procedure, and 3 patients were scheduled for a surgical resection biopsy. Of these 5 patients, two were found to be malignant and three were found to be benign. Pathology requested additional tissue for 1 patient that was initially reported as having suspicious malignant cells and a second 4D EMN procedure was performed that was found to be diagnostic for malignancy. These patients were diagnosed with early stage (I and II) as intended by the USPSTF.

Fourteen patients in the negative cohort were followed using a serial imaging protocol at 3-6 and 9-12 months during the study timeframe. Four of these 14 patients had a nodule that disappeared during follow up scanning. The remaining 10 patients are continuing to be followed up with a serial CT or X-ray scan according to recommended guidelines and have shown no signs of nodule growth; all having over 12 months of follow up. There was no pneumothorax (0%) complication in the study. No additional complications were reported for the patient group, and no complications occurred related to the hybrid INSP-EXP EMN protocol.

**Table 4**

Findings of 25 Patients With Initial Negative Findings

Diagnosis During Follow Up	Patients Followed	Diagnostic Finding	Disease Presence Breakdown	% of total diagnoses
Further Biopsy	3	Inflammation	3	12.0%
Further Biopsy	1	Hamatoma	1	4.0%
Further Biopsy	1	Papilloma	1	4.0%
TTNA	2			8.0%
		Malignant	1	
		Benign	1	
Surgical Resection	3			12.0%
		Malignant	1	
		Benign	2	
4D EMN Repeat	1			4.0%
		Malignant	1	
CT - No longer visible	4			16.0%
CT Stable - 12+ mo.	10			40.0%

## DISCUSSION

As lung cancer screening becomes commonplace in clinical practice, pulmonary specialists will increasingly encounter the challenge of accurately diagnosing smaller peripheral lesions in a fashion that will provide a favorable yield while minimizing complications. ENB systems were developed with the purpose of localizing and sampling smaller peripheral lung lesions. However, earlier ENB technology did not compensate for 4D patient motion and required the addition of radial EBUS and/or fluoroscopy for confirmation of target location and sampling, respectively.

In our review of published navigation bronchoscopy literature (Table 1), we found that fluoroscopic imaging was

a significant contribution to the navigation experience and overall yield of physicians using earlier technology. Eberhardt [12] reported 59% yield for ENB with a lesion size of 28 mm + 8 mm, and diagnostic yields dropped to 29% for lower lobes. Eberhardt states that this reduced yield rate is most likely due to the use of CT images acquired at total lung capacity. These images cannot compensate for inaccuracies associated with respiratory motion. Nabavizadeh [13] used an ENB system in conjunction with radial EBUS and fluoroscopic guidance to achieve a reported yield of only 32% while placing fiducials for SBRT. The fiducial placements were found to be 10 to 50 mm from the lesion surface in 27% of the patients. Makris [14] used an ENB system without respiratory tracking to achieve 62.5% yields for lesions that had an average size of 23.5 mm. Becker [15], Schwarz [16] and Gildea [17] used an ENB system in conjunction with fluoroscopic guidance to achieve 69%, 69% and 73% respectively for lesions averaging 33.5 +/- 11 mm in size with a range of 19 to 45 mm. Ultimately, Gex conducted a meta-analysis of 15 ENB published papers, including 1033 lung nodules with a median diameter of 25 mm. Their analysis calculated the average diagnostic yield to be 64.9%. Overall diagnostic accuracy was 73.9% (95% CI 68.0–79.2). Sensitivity to detect cancer was 71.1% (95% CI 64.6–76.8), with a negative predictive value of 52.1% (95% CI 43.5–60.6). Pneumothorax occurred in 3.1% of patients, requiring chest tube placement in 1.6% of the patients. One will note the negative predictive value was rather low, therefore a technique having a higher specificity to correctly identify a true negative patient would aid the intent to reduce patient morbidity while saving scarce healthcare dollars. [18] Furthermore, this older technology also reported a significantly higher average fiducial target registration error (AFTRE) of 5.1 mm. [19] As the clinical need for lung screening grows, this data reflects lung lesion size as an important factor in diagnosis. As one might expect, larger lesions are easier to target and may diminish the benefit of navigation. Clinicians interested in eliminating the radiation exposure of fluoroscopic navigation, increasing diagnostic yields above older ENB systems, and decreasing inaccuracies associated with respiratory motion that may contribute to pneumothorax must consider using improved systems with the technology that accounts for motion during both the inspiratory and expiratory phases of the respiration cycle.

**Table 1**

Diagnostic Yield of Peripheral Lung Lesions not Utilizing 4D Patient Motion

Study Author	Diagnostic Yield	Lesion Size	Number of Patients Evaluated	Method
Eberhardt <sup>13</sup>	59%	28 +/- 8 mm	118	ENB
Eberhardt <sup>13</sup>	69%	25 +/- 5 mm	118	EBUS
Nabavizadeh <sup>14</sup>	32%	22.7 mm (range 8 to 44 mm)	31 patients, 105 fiducials placed	ENB with daily CBCT
Makris <sup>15</sup>	62.5%	23.5 mm		
Becker <sup>16</sup>	69%	24 +/- 5.4 mm	29	ENB conventional breath hold
Schwarz <sup>17</sup>	69%	33.5 +/- 11 mm	13	ENB
Gildea <sup>18</sup>	73%	22.8 +/- 12.6 mm	60	ENB
Gex <sup>19</sup>	64.9%		1033 meta-analysis	

Technology alone doesn't account for diagnostic accuracy. There must be an established relationship between the pulmonologist and the pathologist with established protocols for reporting findings. This, along with having multidisciplinary treatment teams, is critical to the success of focused clinical management of patients. Certainly the diagnosis of a positive finding on a lung CT is frightening to the patient and their family. The continued management of that patient has been shown to succeed when a multispecialty team's goals and communications are well aligned with the unique needs of the patient and their family.[20]

Our institution, which is the largest hospital in the state and one of the nation's largest public hospitals, serves a diverse patient population in a region of the country with one of the highest prevalence of lung cancer. Based on high diagnostic yield, low procedure complication rates, and decreased need for fluoroscopic radiation exposure while using the 4D EMN technology, we were encouraged that the system will play a vital role in the localization and diagnosis of small peripheral nodules. As our lung cancer screening program grows, we expect to see smaller targets that will require a definitive diagnosis. 4D EMN is a valuable tool in helping us diagnose these small targets while contributing to the stability of the patient's health.

Our study shows that Veran Medical Technologies' SPiNDrive system has demonstrated the value of implementing a hybrid inspiration/expiratory CT protocol for 4D EMN procedures by providing sufficient accuracy to target nodules less than 2cm (4189mm<sup>2</sup>) in size. It is clear from the magnitude of motion between inspiration and expiration that tracking the patient's respiratory state is key to achieving high diagnostic yields and will also be important as pulmonologists explore therapeutic options.

Additional studies are needed to further examine the comparison of diagnostic yield across different size volumetrically measured nodules with and without bronchus signs to the nodule.

## References

1. Jemal A, Siegel R, Ward E, Hao Y, Xu J, Thun MJ. Cancer statistics, 2009, CA Cancer J Clin 2009; 59:225-45.
2. Moyer VA. U.S. Preventive Services Task Force. Screening for lung cancer: U.S. Preventive Services Task Force recommendation statement. Ann Intern Med. 2014.
3. Lung-RADS TM Version 1.0 Assessment Categories Release Date: April 18, 2014. <http://www.acr.org/~media/ACR/Documents/PDF/QualitySafety/Resources/LungRADS/AssessmentCategories.pdf>.
4. Gould MK, Fletcher J, Iannettoni MD, et al. Evaluation of patients with pulmonary nodules: when is it lung cancer? ACCP evidence-based clinical practice guidelines (2nd edition American College of Chest Physicians.). Chest. 132 ( suppl 3 ), 108S - 130S (2007).
5. Rivera MP, Mehta AC, Wahidi MM. Establishing the Diagnosis of Lung Cancer Diagnosis and Management of Lung Cancer, 3rd Ed: American College of Chest Physicians. Baaklini WA, Reinoso MA, Gorin AB, Sharafkaneh A, Manian P. Diagnostic yield of fiberoptic bronchoscopy in evaluating solitary pulmonary nodules. Chest. 117 (4), 1049 – 1054 (2000).
6. Seijo LM, de Torres JP, Lozano MD, et al. Diagnostic yield of electromagnetic navigation bronchoscopy is highly dependent on the presence of a bronchus sign on CT imaging: results from a prospective study. Chest. 138 ( 6 ), 1316 – 1321(2010).
7. Memoli JSW, Nietert PJ, Silvestri GA. Meta-analysis of Guided Bronchoscopy for the Evaluation of the Pulmonary Nodule. Chest. 142:2,385–393 (2012).
8. Chen A, Pastis N, Furukawa B, Silvestri G. Effect of respiratory motion on pulmonary nodule location during electromagnetic navigation bronchoscopy. Chest 2014; doi 10-1378/chest 14-1425.
9. Lee KA, Raval AA, Amir L. Cost-effectiveness of Endobronchial percutaneous biopsy compared with transthoracic biopsy for diagnosis of peripheral lung lesions. Future Medicine Lung Cancer Management. 135-148 (2014).
10. Evidence-Based Clinical Practice Guidelines. Chest. 143,143s-165s (2013). National Lung Screening Trial, 2010 Updates: National Cancer Institute website. Available at <http://www.cancer.gov/clinicaltrials/noteworthy-trials/nlst/updates>.
11. Bauer M, Joshiy S, Modinz K. Diffeomorphic density matching by optimal information transport. Cornell University Library. arXiv:1501.07635, June (2015).
12. Eberhardt R, Anantham D, Ernst A, Feller-Kopman D, Herth F. Multimodality Bronchoscopic Diagnosis of Peripheral Lung Lesions. Am J Respir Crit Care Med.176, 36-41(2007).
13. Nabavizadeh N, Zhand J, Elliott DA, Tanyi JA, et.al. Electromagnetic Navigational Bronchoscopy-guided Fiducial Markers for Lung Stereotactic Body Radiation Therapy. J Bronchol Intervent Pulmonol. 21, 123-130 (2014).
14. Makris D, Scherpereel A, Leroy S, Bouchindhomme B, Faivre JB, Remy J, Ramon P, et al. Electromagnetic navigation diagnostic bronchoscopy for small peripheral lung lesions. Eur Respir J 2007;29:1187-92
15. Becker HC, Herth F, Ernst A, Schwarz Y. Bronchoscopic biopsy of peripheral lung lesions under electromagnetic guidance: A pilot study. Journal of Bronchoscopy. 12, 9-13 (2005).
16. Schwarz Y, Greif, Becker HD, Ernst A, Mehta A. Real-time electromagnetic navigation bronchoscopy to peripheral lung lesions using overlaid CT images: the first human study. Chest.129, 988-994 (2006).
17. Gildea TR, Mazzone PJ, Karnak D, Meziane M, Mehta AC. Electromagnetic navigation diagnostic bronchoscopy: a prospective study. Am Respir Crit Care Med. 174, 982-989 (2006).
18. Gex G, Pralong JA, Combescure C, et. al. Diagnostic Yield and Safety of ta H, Ravenel J, Shaftman S, et.al. The Utility Of Nodule Volume In The Context Of Malignancy Prediction For Small Pulmonary Nodules. Chest. 145(3),464-472 (2014).
19. Raval AA, Amir L. Community Hospital Initial Experience Using Electromagnetic Navigation Bronchoscopy System Integrating Tidal Volume CT Mapping. Future Medicine-Lung Cancer in press 2016.
20. Gaga M, Powell CA, Schraufnagel DE, Schoenfeld N, Rabe K, et. al. on behalf of the ATS/ERS Task Force on the Role of the Pulmonologist in the Management of Lung Cancer. AnOfficialAmericanThoracic Society/European Respiratory Society Statement: The Role of the Pulmonologist in the Diagnosis and Management of Lung CancerAm J Respir Crit Care Med Vol 188, Iss. 4, pp 503–507, Aug 15, 2013.
21. Mehta H, Ravenel J, Shaftman S, Tanner N, Paoletti L, Taylor K, Tammemagi M, Gomez M, Nietert P, Gould M, Silvestri G. The Utility Of Nodule Volume In The Context Of Malignancy Prediction For Small Pulmonary Nodules. CHEST 2013
22. Seijo L, Torres J, Lozano M, Bastarrika G, Alcaide A, Lucunza M, Zulueta J. Diagnostic Yield of Electromagnetic Navigation Bronchoscopy Is Highly Dependent on the Presence of a Bronchus Sign on CT Imaging. CHEST, 2010; 138(6):1316-1321.

**Author Information**

**Eric L. Flenaugh, MD, FCCP, Associate Professor, Chief of Pulmonary & Critical Care Medicine, Morehouse School of Medicine**

Director, Advanced Diagnostic and Interventional Pulmonary Service Grady Health System  
Atlanta, GA

**Kareem Hosny Mohammed, MD, PhD, Post-Doctoral Fellow**

Emory Clinical Cardiovascular Research Institute, Rollins School of Public Health, Emory University  
Atlanta, GA