

Prostate Cancer Presenting As A Chest Wall Tumour

C Roxburgh, S Swami

Citation

C Roxburgh, S Swami. *Prostate Cancer Presenting As A Chest Wall Tumour*. The Internet Journal of Urology. 2006 Volume 4 Number 2.

Abstract

Prostate cancer commonly metastasises to bone and lymph nodes. We report a case of metastatic prostate cancer presenting clinically as a chest wall tumour. Raised serum prostate specific antigen and positive fine needle aspiration cytology established the diagnosis.

He was treated with standard hormonal therapy and is doing well 24 months post presentation with substantial regression of the chest wall mass.

INTRODUCTION

Prostate adenocarcinoma is the second commonest male cancer in the UK and the commonest in the USA. In descending order of frequency, usual sites for metastatic disease include bone, lymph nodes, lung, bladder, liver and adrenal glands¹. There are reports in the literature of metastases to almost every organ in the body. Cutaneous or soft tissue metastases from primary prostate tumours are well documented^{2,3}.

Primary and secondary neoplasms of the chest wall are rare, accounting for 1% of all neoplasia⁴. There are varying aetiologies for these tumours, benign accounting for around 50%. Malignant primaries include Ewings sarcoma, osteosarcoma and chondrosarcoma. Metastatic chest wall tumours account for 16% of all chest wall tumours⁵.

An unusual presentation of prostate cancer presenting as a tumour of the chest wall is described below.

CASE REPORT

A 65yr old male with a past history of anterior resection for rectal adenocarcinoma presented with a soft tissue lump over his left pectoral area. The lump had been present for 4 weeks. Examination revealed an 8cm x 5cm diffuse, non mobile and non-tender mass.

Subsequent work-up included MRI scan, CT scan and a bone scan. MRI revealed a large mass in the chest wall most likely to have arisen from a rib or the pleura, displacing the adjacent lung and invading the subcutaneous fat on the posterior chest wall (Figures 1&2).

Figure 1

Figures 1 and 2: MRI Scan of the thorax: Large mass arising from the left posterolateral chest wall displacing adjacent lung and invading subcutaneous fat

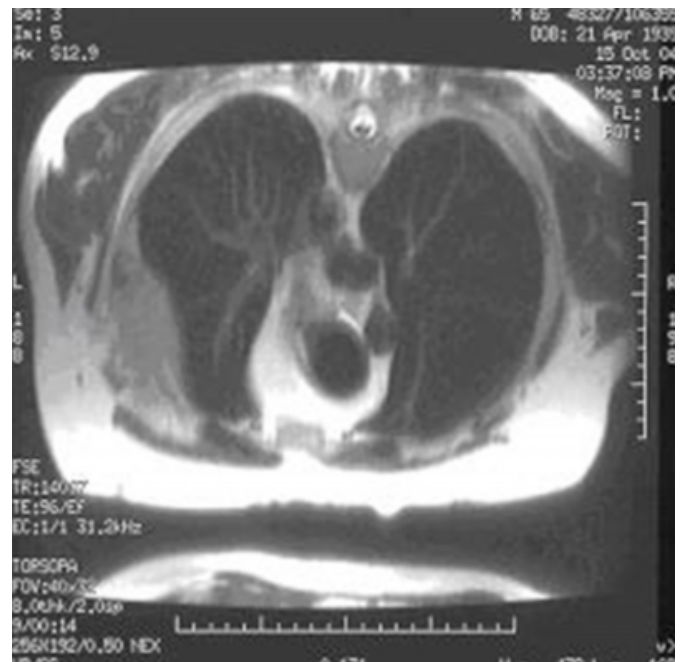
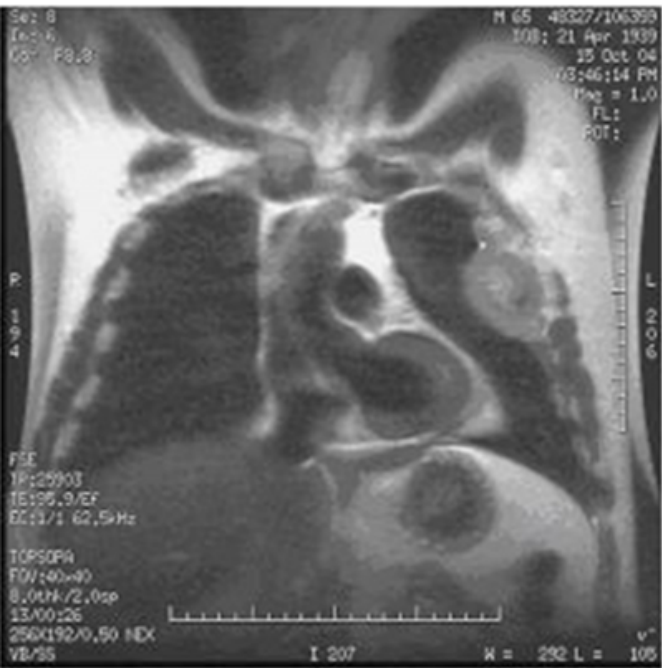
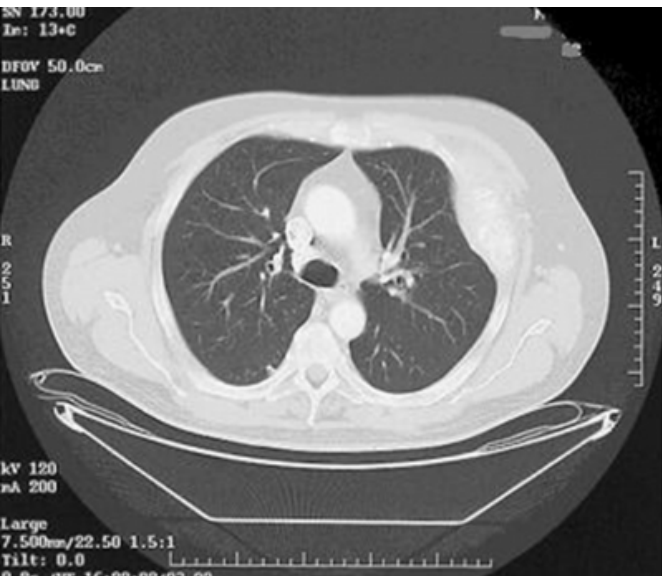Figure 2



CT and biopsy was performed. CT showed a sclerotic mass involving the ribs and chest wall consistent with metastatic prostate disease or chest wall sarcoma (Figure 3).

Figure 3

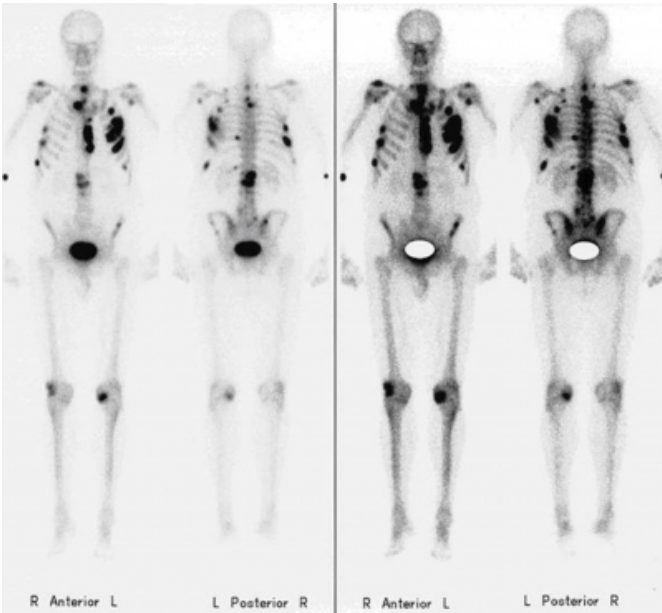
Figure 3: CT Chest. Sclerotic mass involving the anterior 4 and 5 ribs of left thoracic wall



A bone scan showed multiple bony metastases throughout the ribs, the thoracic and lumbar spine.

Figure 4

Figure 4: Radionucleotide bone scan: Multiple bony metastases bilaterally throughout the ribs, the sternum, lumbar spine and pelvis. The most active lesion is seen in the left 4 rib anteriorly.



Serum PSA was grossly elevated at 1746. Fine needle aspiration cytology revealed metastatic prostate cancer confirmed with immunocytochemistry (PSA positive, CK7 negative, CK20 negative, AE1/AE3 positive).

There was no history of lower urinary tract symptoms or bone pain. Rectal examination revealed a small hard prostate. Routine biochemistry was unremarkable aside from an elevated alkaline phosphatase of 230. There was no family history of prostate cancer.

The patient was commenced on goserelin three-monthly injections as well as cyproterone acetate to guard against initial tumour flare. He is under ongoing follow-up 24 months following initial presentation. The chest wall lesion is no longer visible and has shown a marked reduction in size with hormonal treatment.

DISCUSSION

Prostatic adenocarcinoma metastatic to the chest wall has been reported previously but only in patients with known disease⁶. Chest wall metastases from all tumours are more commonly due to blood-borne spread than lymphatic or direct spread. Primary tumours of breast and lung can invade the chest wall directly.

To our knowledge, this is the first report of undiagnosed prostate cancer presenting as a large invasive chest wall

tumour.

Estimation of serum PSA is not routinely undertaken in pre-operative assessment of chest wall tumours. The sclerotic bony lesion in this case prompted the assessment of serum PSA. Radiological assessment includes X-ray, CT or MRI. A bone scan can reveal other sites of bony metastatic disease. In male patients with cutaneous or soft tissue tumours of unknown origin, the PSA is a useful marker to rule out one rare but potential cause.

A significant proportion of patients with metastatic prostate cancer achieve a remission with hormonal treatment. The median survival after such a remission is 12-24 months^{7 8}. Subsequent relapse with hormonal escape is the rule which accounts for the poor results in these patients.

References

1. Saitoh H, Hida M, Shimbo T. Metastatic patterns of

Prostate Cancer. Correlation between sites and number of organs involved. *Cancer* 1984; 54:p3078-3084

2. Bellman B, Grossman M, Spitz J. Prostate Cancer metastatic to skin. *The Journal of European Academy of Dermatology and Veneurology*. 1995;Vol 4(1):p75-76

3. Duran EP, Pardela A. Cutaneous Metastases from Prostate Cancer. *Journal of Surgical Oncology*. 1996;Vol62(2):p144-147

4. *The Oxford Textbook of Surgery*, Morris Peter J, Wood William C. Chapter 41.4 Primary chest wall neoplasms

5. Friemann J, Roessner A, Muller K-M. Primary and secondary tumors of the chest wall in the view of pathology. *Langenbecks Archiv fur Chirurgie*. 1987;Vol. 372:p 757-767 (ABSTRACT)

6. Kaneko H, Nakauchi K, Mashima Y, Kawakami M, Kumakawa T. Monitoring tumour response to therapy by means of ³¹P magnetic resonance spectroscopy. A case of advanced prostate cancer with metastatic chest wall tumour. *The Japanese Journal of Urology*. 1994;Vol 85(5):p819-822

7. Carroll PR, Kantoff P, Balk W. Overview consensus statement. Newer approaches to androgen deprivation therapy in prostate cancer. *Urology* 2002 (Suppl) page 1

8. W. Chodak, T. Keane L. Klotz, Critical evaluation of hormonal therapy for carcinoma of the prostate, *Urology* 60 (2002), p. 201

Author Information

C. S. D. Roxburgh, MRCS

Department of Urology, Aberdeen Royal Infirmary

S. K. Swami, FRCS

Department of Urology, Aberdeen Royal Infirmary