

Open Fracture of the Tibia & Fibula Caused by an Airbag: A Case Report & Review of the Literature Regarding Lower Extremity Injuries Secondary to Airbags

A Syal, B Pilkey

Citation

A Syal, B Pilkey. *Open Fracture of the Tibia & Fibula Caused by an Airbag: A Case Report & Review of the Literature Regarding Lower Extremity Injuries Secondary to Airbags*. The Internet Journal of Orthopedic Surgery. 2005 Volume 3 Number 1.

Abstract

This is a case report of an open fracture of the tibia and fibula caused by the deployment of an airbag in a motor vehicle collision, unreported in the literature to date. A review of the literature regarding tibia and fibula fractures secondary to airbags was performed.

It has been demonstrated in the literature that airbags can produce significant upper and lower extremity injuries when no other restraining devices are employed.

INTRODUCTION AND REVIEW

Motor vehicle collisions (MVC) are a significant cause of morbidity and mortality. Seat belt use has been identified as a significant factor in declining rates of MVC related morbidity and mortality since their introduction in the 1960s^{1,2}. Frontal airbags, mandated since the early 1990s, were introduced to help reduce the risk of injury secondary to frontal collisions. The effectiveness of airbags as lifesaving devices and a means of preventing or minimizing injury to the head, neck, and torso have been documented^{3,4,5}. However, the possible effect on the lower extremities has received less attention. As a group, restraining devices decrease the incidence of upper and lower extremity trauma sustained by patients injured in motor vehicle collisions^{6,7,8}.

Air bags, however, are associated with an increased incidence of upper and lower extremity injuries when compared with seat belts alone or when no restraining devices are used. In fact combined restraint use was associated with an increased fracture risk for tibia and fibula fractures¹. Studies have shown that injuries to the lower extremity secondary to motor vehicle crashes are frequent and disabling. Burgess et al. studied the lower extremity injuries of 10 drivers of airbag equipped cars involved in MVCs and found that air bags do not prevent injuries of the lower extremity⁹. McGovern et al. reported an association

between airbag restraint alone and an increased incidence of upper and lower extremity fractures¹⁰. There is support in the literature that airbags can cause significant injuries to both the upper and lower extremities. This case report demonstrates an unusual presentation of a lower extremity injury due to airbag deployment in an MVC.

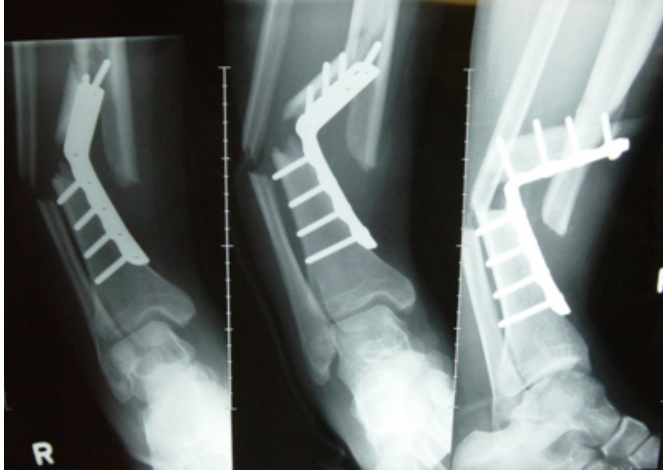CASE REPORT

A 25 year old man, as a belted front seat passenger, was involved in a MVC resulting in an open right tibia and fibula fracture with disruption of a previous plate. Two months earlier he had fallen from a height causing isolated closed tibia and fibula fractures requiring open reduction and internal fixation with a plate and screws at a nearby peripheral hospital. Subsequently, prior to the collision the patient was resting his leg on the front dashboard to keep his leg elevated. The vehicle was traveling approximately 110 km/h when it collided with a deer causing the airbags to deploy in both the driver and passenger compartments. The passenger-sided airbag deployed in an upward direction forcing his right leg into the windshield causing an open fracture of the long bones as disruption of the plate construct.

He presented to a regional hospital where he was initially assessed and imaging studies were taken (Fig. 1).

Figure 1: AP, Mortise, & Lateral views of the right tibia and fibula demonstrating significant malalignment as well as bent plate preventing further reduction.

Figure 1



On presentation he presented with an open 2 cm wound over the distal right fibula with exposed bone. The limb was in 90° of varus deformity as well as posterior angulation. The right foot had non-palpable dorsalis pedis and posterior tibialis pulses, was pale, blue, and cool to touch. The emergency physician performed a closed reduction to approximately 50° varus/posterior angulation and pulses were palpable with a warm, pink foot post-reduction. He was splinted and then transferred to Health Sciences Centre (HSC) in Winnipeg for definitive fracture management. The patient was assessed in the HSC emergency department; repeat X-rays were taken, no further closed reduction was attempted due to the bent plate blocking any planned maneuvers for realignment. He was admitted to hospital for definitive fracture management.

The operation involved irrigation and debridement of the open wound, incision through his previous anterior scar for removal of the plate and screws, irrigation of the tibia fracture, closed reduction of the tibia segmental fracture followed by intramedullary nail insertion with proximal and distal locking screws. There were no complications from the operative procedure and the patient was transferred to a peripheral hospital from where he was discharged home on the third postoperative week. He has since been seen in follow up at the HSC orthopedic trauma outpatient clinics with demonstration of uneventful wound healing as well as preservation of good alignment and early callus formation on repeat radiographs of the IM nail (Figs. 2 & 3).

Figure 2

Figure 2A: Post-operative lateral view demonstrating new bone healing and good alignment.

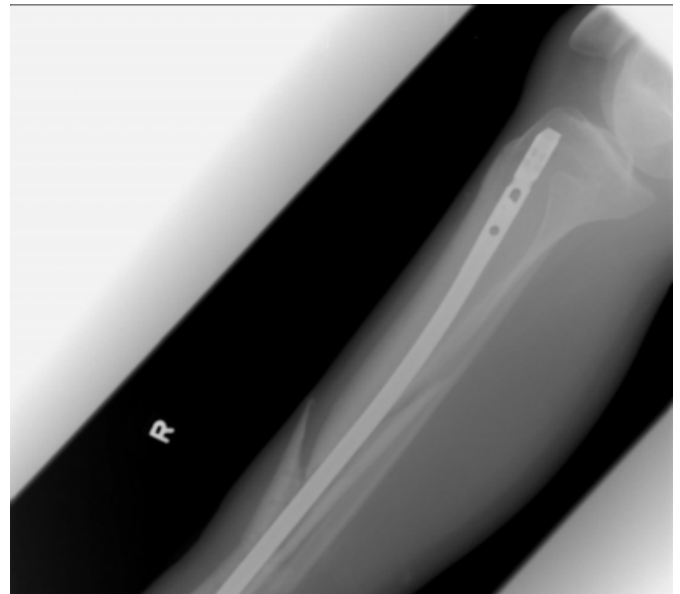


Figure 3

Figure 2B: Post-operative AP view demonstrating new bone healing and good alignment.

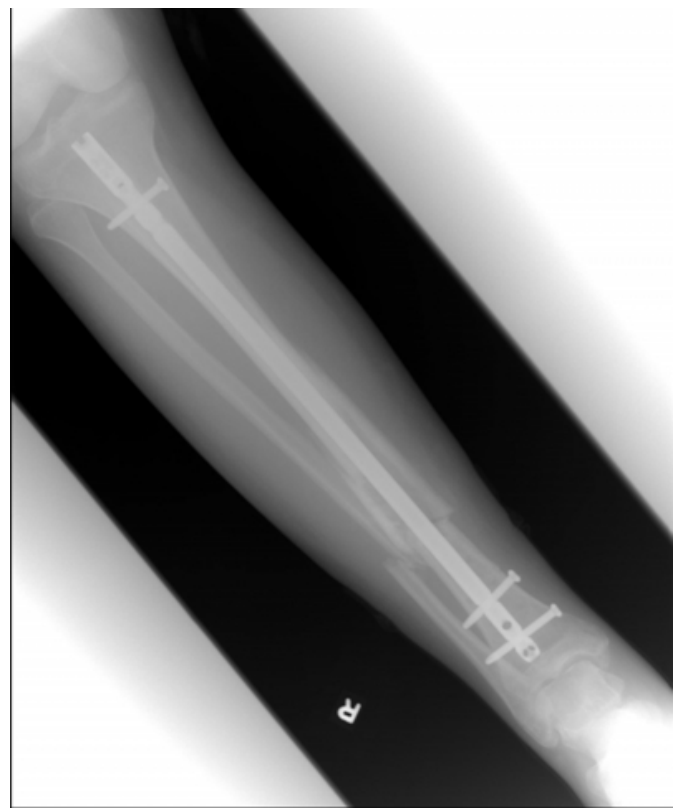
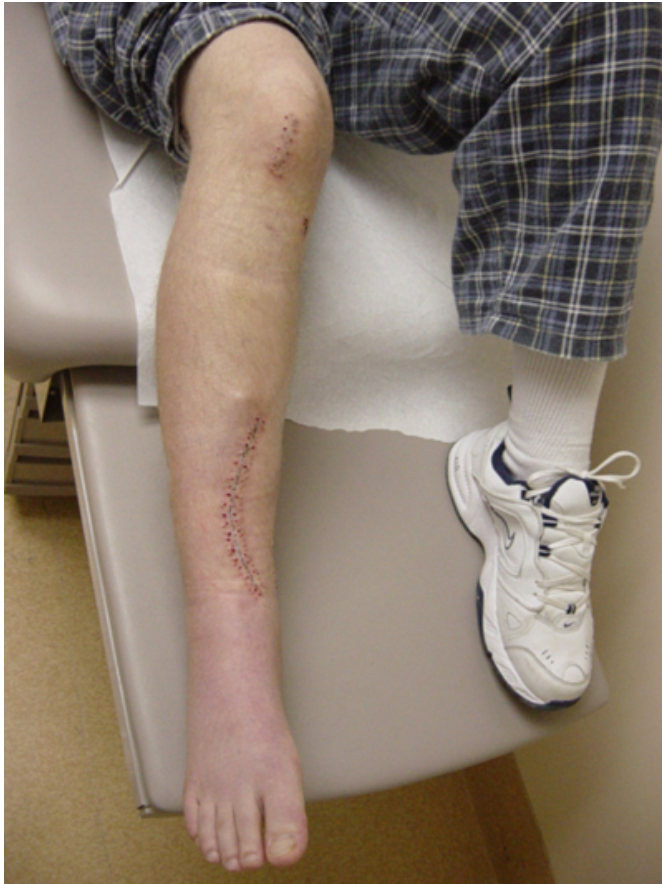
Figure 4

Figure 3: Follow up of patient's leg demonstrating excellent alignment and wound healing.



DISCUSSION

It is a rather casual occurrence for front seat passengers to place their lower limbs on the dashboard. The danger in doing so has been demonstrated in this case report wherein the force applied by the airbag deployment was great enough to bend a metal plate with screws fixing it to bone, and also causing open fracture of the distal tibia and fibula. It has

been demonstrated in the literature that airbags can produce significant upper and lower extremity injuries when no other restraining devices are employed. Although there is evidence to show that there is a protective effect of both airbags and restraining devices when used in conjunction with one another. Public awareness of the potential dangers of airbags in causing upper and lower extremity injuries should be addressed to prevent increasing presentations of these injuries in MVCs.

References

1. Estrada LS, Alonso JE, McGwin G, et al. Restraint Use and Lower Extremity Fractures in Frontal motor Vehicle Collisions. *J Trauma* 2004;57:323-328.
2. Li G, Shahpar C, Grabowski JG, et al. Secular trends of motor vehicle mortality in the United States, 1910-1994. *Accident Anal Prev* 2001;33:424-432.
3. Zador PL, Ciccone MA. Automobile driver fatalities in frontal impacts: air bags compared with manual belts. *Am J Public Health*.1993;83:661-666.
4. Murphy JR RX, Birmingham XL, Okunski WJ, et al. The influence of airbag and restraining devices on the patterns of facial trauma in motor vehicle collision. *Plast Reconstr Surg*. 2000;105:516-520.
5. Pintar FA, Yoganandan N, Gennarelli TA. Airbag effectiveness on brain trauma in frontal crashes. *Proc Assoc Adv Automot Med Conf*. 2000;44:149-169.
6. Crandall CS, Olson LM, Sklar DP. Mortality reduction with air bag and seat belt use in head-on passenger car collisions. *Am J Epidemiol*. 2001;153:219-224.
7. Evans L. The effectiveness of safety belts in preventing fatalities. *Accid Anal Prev*. 1986;18:229-241.
8. Braver ER, Ferguson SA, Greene MA, et al. Reductions in deaths in frontal crashes among right front passengers in vehicles equipped with passenger airbags. *JAMA*. 1997;278:1437-1439.
9. Burgess AR, Dischinger PC, O'Quinn TD, et al. Lower extremity injuries in drivers of airbag equipped automobiles: clinical and crash reconstruction correlations. *J Trauma*. 1995;38:509.
10. McGovern MK, Murphy RX, Okunski WJ, et al. The influence of air bags and restraining devices on extremity injuries in motor vehicle collisions. *Ann Plast Surg*. 2000 May;44(5):481-485.

Author Information

Abeer Syal, M.D.

Orthopaedic Surgery Resident, Department of Surgery, Section of Orthopaedic Surgery, Health Sciences Centre, University of Manitoba

Brad Pilkey, MD, FRCSC

Director of Orthopaedic Trauma, Department of Surgery, Section of Orthopaedic Surgery, Health Sciences Centre, University of Manitoba