

# Benign Recurrent Intrahepatic Cholestasis (Bric)

S Arulprakash, P Rajan Babu, T Pugazhendhi, S Jeevankumar

## Citation

S Arulprakash, P Rajan Babu, T Pugazhendhi, S Jeevankumar. *Benign Recurrent Intrahepatic Cholestasis (Bric)*. The Internet Journal of Pediatrics and Neonatology. 2008 Volume 9 Number 2.

## Abstract

Benign recurrent intrahepatic cholestasis (BRIC) a rare form of hereditary cholestasis syndrome characterized by repeated self limited episodes of pruritus and jaundice. It recurs but occasionally leads to progressive liver disease. Treatment is symptomatic. We report a case of BRIC in a child.

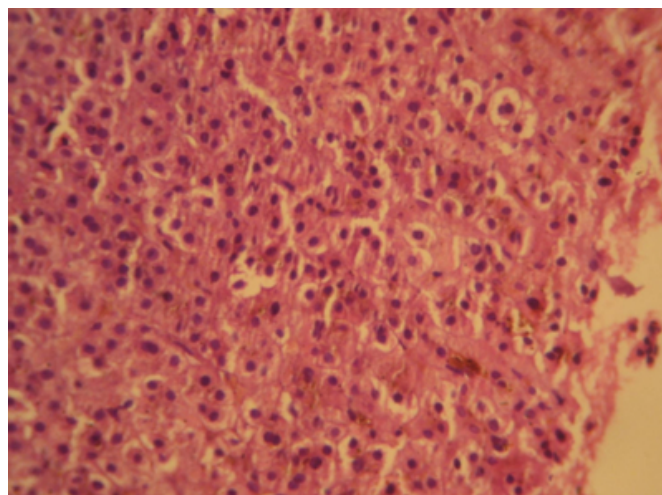
## CASE REPORT

A 11-year-old boy who is the first child of his healthy non consanguineous parents, presented to us with complaints of pruritus, jaundice, dark coloured urine and intermittent pale stools. There was no history of febrile illness / ingestion of drugs or family history of liver disease. He had previous similar episode of jaundice one year back it lasted for one month for which he received symptomatic treatment . Liver function tests done during that previous episode showed conjugated hyperbilirubinemia and elevated alkaline phosphatase (900 IU). The child was asymptomatic in between the episodes. He was healthy with normal growth and development. On examination, the child had icterus, obvious itching, without pallor, pedal edema or signs of vitamin deficiencies. There were no signs of liver failure. Liver was just palpable in right hypochondrium with a span of 11 cm. Spleen was not palpable. Rest of the systemic examination was non contributory. Investigations revealed Hb of 12.1 g/dl with normal total and differential count. Total bilirubin was 19.53 mg% with a direct component of 14.06mg%. Alkaline phosphatase was elevated with a value of 769 IU. Liver enzymes including ALT, AST and gamma glutamyl transpeptidase (GGT: 8U/L) were within normal limits. Serum total proteins, albumin globulin ratio were also normal. Prothrombin time was prolonged but responded to vitamin K. Ultrasonography of abdomen showed normal echotexture of liver. MRCP (Magnetic Resonance Cholangio Pancreatogram) was normal. Viral markers for Hepatitis A, B and C were negative and serum ceruloplasmin (20 mg/dL) was within normal limits. In view of clinical and biochemical findings, a possibility of recurrent cholestasis was considered and a liver biopsy was performed. The biopsy showed preserved lobular architecture with marked

cholestasis within hepatocytes with mild inflammatory cell infiltrates (Fig.1).

## Figure 1

Figure 1: Liver biopsy showing hepatic lobules with intrahepatic cholestasis and inflammatory cell infiltrates



Diagnosis of BRIC was made on the basis of clinical and laboratory parameters. He was treated symptomatically and he improved within 4 weeks with normalization of liver function tests. The child was asymptomatic on 1 year follow up.

## DISCUSSION

BRIC was described by Summerskill and Walshe in 1959 as recurrent episodes of jaundice and pruritus. (1) It is a less severe form of hereditary cholestasis syndromes. BRIC- 1 and 2 is a benign, recurrent form of FIC- 1 and 2 (Familial intrahepatic cholestasis). There are three forms of BRIC all with similar phenotype. BRIC - 1 and BRIC-2 are transmitted as autosomal recessive diseases. BRIC-1/PFIC-1

(PFIC -progressive familial intrahepatic cholestasis) due to mutations in the aminophospholipid flippase ATP8B1 located on chromosome 18q21 (3). BRIC-2/PFIC-2 due to mutations in the bile salt export pump BSEP/ABCB11 located on chromosome 2q24 (4). A third form, not linked to either 18q21 or 2q24 exists and is transmitted as an autosomal dominant disease (5). BRIC manifests early in life, cholestasis is preceded by intense pruritus, malaise, lassitude, occasionally by an erythematous rash. Duration of cholestasis last for 2 – 24 weeks (1), but longer bouts and progression to PFIC-1 have been described. The intensity and the length of intervening periods, vary unpredictably before resolving spontaneously (2). Between attacks the patients are healthy. Associated symptoms include anorexia, weight loss, vomiting, fatigue, dark urine and pale stools. Physical examination is usually unremarkable. The hallmark of the disease is cholestasis – elevated bilirubin, bile acids and alkaline phosphatase – with normal G-GT. Liver function tests are normal between bouts (6). Histologically there is canalicular cholestasis, some degree of portal hepatitis and fibrosis. Diagnosis was based on the following diagnostic criteria for BRIC (a) At least two episodes of jaundice separated by a symptom-free interval lasting several months to years. (b) Laboratory values consistent with intrahepatic cholestasis. (c) Severe pruritis secondary to cholestasis. (d) Liver histology demonstrating centrilobular cholestasis. (e) Normal intrahepatic and extrahepatic bile ducts confirmed by cholangiography. (f) Absence of factors known to be associated with cholestasis, (i.e., drugs, pregnancy) (7). BRIC -1 are sometimes associated with extrahepatic manifestations such as diarrhea, bile acid malabsorption, pancreatitis and nephrolithiasis which can be explained by wide expression of FIC1 in these tissues. (8) BRIC- 2 seems to be associated with risk of development of gall stones. BRIC is not always as benign sometimes it may progress to PFIC and later cirrhosis. (9) A return in appetite is often the first sign of resolution followed by pruritus. Jaundice lessens gradually and then resolves. (7)

No specific treatment that could either prevent or limit the duration of attacks is known. The key to treatment is therefore relief of severe pruritus and other symptoms until

attacks resolve spontaneously. Intractable pruritus responds poorly to anti-histaminics, cholestyramine, UDCA (Urosodeoxycholic acid) (10) or S-adenosyl methionine and rifampicin. (11) Plasmapheresis / MARS (Molecular Adsorbents Recirculation System) should be considered in refractory cases. Biliary diversion is not very convincing. Liver transplantation can be indicated for intractable pruritus in particular when BRIC progresses to PFIC.

## CORRESPONDENCE TO

Dr. Arulprakash.SPlot. No: 119 A, First main road, Second cross street, Lakshmi nagar extension, Porur, Chennai: 600116. Tamilnadu India Ph: 09962033234 E-mail:drarulaash@yahoo.co.in

## References

1. Summerskill WHJ, Walsh JM. Benign recurrent intrahepatic obstructive jaundice. *Lancet*, 1959; 1: 686-90.
2. Al Drees K, al Zaben A, al Amin A, Abdulla A. Benign recurrent intrahepatic cholestasis in a Saudi child. *Ann of Trop Paediatr*, 1999; 19: 215-7.
3. Bull LN, van Eijk MJ, Pawlikowska L et al.. A gene encoding a P-type ATPase mutated in two forms of hereditary cholestasis. *Nature Genet*, 1998; 18: 219-24.
4. Van Mil SWC, Van Der Woerd WL, Van der Brugge G et. al. Benign recurrent intrahepatic cholestasis type 2 is caused by mutations in ABCB11. *Gastroenterology*, 2004; 127: 379-84.
5. Floreani A, Molaro M, Mottes M et al. Autosomal dominant benign recurrent intrahepatic cholestasis (BRIC) unlinked to 18q21 and 2q24. *Am J Med Genet*, 2000; 95: 450-3.
6. Summerfield JA, Kirk AP, Chitrakroh A, Billing BH. A distinctive pattern of serum bile acid and bilirubin concentrations in benign recurrent intrahepatic cholestasis. *Hepatology*, 1981; 28: 139-42.
7. Tygstrup N, Jensen B: Intermittent intrahepatic cholestasis of unknown etiology in five young males from the Faroe Islands. *Acta Medica Scandinavica*, 1969; 185:523-530.
8. Gernot Zollner, Micheal Trauner .Mechanism of cholestasis. *Clin liver Dis*, 2008; 12:1-26
9. Van Ooteghem NAM, Klomp LWJ et al.. Benign recurrent intrahepatic cholestasis progressing to progressive familial intrahepatic cholestasis: low GGT cholestasis is a clinical continuum. *J Hepatol*, 2002; 36: 439-43.
10. Crosignani A, Podda M, Bertolini E et al.. Failure of ursodeoxycholic acid to prevent a cholestatic episode in a patient with benign recurrent intrahepatic cholestasis: a study of bile acid metabolism. *Hepatology*, 1991; 13: 1076-83.
11. Balsells F, Wyllie R, Steffen R, Kay M. Benign recurrent intrahepatic cholestasis: improvement of pruritus and shortening of symptomatic phase with rifampicin therapy: a case report. *Clin Pediatr (Phila)* 1997; 36: 483-485.

**Author Information**

**S. Arulprakash, M.D (Ped), DNB (Ped)**

Resident, Medical Gastroenterology, Department of Digestive Health and Diseases, Government peripheral hospital, Kilpauk Medical College Hospital

**P.I. Rajan Babu, M.D.**

Resident, Medical Gastroenterology, Department of Digestive Health and Diseases, Government peripheral hospital, Kilpauk Medical College Hospital

**T. Pugazhendhi, M.D, D.M (Gastro)**

Professor, Medical Gastroenterology, Department of Digestive Health and Diseases, Government peripheral hospital, Kilpauk Medical College Hospital

**S. Jeevankumar, M.D, D.M (Gastro)**

Professor, Medical Gastroenterology, Department of Digestive Health and Diseases, Government peripheral hospital, Kilpauk Medical College Hospital