

Mild Postnatal Hydronephrosis Is Not Associated With Increased Vesicoureteral Reflux

S Mathew, E Abdelsalam, J Saslow, B Amendolia, T Nakhla, N Kemble, N Razi, G Stahl, Z Aghai

Citation

S Mathew, E Abdelsalam, J Saslow, B Amendolia, T Nakhla, N Kemble, N Razi, G Stahl, Z Aghai. *Mild Postnatal Hydronephrosis Is Not Associated With Increased Vesicoureteral Reflux*. The Internet Journal of Pediatrics and Neonatology. 2008 Volume 11 Number 1.

Abstract

Background: Antenatal hydronephrosis is known to be associated with vesicoureteral reflux (VUR). However, the incidence of VUR in postnatally diagnosed hydronephrosis is unknown. Hypothesis: The prevalence of VUR is increased in infants diagnosed with hydronephrosis on postnatal ultrasonography. Methods: Infants admitted to our NICU between January 1998 and September 2007 and diagnosed with hydronephrosis on postnatal ultrasonography were included. Results: One hundred thirty six infants were diagnosed with hydronephrosis by postnatal ultrasound and qualified for the study. Ninety two infants (67.7%) had grade I hydronephrosis, 34 infants grade II hydronephrosis (25%), 9 grade III hydronephrosis (6.6%) and one infant (0.7%) had grade IV hydronephrosis. Voiding cystourethrograms (VCUG) were performed on 90 infants (66.2%). Only 2 infants (2.2%) had VUR. Both of the infants who had VUR also had other associated major congenital anomalies. Conclusion: Mild postnatal hydronephrosis in our study population was not associated with an increased incidence of VUR.

Abbreviations:

APPD; Anteroposterior Pelvic Diameter (APPD)

BW; Birth Weight

GA; Gestational Age

NICU; Neonatal Intensive Care Unit

SFU; Society of Fetal Urology

US; Ultrasonography

VCUG; Voiding Cystourethrogram

VUR; Vesicoureteral Reflux

INTRODUCTION

Hydronephrosis diagnosed on prenatal ultrasonography is known to be associated with vesicoureteral reflux (VUR) (1). The incidence of VUR in antenatally diagnosed hydronephrosis ranges between 7- 38 % (1-7). VUR in infants and children can lead to recurrent urinary tract infection, renal scarring and end stage renal disease (8-10). Early diagnosis is essential in preventing complications associated with VUR. The postnatal management of antenatally detected hydronephrosis is controversial. Based on their studies, several investigators recommend that voiding cystourethrograms (VCUG) should be routinely performed in all cases of prenatally diagnosed

hydronephrosis (2,11,12).

The kidneys are routinely imaged during abdominal ultrasonography in infants even when it is performed for a disease unrelated to the genitourinary tract. In our institution, hydronephrosis is graded as per Society of Fetal Urology (SFU) grading system. Based on this classification, a large number of infants were diagnosed with grade I-II hydronephrosis. Although VCUG is routinely performed on infants diagnosed with hydronephrosis on prenatal ultrasound, its utility has been questioned (5,13). The value of VCUG in postnally diagnosed hydronephrosis is also uncertain. Acton et al reported that mild postnatal hydronephrosis is a poor predictor of VUR and may be a normal variant during the neonatal period (14). Furthermore, VCUG is an invasive and potentially hazardous procedure. The studies reporting correlations between antenatal hydronephrosis and VUR used anteroposterior pelvic diameter (APPD) to grade hydronephrosis (1-7). The literature to support correlation between postnally diagnosed mild hydronephrosis by SFU classification and VUR is sparse. Our objective was to determine the incidence of VUR in infants diagnosed with hydronephrosis on postnatal

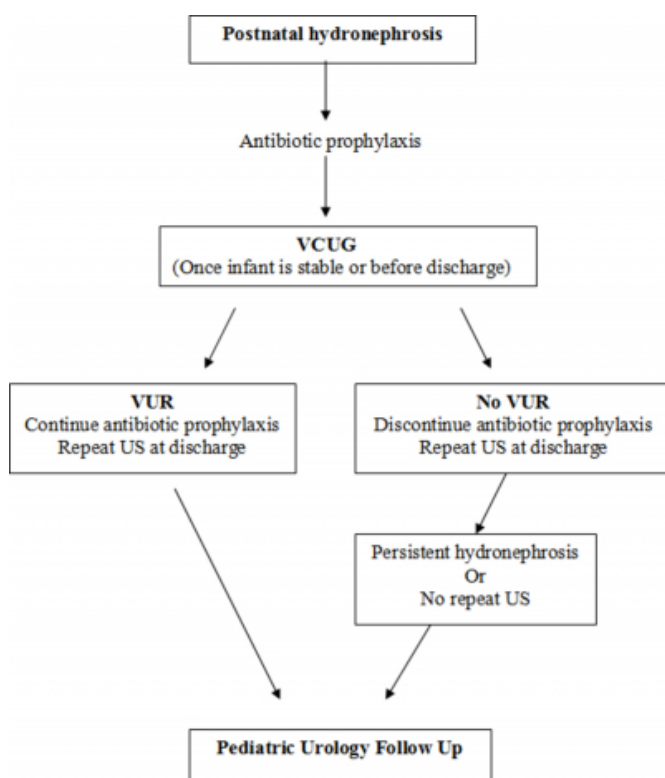
ultrasound.

MATERIALS AND METHODS

This is a single center, retrospective study in infants born between January 1998 and September 2007 admitted to the 35 bed, level III NICU at Cooper University Hospital, Camden, New Jersey and diagnosed with hydronephrosis on postnatal abdominal ultrasonography. The algorithm for the management of postnatally diagnosed hydronephrosis in our institution is described in figure 1.

Figure 1

Figure1: The algorithm for the management of postnatally diagnosed hydronephrosis at our institution.



VCUG; Voiding Cystourethrogram, VUR; Vesicoureteral Reflux, US; Ultrasonography

The Institutional Review Committee at Cooper University Hospital approved this study. The infants were identified from a neonatal database (Neonatal Information System III, NIS-Medical Data Systems, Wayne, PA). The following data were collected on each infant: date of birth, gestational age, birth weight, sex, race, results of prenatal ultrasound, indication and results of post natal ultrasound and results of VCUG.

Hydronephrosis was defined using the Society of Fetal Urology grading system (15).

- Grade 0 No splitting of the central renal echo complex
- Grade I Slight splitting of the central renal echo complex
- Grade II Dilated renal pelvis and some fluid in calyces
- Grade III Pelvis dilated beyond sinus, calyces uniformly dilated
- Grade IV Pelvis and calyces dilated, parenchyma thin
- Mild hydronephrosis (Grade I or II)
- Moderate hydronephrosis (Grade III)
- Severe hydronephrosis (Grade IV)

The international grading system was used to grade the VUR (16).

- Grade I: reflux into a nondilated ureter.
- Grade II : reflux into upper collecting system without dilation.
- Grade III : reflux into dilated ureter and/or blunting of calyceal fornices.
- Grade IV : reflux into grossly dilated ureter.
- Grade V : massive reflux with significant ureteral dilatation and tortuosity and loss of papillary impression

Infants with genitourinary abnormality known to be associated with VUR were excluded. Statistics were performed using Sigma Stat 3.1 for Windows statistical package (Systat Software, Inc. Point Richmond CA).

RESULTS

A total of 4,226 infants were admitted to our NICU during the study period. Hydronephrosis was diagnosed in 137 infants by postnatal abdominal ultrasonography (US). One infant was excluded from the study due to associated multicystic dysplastic kidney. The demographics and clinical characteristics of the infants with hydronephrosis are described in table 1.

Figure 2

Table 1: The demographics and baseline clinical characteristics of the study population

	n= 136
Birth weight (Grams) (Median, Range)	1787 (464-4640)
Gestational age (Weeks) (Median, Range)	33 (24-41)
Sex, Male (%)	90 (66.2)
Race, White (%)	60 (44.1)

The common indications for performing abdominal US were hydronephrosis on prenatal US, cholestasis and mild dysmorphism (Table 2).

Figure 3

Table 2. Indications of abdominal ultrasonography in infants diagnosed with hydronephrosis (n=136)

	n (%)
Hydronephrosis on prenatal US	33 (24.2)
Mild dysmorphism*	31 (22.7)
Cholestasis	26 (19.1)
Major congenital anomaly	14 (10.3)
UTI	13 (9.6)
Renal failure	11 (8.1)
Others#	8 (5.9)

*Single umbilical artery, hypospadias, preauricular tag, facial dysmorphism
#R/O abdominal abscess, r/o fungal ball

At our institution all infants with UTI are subjected to renal US and VCUG. The median age of performing the abdominal ultrasound was 9 days (range 1-152 days).

More than ninety two percent of infants (126/136) had mild hydronephrosis (grade I or II using the SFU classification) (Table 3).

Figure 4

Table 3. The grades of hydronephrosis and the incidence of VUR in the study population (n=136)

SFU Grades	Hydronephrosis (%)	VCUG Performed (%)	VUR (%)
Grade I	92 (67.7)	57 (62.0)	1* (1.7)
Grade II	34 (25.0)	26 (76.5)	1* (3.8)
Grade III	9 (6.6)	6 (67)	0 (0)
Grade IV	1 (0.7)	1 (100)	0 (0)

*Also had multiple other major congenital anomalies

*Also had duodenal atresia

VCUG was performed on 90 infants (66.2%). The median

age of infants at the time of VCUG was 28 days (range 3-121). Only two infants (2.2%) had VUR (one infant had grade I VUR and the other infant had grade III VUR). Both infants who had VUR also had other associated major congenital anomalies. One infant had multiple congenital anomalies (congenital heart disease, hydrocephalus, two vessels cord) and the other had duodenal atresia. Fourteen infants in our study population had major, but non-urological congenital anomalies (gastroschisis 4, cleft palate 4, congenital heart defects 2, omphalocele 1, anal atresia 1, duodenal atresia 1 and Dandy Walker Syndrome 1). The incidence of VUR in infants with major non-urological congenital anomalies and postnatal hydronephrosis was 14.3% (2 out of 14 infants). None of the infants with postnatal hydronephrosis without associated major congenital abnormalities had VUR. 33 infants who had postnatal hydronephrosis also had abnormalities on prenatal US. VCUG was performed in 28 infants, none of them had VUR.

A follow-up US was performed in 72/136 infants before discharge from the hospital. Hydronephrosis was resolved in 44.4% (32 /72) of infants.

DISCUSSION

Hydronephrosis is the most common genitourinary anomaly diagnosed on prenatal ultrasound with an incidence of 0.5-7.7% (17-19). Although the incidence of VUR is increased when there is a prenatal diagnosis of hydronephrosis, there is no consensus whether VCUG should be performed in every infant (5,13). Postnatal hydronephrosis can be an incidental finding while performing abdominal ultrasonography for indications other than genitourinary tract abnormalities. However, the data is limited on the management of these infants. VCUG is an expensive and invasive procedure with several complications including infection and exposure to radiation. Our study adds new data supporting the view that VCUG may not be necessary in every infant diagnosed with hydronephrosis on postnatal ultrasonography.

In our study population, the overall incidence of VUR in postnatally diagnosed hydronephrosis was only 2.2%. This incidence is slightly higher than the baseline prevalence of 1% VUR in general population (20, 21). The two infants who had VUR also had other major congenital anomalies. Although the number of infants with major congenital anomalies was low in our cohort, the incidence of VUR in infants with postnatally diagnosed hydronephrosis in this

group of infants was much higher (14.3%). If we exclude the 14 infants with major congenital anomalies, none of the 76 infants with postnatal hydronephrosis had VUR. Davey et al also did not find any significant difference in the incidence of VUR in infants and younger children diagnosed with mild hydronephrosis on abdominal ultrasound (22). More recently, Berrocal et al in their retrospective study reported no significant correlation between VUR and postnatally diagnosed mild hydronephrosis (23). The total number of infants with grade III and IV hydronephrosis in our study population was only 10. VCUG was performed on 7 of these infants. Two infants with grade III hydronephrosis died from respiratory failure and one infant was transferred to another hospital before the VCUG was performed. Although none of these infants had VUR, the number is too small to make any conclusion. However, VCUG was performed in a much larger group of infants with grade I and II hydronephrosis. The incidence of VUR was not significantly increased in infants with mild hydronephrosis (grade I and II) as compared to the general population.

VCUG, an expensive and invasive procedure, may cause significant parental anxiety and expose infants to ionizing radiation. VCUG is also associated with catheter induced urinary tract infection, gross hematuria and dysuria (7, 24). Wosnetzer et al reported an incidence of bladder rupture during voiding cystourethrography in a premature infant (24). More recently, Kajbafzadeh et al reported two more cases of bladder rupture during VCUG in infants (26). As the incidence of VUR is not significantly increased, performing VCUG in every infant diagnosed with mild hydronephrosis may not be justifiable. Moreover, Sidhu et al in their meta-analysis on long term outcome of fetal and neonatal hydronephrosis concluded that mild hydronephrosis is a relatively benign and self-limiting condition which resolves without intervention (27). Routine performance of VCUG could be reserved for infants with mild hydronephrosis who also have associated major congenital anomalies and in infants with severe hydronephrosis as the incidence of VUR and other genitourinary abnormalities are likely to be higher in these infants (1). Acton et al in a 5 year audit of 778 neonatal renal scans reported that mild pyelectasis is a poor predictor of VUR and suggested performing a VCUG in infants with persistent pyelectasis at 2 and 6 weeks of age (14).

The incidence of VUR in prenatally diagnosed hydronephrosis ranges between 7-38% (1-7). The wide range of outcomes can be partially attributed to the lack of

standard grading systems for hydronephrosis. The data on VUR and hydronephrosis have been reported using a number of grading systems. The studies reporting higher incidence of VUR in infants diagnosed with hydronephrosis used APPD classification (1-7). Due to variability in the definition of hydronephrosis in the fetus and infants, SFU published a uniform method of detecting and classifying hydronephrosis (15). The SFU classification grades renal pelvic dilatation, the number of calyces seen and parenchymal atrophy within five grades of increasing severity (15). The SFU system is increasingly being used but it is prone to inter-observer variability as it mainly provides a qualitative assessment of hydronephrosis (15). Assessment of hydronephrosis by using APPD provides a quantitative measure of hydronephrosis and minimizes operator bias. The lower incidence of VUR in our study population can partially be explained by the use of SFU grading system, which is prone to observer bias.

The limitations of this study are a single center, retrospective analysis with a limited sample size. Despite these limitations, we conclude that in our study population, the incidence of VUR is not increased in infants diagnosed with isolated mild postnatal hydronephrosis by SFU grading system. A larger prospective study is required to determine the true incidence of VUR before recommending routine performance of an expensive and invasive procedure (VCUG) in infants with mild postnatal hydronephrosis. Future studies should be designed to overcome existing limitations and performed using standardized, reliable and reproducible grading system for hydronephrosis.

References

1. Lee RS, Cendron M, Kinnamon DD, Nguyen HT. Antenatal hydronephrosis as a predictor of postnatal outcome: a meta-analysis. *Pediatrics* 2006;118:586-593
2. Zerlin JM, Ritchey ML, Chang A. Incidental Vesicoureteral Reflux in Neonates with Antenatally detected Hydronephrosis and other renal abnormalities. *Pediatric Radiology*. 1993;187:157-160
3. Burge DM, Griffiths MD, Malone PS, Atwell JD. Fetal vesicoureteral reflux: outcome following conservative postnatal management. *J Urol* 1992;148:1743-1745.
4. Walsh G, Dubbins PA. Antenatal renal pelvis dilatation: a predictor of vesicoureteral reflux? *Am J Radiol* 1996;167:897-900
5. Yerkes EB, Adams MC, Pope JC, Brock JW. Does every patient with prenatal hydronephrosis need voiding cystourethrography? *J Urol* 1999;162:1218-1220
6. Najmaldin A, Burge DM, Atwell JD. Fetal vesicoureteral reflux. *Br J Urol*. 1990;65:403-406
7. Ismaili K, Avni FE, Hall M. Results of systematic voiding cystourethrography in infants with antenatally diagnosed renal pelvis dilatation. *J Pediatr*. 2002;14:21-24
8. Gargollo PC, Diamond DA. Therapy insight: What nephrologists need to know about primary vesicoureteral

- reflux. *Nat Clin Pract Nephrol.* 2007;3:551-563
9. Supavekin S, Kucivilize K, Hunnangkul S, Sriprapaporn J, Pattaragarn A, Sumboonnanda A. The relation of vesicoureteral reflux and renal scarring in childhood urinary tract infection. *J Med Assoc Thai.* 2006;89:S41-47
10. Olbing H, Smellie JM, Jodal U, Lax H. New renal scars in children with severe VUR: a 10-year study of randomized treatment. *Pediatr Nephrol.* 2003;18:1128-1131
11. Gloor JM, Ramsey PS, Ogburn PL, Jr, Danilenko-Dixon DR, DiMarco CS, Ramin KD. The association of isolated mild fetal hydronephrosis with postnatal vesicoureteral reflux. *J Matern Fetal Neonatal Med.* 2002;12:196-200
12. Phan V, Traubici J, Hershenfield B, Stephens D, Rosenblum ND, Geary DF. Vesicoureteral reflux in infants with isolated antenatal hydronephrosis. *Pediatr Nephrol.* 2003;18:1224-1228
13. Lidefelt KJ, Ek S, Mihocsa L. Is screening for vesicoureteral reflux mandatory in infants with antenatal renal pelvis dilatation? *Acta Paediatr.* 2006;95:1653-1656
14. Fernbach SK, Maizels M, Conway JJ. Ultrasound grading of hydronephrosis: introduction to the system used by the Society for Fetal Urology. *Pediatr Radiol.* 1993;23:478-80
15. Acton C, Pahuja M, Opie G, Woodward A. A 5-year audit of 778 neonatal renal scans (Part 1): perplexing pyelectasis and suggested protocol for investigation. *Australas Radiol.* 2003;4:349-353
16. Lebowitz RL, Olbing H, Parkkulainen KV, Smellie JM, Tamminen-Möbius TE. International system of radiographic grading of vesicoureteric reflux. *International Reflux Study in Children. Pediatr Radiol.* 1985;15:105-109
17. Dudley JA, Haworth JM, McGraw ME, Frank JD, Tizard EJ. Clinical relevance and implications of antenatal hydronephrosis. *Arch Dis Child Fetal Neonatal Ed.* 1997;76:F31-34
18. Gunn TR, Mora JD, Pease P. Antenatal diagnosis of urinary tract abnormalities by ultrasonography after 28 weeks' gestation: incidence and outcome. *Am J Obstet Gynecol.* 1995;172:479-486
19. Sairam S, Al-Habib A, Sasson S, Thilaganathan B. Natural history of fetal hydronephrosis diagnosed on mid-trimester ultrasound. *Ultrasound Obstet Gynecol.* 2001;17:191-196
20. Lebowitz RL. The detection and characterization of vesicoureteral reflux in the child. *J Urol.* 1992;148:1640-1642
21. Medical versus surgical treatment of primary vesicoureteral reflux: report of the International Reflux Study Committee. *Pediatrics.* 1981;67:392-400
22. Davey MS, Zerlin JM, Reilly C, Ambrosius WT. Mild renal pelvic dilatation is not predictive of vesicoureteral reflux in children. *Pediatr Radiol.* 1997;27:908-911
23. Berrocal T, Pinilla I, Gutiérrez J, Prieto C, de Pablo L, Del Hoyo ML. Mild hydronephrosis in newborns and infants: can ultrasound predict the presence of vesicoureteral reflux. *Pediatr Nephrol.* 2007;22:91-96
24. McAlister WH, Cacciarelli A, Shackelford GD. Complications associated with cystography in children. *Radiology.* 1974;111:167-172
25. Wosnitzer M, Shusterman D, Barone JG. Bladder rupture in premature infant during voiding cystourethrography. *Urology.* 2005;66:432
26. Kajbafzadeh AM, Saeedi P, Sina AR, Payabvash S, Salmasi AH. Infantile bladder rupture during voiding cystourethrography. *Int Braz J Urol.* 2007;33:532-535
27. Sidhu G, Beyene J, Rosenblum ND. Outcome of isolated antenatal hydronephrosis: a systematic review and meta-analysis. *Pediatr Nephrol.* 2006;21:218-224

Author Information

Seema Mathew, MD

Pediatrics/Neonatology, Cooper University Hospital-Robert Wood Johnson Medical School, One Cooper Plaza, Camden, NJ, 08103, USA

Elsayed Abdelsalam, MD

Pediatrics/Neonatology, Cooper University Hospital-Robert Wood Johnson Medical School, One Cooper Plaza, Camden, NJ, 08103, USA

Judy G Saslow, MD

Pediatrics/Neonatology, Cooper University Hospital-Robert Wood Johnson Medical School, One Cooper Plaza, Camden, NJ, 08103, USA

Barbara Amendolia, MSN, NNP

Pediatrics/Neonatology, Cooper University Hospital-Robert Wood Johnson Medical School, One Cooper Plaza, Camden, NJ, 08103, USA

Tarek Nakhla, MD

Pediatrics/Neonatology, Cooper University Hospital-Robert Wood Johnson Medical School, One Cooper Plaza, Camden, NJ, 08103, USA

Nicole Kemble, RHIT

Pediatrics/Neonatology, Cooper University Hospital-Robert Wood Johnson Medical School, One Cooper Plaza, Camden, NJ, 08103, USA

Nosrat Razi, MD

Pediatrics/Neonatology, Cooper University Hospital-Robert Wood Johnson Medical School, One Cooper Plaza, Camden, NJ, 08103, USA

Gary E Stahl, MD

Pediatrics/Neonatology, Cooper University Hospital-Robert Wood Johnson Medical School, One Cooper Plaza, Camden, NJ, 08103, USA

Zubair H Aghai, MD

Pediatrics/Neonatology, Cooper University Hospital-Robert Wood Johnson Medical School, One Cooper Plaza, Camden, NJ, 08103, USA