

# Early mycosis fungoides: Management of stage IB with phototherapy

J Zic

---

## Citation

J Zic. *Early mycosis fungoides: Management of stage IB with phototherapy*. The Internet Journal of Dermatology. 2008 Volume 7 Number 3.

DOI: [10.5580/33c](https://doi.org/10.5580/33c)

## Abstract

John Alan Zic, MD, earned his medical degree from the Vanderbilt University School of Medicine in Nashville, Tennessee. He then completed an internship in internal medicine at the University of Chicago Hospital and a residency in dermatology (serving as chief resident) at the University of Illinois at Chicago Hospital.

Dr. Zic currently is Associate Professor of Medicine in the Division of Dermatology of Vanderbilt University's School of Medicine and the Associate Dean of Admissions for the medical school. In 1996 he established the multidisciplinary Vanderbilt University Cutaneous Lymphoma Clinic.

Dr. Zic has served as principal investigator in numerous studies on cutaneous lymphoma. He serves on the international editorial board of the American Journal of Drugs in Dermatology while also serving as a reviewer for numerous journals. His primary research interests focus on variables predicting response and survival of patients with cutaneous lymphomas. He is a member of several professional organizations, including the American Academy of Dermatology, the International Society for Cutaneous Lymphoma, the United States Consortium for Cutaneous Lymphoma, the Society for Investigative Dermatology, and the Tennessee Dermatology Society.

While at Vanderbilt University, Dr Zic has earned a Master Clinical Teacher appointment, a CANDLE Award for medical student mentoring/teaching, a Grant Liddle Award for research mentoring of young physicians and in 2007 he was elected a Founding Member of the Vanderbilt University School of Medicine Academy of Excellence in Teaching.

## INTRODUCTION

Early stage mycosis fungoides (MF) includes those patients with patches and plaques who may have palpable lymph nodes, but subsequent lymph node biopsy reveals benign or dermatopathic findings. Patients with patches and plaques covering less than 10% body surface area (BSA) (T1) are classified as stage IA, those with patches and plaques covering greater than 10% BSA (T2) are classified as stage IB, and those with dermatopathic lymphadenopathy (N1) are classified as stage IIA. The prognosis for patients with early stage mycosis fungoides is good. In fact, the survival of patients with stage IA MF is not affected by the disease, an important detail to share with patients.

Treatment for early stage MF should focus on applying skin-directed therapies to gain control of the disease and, hopefully, prevent progression to more advanced disease. The following case will highlight the use of phototherapy in the treatment of stage IB MF.

## CASE PRESENTATION

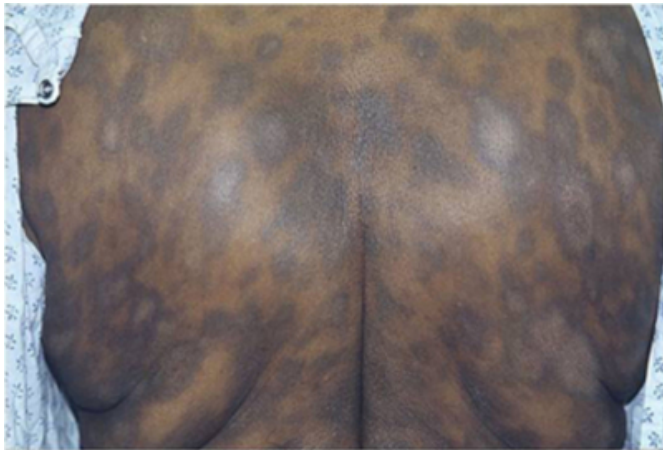A 53-year-old African-American female patient presents with a five-year history of an asymptomatic slowly progressive rash. She does not recall any triggering events at the onset of the rash. She believes she may have had hives which left her with the spots. Her past medical history is significant for diabetes and hypertension, both well-controlled. Medications include metformin, enalapril and furosemide.

Physical examination shows normal vital signs, normal cardiopulmonary exam, and normal gastrointestinal exam. There are no palpable lymph nodes in the cervical, axillary, or inguinal regions. Total skin examination reveals a

generalized eruption of 2cm to 6cm ill-defined dark brown, hyperpigmented patches covering 50% BSA on the trunk more than the extremities. Many of the patches show central grayish white hypopigmentation. (Figure 1)

**Figure 1**

Figure 1



## CONSIDERATIONS FOR DERMATOLOGIST AND ONCOLOGIST

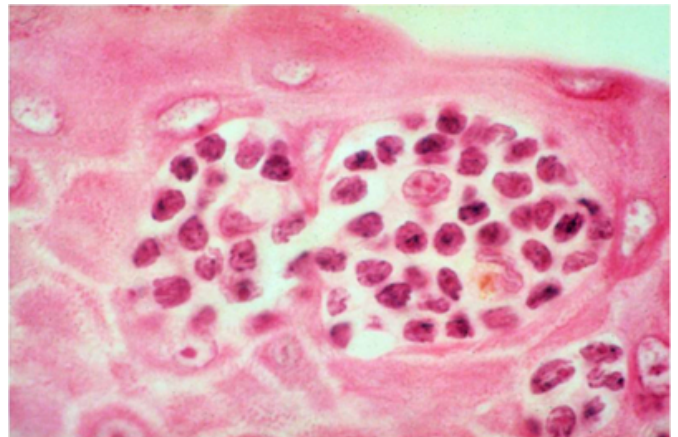
Dermatologists should recognize the clinical features of this case that suggest a diagnosis of mycosis fungoides. The history of a chronic rash without significant pruritus primarily involving sun-protected areas is consistent with MF. In dark-skinned patients, the presence of hypopigmented patches should add mycosis fungoides to the diagnostic differential. Hypopigmented patches on the trunk suggest the following possibilities beyond MF: eczematous dermatitis, post-inflammatory hypopigmentation, tinea versicolor, drug eruption, secondary syphilis, and sarcoidosis. Therefore, skin biopsies are indicated to clarify the diagnosis.

## PATHOLOGY

Three 6mm punch skin biopsies are performed from the back, right thigh and buttock. Histopathology shows a dense band-like infiltrate of mononuclear cells in the upper dermis. Within the epidermis are numerous scattered mononuclear cells with cerebriform hyperconvoluted nuclei. One section demonstrates a collection of these atypical cells in association with a Langerhan's cell (SEE FIG 2). There is no spongiosis. Immunostains identify the mononuclear cells within the epidermis as CD4 positive T cells with loss of CD7 staining.

**Figure 2**

Figure 2



## DIAGNOSIS

The clinical and pathologic findings are diagnostic of mycosis fungoides. The presence of patches covering 50% BSA with no enlarged lymph nodes supports the clinical stage IB. The prognosis is good with treatment to get control of the disease and slow progression. The ISCL recommended staging studies includes primarily blood work without the need for CT scans unless clinically indicated. Because this patient had no palpable lymph nodes and patches, not thick plaques, the decision was made to not perform CT scans.

The following laboratory studies were negative or normal: comprehensive metabolic panel except for blood glucose 200mg/dl (<120mg/dl), complete blood count with differential and platelets, lactate dehydrogenase, and flow cytometry.

Treatment for stage IB MF should include skin-directed therapies based on their efficacy and favorable side effect profile. Both mechlorethamine (nitrogen mustard, NM) ointment and phototherapy offer reasonable skin-directed treatment options. There are no well-controlled clinical trials comparing these therapies head-to-head. NM ointment 0.01% is normally applied to the entire skin surface sparing hair bearing sections of the scalp and genitalia. For patients with minimal skin involvement, application of NM ointment to affected region may be a reasonable option, but is unlikely to suppress spread of the disease beyond the treated region.

There are two primary forms of phototherapy: narrow band UVB (NBUVB) and psoralen and UVA (PUVA). In the latter, patients ingest a photoactivated drug, 8-methoxypsoralen, one hour before exposing the skin to UVA light. Patients who fail these skin-directed therapies may

respond to the addition of oral bexarotene capsules or subcutaneous interferon alfa to their skin-directed therapy. Often, bexarotene is prescribed as monotherapy whereas interferon alfa is usually prescribed as part of combined modality therapy with PUVA phototherapy, photopheresis or bexarotene capsules.

### MANAGEMENT

After discussing the risks and benefits of all treatment options, the patient chose to pursue phototherapy over the NM ointment because she did not like the idea of having a greasy ointment on her skin for most of the day. Because she had patches rather than thick plaques, the NM ointment would have been a reasonable treatment option also. Both NBUVB and PUVA are effective treatment options for early stage IA and IB MF. Several studies support the claim that NBUVB is equal in efficacy to PUVA phototherapy in the treatment of early stage MF. Relapse is expected at an overall rate of 50% with both modalities. The psoralen ingested with PUVA may cause nausea. The longest interval between NBUVB treatments is usually 7 to 10 days to prevent phototoxicity whereas intervals of 1 to 3 months can be safely maintained between PUVA phototherapy treatments.

Because NBUVB phototherapy was not readily available from her local dermatologist the patient began PUVA phototherapy three times weekly. By her 15th treatment the patient showed more homogeneous pigmentation of her dyspigmented patches. After 3 months of PUVA her interval was decreased to twice weekly for two months then once weekly for two months then once every two weeks. The patient showed significant clearing of her skin with subtle patches primarily on the inner thighs (difficult areas for PUVA exposure). The residual disease on the inner thighs responded well to clobetasol 0.05% ointment applied twice daily for 6-8 weeks. The decision was made to stop PUVA

and engage in watchful waiting. The relapse rate is approximately 50% with PUVA regardless of a long maintenance regimen (one treatment every two months) or stopping the PUVA. Because there is a significantly increased risk of melanoma in patients that receive more than 250 PUVA treatments it is reasonable to limit exposure to PUVA.

### CONCLUSIONS

Clinicians need to be alert to the possibility of the diagnosis of mycosis fungoides in any patient with a chronic rash in sun-protected areas. Multiple biopsies are often needed to nail the diagnosis. Patients with stage IB MF may respond to NM ointment or phototherapy. It will take months of either modality to demonstrate a response. Fortunately, phototherapy is a highly effective approach to stage IB MF with a majority of patients responding well and only a small minority of patients progressing to more aggressive disease.

### References

1. Kim Y, Lim H, Mraz-Gernhard S, Varghese A, Hoppe RT. Long term outcome of 525 patients with mycosis fungoides and Sezary syndrome. *Arch Dermatol* 139:857-866, 2003.
2. Kim Y, Martinez G, Varghese A, Hoppe RT. Topical Nitrogen Mustard in the Management of Mycosis Fungoides. *Arch Dermatol* 139:165-173, 2003.
3. Querfeld C, Rosen ST, Kuzel TM, Kirby KA, Roenigk HH, Prinz BM, Guitart J. Long-term Follow-up of Patients With Early-Stage Cutaneous T-Cell Lymphoma Who Achieved Complete Remission With Psoralen Plus UV-A Monotherapy *Arch Dermatol* 141: 305-11, 2005.
4. Ghodsi Z, Hallaji Z, Balighi K, Safar F, Chams-Davatchi C. Narrow-band UVB in the treatment of early stage mycosis fungoides: report of 16 patients *Clin Exp Dermatol* 30: 376-8; 2005.
5. El-Mofty M, El-Darouty M, Salonas M, Bosseila M, Sobeih S, Leheta T, Nada H, Tawdy A. Narrow band UVB (311 nm), psoralen UVB (311 nm) and PUVA therapy in the treatment of early-stage mycosis fungoides: a right-left comparative study *Photodermatol Photoimmunol Photomed* 21:281-6; 2005.

**Author Information**

**John A. Zic, MD**

Associate Professor of Medicine Director, Vanderbilt University Cutaneous Lymphoma Clinic, Division of Dermatology,  
Vanderbilt University School of Medicine