

# Mesenteric cystic lymphangioma

A Nejmeddine, A Sonia, H Sondes, B Salah, B Issam

## Citation

A Nejmeddine, A Sonia, H Sondes, B Salah, B Issam. *Mesenteric cystic lymphangioma*. The Internet Journal of Surgery. 2008 Volume 19 Number 1.

## Abstract

Mesenteric cystic lymphangioma is an uncommon benign abdominal mass. A new case is presented, combined with lymphadenitis. In our case, mesenteric cystic lymphangioma was located near the jejunum. This finding suggests that mesenteric cystic lymphangioma could have evolved as a consequence of obstruction of the lymphatics. We hypothesize that in patients with lymphatic obstruction, mesenteric cystic lymphangioma may be regarded as an acquired anomaly. The lesion was removed surgically with complete resection which is the optimal treatment with excellent prognosis.

## INTRODUCTION

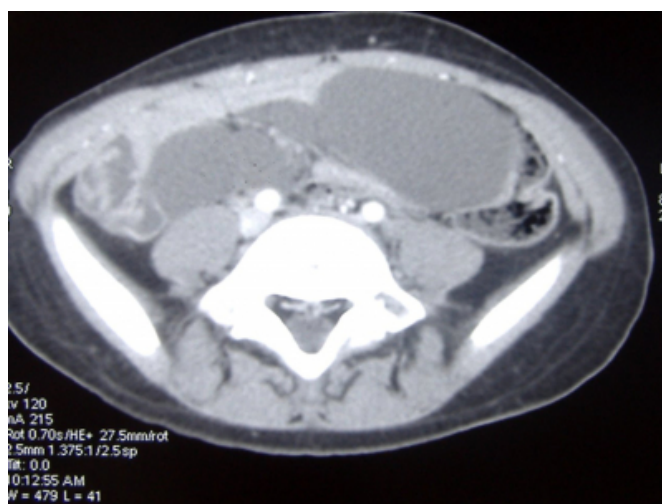Mesenteric cystic lymphangiomas are rare benign cystic tumors, most often seen in pediatric patients, with fewer than 250 detailed reports published in the English-language literature. The etiology is unknown, though some believe that it might be associated with developmental anomalies of the lymphatics. Other possible etiologies include bleeding or inflammation in the lymphatic channels with obstruction and subsequent lymphangioma formation. The clinical presentation is diverse, ranging from an incidentally discovered abdominal cyst to symptoms of acute abdomen.

## CASE REPORT

A 5-year-old female child presented to the Emergency Department complaining of abdominal pain with recurrent episodes of vomiting for 2 weeks. The past medical history was otherwise unremarkable. On physical examination, she was pale and not dehydrated. The abdomen was soft but painful, with an extremely tender mass palpable in the lower abdomen. Bowel sounds were hypoactive; both rest of the abdomen and digital rectal examination were unremarkable. Laboratory results were within normal limits. The plain abdominal films suggested a soft tissue mass in the mid-abdomen. CT scan showed a large cyst, with attenuation values in the range of water, possibly originating in the small intestine (Fig. 1).

## Figure 1

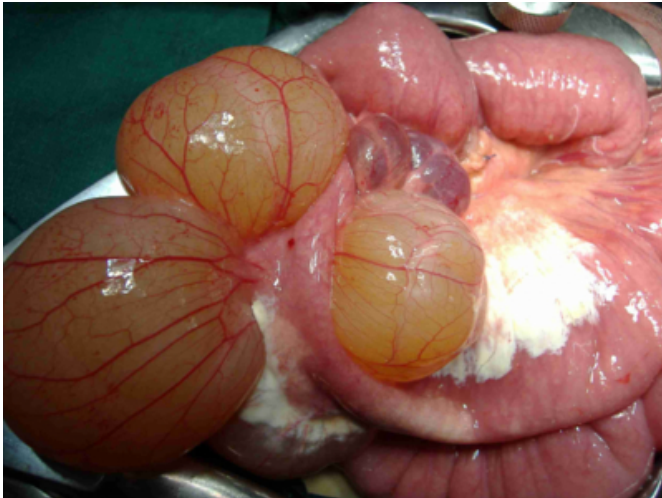
Figure 1: CT scan showing intra-abdominal cystic lymphangioma with attenuation values in the range of water.



Exploratory laparotomy revealed cysts in the mesentery of the jejunum without adhesions to adjacent bowel. The cystic mass contained clear yellow fluid (Fig. 2); enlarged lymph nodes were found (Fig 3). The rest of the abdomen was normal and without free intraabdominal fluid. The mass was resected. The postoperative course was unremarkable.

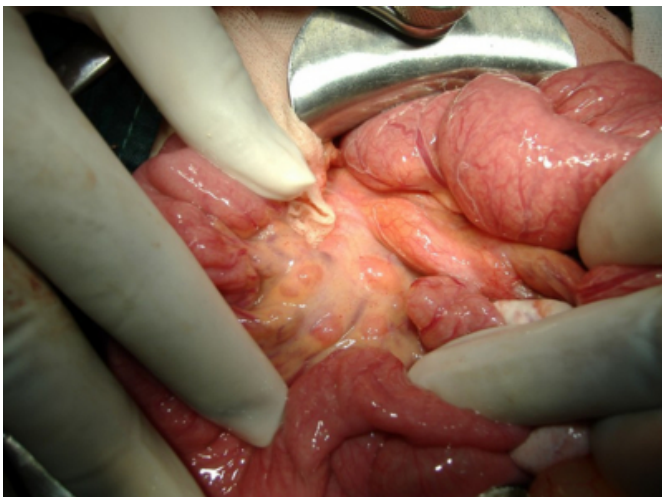**Figure 2**

Figure 2: Mesenteric cystic mass containing clear yellow fluid



**Figure 3**

Figure 3: Enlarged mesenteric lymph nodes.



At microscopical pathological examination, the cyst wall showed attenuated endothelial lining positive for CD 31, smooth muscle fibers, and fibrovascular adipose tissue. Lymphocytic aggregates were seen throughout the cyst wall, with diffuse chronic inflammatory infiltration below the endothelial lining. Based on these findings, the final diagnosis of mesenteric cystic lymphangioma was made. At 6 and 24 months follow-up, our patient was completely asymptomatic and ultrasonography and CT showed no evidence of recurrence.

## DISCUSSION

Cystic lymphangiomas are uncommon, congenital benign tumours of the lymphatic system. They occur mainly in the cervical or axillary region, while abdominal locations are

rare (<3% of all childhood cases). Any abdominal lymph structure may be the seat of a lymphangioma; locations can be mesenteric, omental, mesocolic and retroperitoneal [1]. Abdominal lymphangiomas are more common in boys and usually occur in childhood. Pathogenesis remains unknown, and many possible pathological processes have been proposed, including benign proliferation of ectopic lymphatics [2]. Different hypotheses on the etiopathogenesis of mesenteric cystic lymphangioma have been postulated. It has been suggested that mesenteric cystic lymphangioma is a congenital malformation. Mesenteric cystic lymphangioma has been associated with volvulus, and lymphadenitis with obstruction of the lymphatics. It may lead to venous and lymphatic congestion. Adequate lymphatic drainage is compromised and lymphangioma or a chylous mesenteric cyst may arise [3]. Sonography generally demonstrated well-defined cystic masses with internal septations. On sonography and CT, the internal content was usually similar to water; occasionally a cystic lymphangioma was uniloculated. The presence of echogenic contents, a thick capsule and septation indicated internal bleeding or infection. Sonography was superior to CT in the demonstration of the internal nature of the cysts [4].

Differential diagnosis includes diverse cystic masses of intra- or retroperitoneal origin. Intraperitoneal lymphangiomas are more commonly seen in the mesentery than in the omentum. Differential diagnosis of intraperitoneal cystic masses includes pancreatic pseudocysts, enteric duplication cysts, cystic mesotheliomas, and ascites. The presence of an enhancing thick wall is helpful in characterizing a lesion as either a pseudocyst or an enteric duplication cyst [4]. Clinical presentation of abdominal lymphangiomas is variable and may be misleading. Chronic non-specific abdominal signs include progressive abdominal distension and chronic abdominal pain, while the most common acute signs are acute abdominal pain and distension, vomiting, fever and peritonitis [2,5]. Complete surgical excision is the treatment of choice for both duplication and lymphangioma; prognosis is excellent if the resection is complete [2].

Pathologically, lymphangiomas are subdivided into three main types: capillary, cavernous, and cystic. The first two are predominantly cutaneous lesions; cystic lymphangiomas are generally found in the abdomen and retroperitoneum [6]. Lymphangioma is characterized by stromal aggregates of lymphocytes and an endothelial lining that usually stains positively with factor VIII-related antigen or CD31, and that

is often surrounded by a layer of smooth muscle tissue [7]. The treatment of mesenteric cystic lymphangioma is surgical; total excision is required. Resection of lymphangioma may sometimes require resection of adjacent bowel or other structures because it is often closely attached to the enteric vascularity [3], but the results are often unsatisfactory because of complications, particularly recurrence owing to incomplete excision. For these reasons, intralesional injection of sclerosing agents has been proposed. But because of the risk of damage to vital structures, surgical excision might be the treatment of choice [8].

### CORRESPONDENCE TO

Affes Nejmeddine Department of General Surgery Habib Bourguiba Hospital Sfax 3003, Tunisia Tel: 216 98500014  
E-mail: affesnejm@yahoo.fr

### References

1. Siegel MJ, Glazer HS, St. Amour TE, Rosenthal DD. Lymphangioma in children: MR imaging. *Radiology* 1989; 170: 467-70.
2. Quaglietta L, Mastroianni R, Miele E, Esposito C, Terracciano LM, Vallone G, Staiano A. Cystic lymphangioma associated with enteric duplication as a cause of recurrent vomiting *Digestive and Liver Disease* 2005; 37: 533-536.
3. Weeda VB, Booi KA, Aronson DC. Mesenteric cystic lymphangioma: a congenital and an acquired anomaly? Two cases and a review of the literature. *J Ped Surg* 2008; 43, 1206-1208.
4. Vargas-Serrano B, Alegre-Bernal N, Cortina-Moreno B, Rodriguez-Romero R, Sanchez-Ortega F. Abdominal cystic lymphangiomas: US and CT findings. *Eur J Radiol* 1995; 19: 183-187.
5. Troum S, Solis MM. Mesenteric lymphangioma causing bowel obstruction in a child. *South Med J* 1996; 89: 808-9.
6. Losanoff JE, Richman BW, El-Sherif A, Rider KD, Jones JW. Mesenteric cystic lymphangioma. *J Am Coll Surg* 2003; 196: 589-603.
7. Haeng Chung J, Lim Suh Y, Ac Park I, Jang J, Chi JG, Kim YI, Kim WH. A pathologic study of abdominal lymphangiomas. *J Korean Med Sci* 1999; 14: 257-262.
8. Okazaki T, Iwatani S, Yanai T, Kobayashi H, Kato Y, Marusasa T, Geoffrey JL, Yamataka A. Treatment of lymphangioma in children: our experience of 128 cases. *J Ped Surg* 2007; 42, 386-389.

**Author Information**

**Affes Nejmeddine**

Department of General Surgery, Habib Bourguiba Hospital

**Annabi Sonia**

Department of General Surgery, Habib Bourguiba Hospital

**Haddar Sondes**

Department of Radiology, Habib Bourguiba Hospital

**Boujelben Salah**

Department of General Surgery, Habib Bourguiba Hospital

**Beyrouti Mohamed Issam**

Department of General Surgery, Habib Bourguiba Hospital