

Malposition Of Internal Jugular Vein Cannula Into Ipsilateral Subclavian Vein In Reverse Direction- Unusual Case Report

D Malhotra, S Gupta, S Gupta, B Kapoor

Citation

D Malhotra, S Gupta, S Gupta, B Kapoor. *Malposition Of Internal Jugular Vein Cannula Into Ipsilateral Subclavian Vein In Reverse Direction- Unusual Case Report*. The Internet Journal of Anesthesiology. 2008 Volume 22 Number 1.

Abstract

Malpositioning of CVC inserted into the subclavian vein and IJV is a known and dreaded complication. The most common misplacement of the subclavian vein catheter is into the IJV (5.4%) and does not vary with the side of insertion or whether the head is turned towards or away from the side of insertion.¹ Our case report is about misplacement of catheter in the reverse direction towards the axillary vein (reverse direction) inserted through IJV.

INTRODUCTION

Percutaneous cervical central venous cannulation is now common during perioperative care of major surgical patients, in intensive care monitoring, for long-term hyperalimentation and also for securing a central vein for rapid restoration of blood volume in a case of unexpected acute blood loss. Advantages of internal jugular vein cannulation relate to its consistent, predictable, anatomic location, its valve less course to the superior vena cava and right atrium, the possibility of repeated cannulation and low incidence of complications in experienced hand.

Placement of CVC is technically challenging procedure. Reported incidence of malpositioning of CVC varies extremely wide range <1% to >60%^{2, 3}. Most common misplacement is towards ipsilateral IJV. Malpositioning of CVC inserted through IJV approach towards axillary vein instead of right atrium is very unusual. We report one such unusual case occurring in ICU setting.

CASE PRESENTATION

A 26 year old male, a case of road traffic accident with head injury and CTscan proved Right temporo-parietal contusion with midline shift with GCS 7(E2V2M3) was admitted in ICU for elective ventilation. Patient was hemodynamically stable with pulse 90b/m BP 126/70. After putting patient on A/C mode, CVC inserted through right sided internal jugular vein approach in single go. Guide wire went freely. Adequate backflow of blood and free inflow of normal saline confirms IV position of Central Vein Catheter. CVP

recorded was zero. CVP was not rising even after adequate crystalloid and blood administration. Check chest X-ray was done which showed to our surprise that catheter tip was placed in retrograde position in subclavian vein as shown in

Figure 1

FIGURE: 1- Chest X-Ray showing retrograde placement of IJA central vein cannula in Rt.subclavian vein

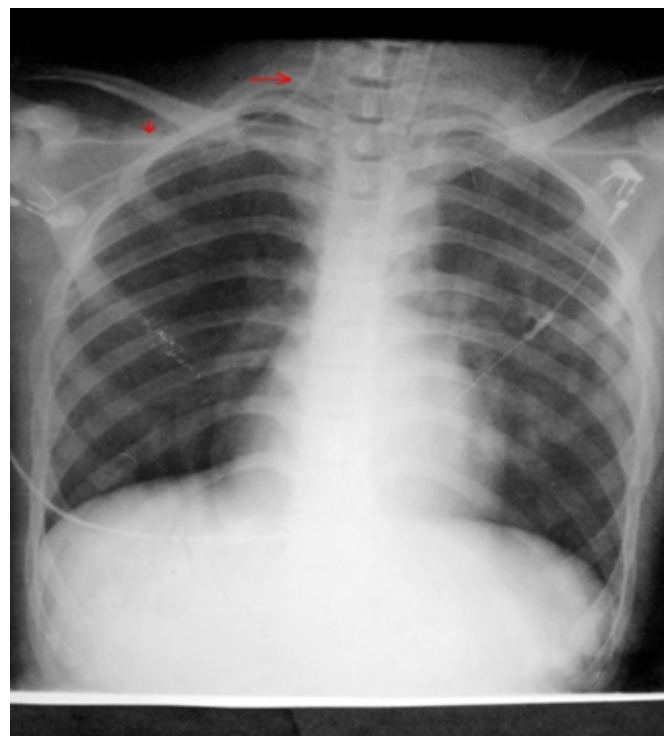
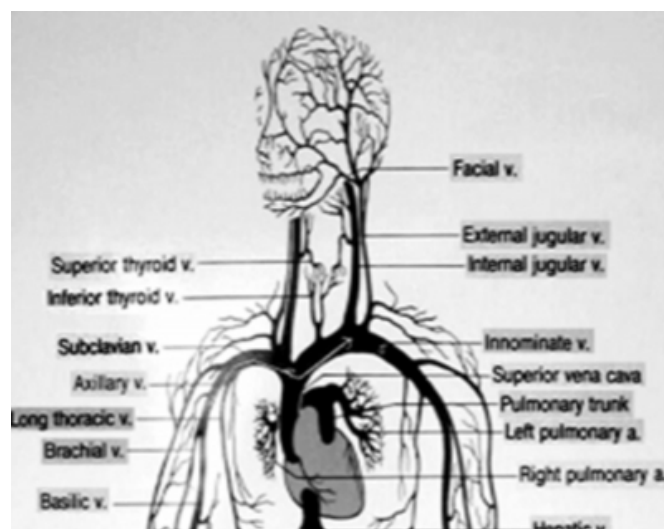


Figure 2

Figure 2- shows the anatomic landmarks for the venous cannulations in the neck



The patient was shifted to the Neurosurgical OT for evacuation of contusion. Immediately under fluoroscopy, guide wire was reinserted and the CVC was withdrawn. The guide wire was pulled out to some extent and redirected and the CVC was inserted and tip of catheter was being seen at junction of the SVC and Right Atrium under fluoroscopy. The CVP recorded was 6cm H₂O. Surgery was done and the patients shifted back to the ICU for elective ventilation.

DISCUSSION

Central venous catheter insertion is a common procedure used in monitoring CVP, administration of some drugs, blood and blood products, antineoplastic treatment, Parenteral nutrition, and bone marrow transplantation. Central venous catheters can be centrally or peripherally inserted; however, the commonly referred technique is the internal jugular or subclavian veins. These complications can be listed as arterial puncture, pneumothorax, chylothorax, Vein and nerve damage, infection, thrombosis, malposition, folding of the catheter, hemothorax, cardiac tamponade, air embolism, arrhythmia, and death¹.

Catheter malpositioning is a known complication of central venous catheterization² though uncommon complication of the cannulation and detected by immediate check chest X-ray or USG guided placement. The most common cause of early malfunctioning of the central venous catheter is related to its malpositioning.³ Central venous catheter tip placement at the junction of SVC and right atrium is important for accurate central venous pressure (CVP) measurement⁴. A

misplaced catheter tip not only defeats the purpose of correctly measuring CVP but also predisposes it to the risk of obstruction to aspiration, clotting, thrombophlebitis, erosion of the venous wall, cardiac tamponade, and failure to aspirate air in the event of air embolism.^{5, 6} Most common of all misplacements is the cephalad insertion into ipsilateral IJV via subclavian approach. Paw⁷ stated catheterization via the left internal jugular vein results in more malpositioning and vascular perforation than catheter placed from the right internal jugular vein. Other sites for misplacements include azygous vein, thymic vein, contralateral subclavian vein.⁸ According to Muhm et al⁹ study the frequency of malpositioning was related to the anatomic approach and the catheter type used, but not to the physicians experience. Their reported respective incidences were 4.12% for the left internal jugular access, but were lower for the right internal jugular (1.1%); Misplacement was more frequent with soft silicone catheters (2.53%) than with semi-rigid catheters (0.79%). Retrograde malpositioning of CVC in axillary vein is very unusual presentation as in our case report. Studies have hypothesized that final position of catheter tip depends on the course the guide wire takes which is influenced by the initial orientation of J type guide wire tip during subclavian approach.

In a randomized controlled study authors suggest that keeping the guidewire J tip directed caudad increase correct placement of CVC towards atrium.¹⁰ Even use of USG guided insertion is controversial. Some suggest USG improves success rate of insertion performed by less experienced operator. Other suggests it has no significant effect on catheter insertion. The US guided technique is a safer procedure especially in older patients; it affords an easier and more rapid cannulation of a central vein, drastically reducing major and minor complications.¹¹ Catheter placements is a blind procedure and misplacement of CVC remains a known but uncommon complication as in our case report showing unusual misplacement. The radiographic incidence of central venous catheter malpositioning is low and that clinical use of malpositioned catheters is associated with few complications. However, determination of the catheter position by chest X-ray should be considered when mechanical complications cannot be excluded, aspiration of venous blood is not possible, or the catheter is intended for central venous pressure monitoring, high flow use or infusion of local irritant drugs.¹²

References

1. Gladwin MT, Slonim A, Landucci DL, Gutierrez DC, Cunnion RE: Cannulation of the internal jugular vein: is postprocedural chest radiography always necessary? *Crit Care Med* 1999; 27:1819-1823
2. Sanchez R, Halck S, Walther-Larsen S, et al. Misplacement of subclavian venous catheters: importance of head position and choice of puncture site. *Br J Anaesth* 1990; 64: 632-3
3. Boardman P, Hughes JP. Radiological evaluation and management of malfunctioning central venous catheters. *Clin Radiol* 1998; 53: 10-6
4. McGee WT, Ackerman BL, Rouben LR, et al. Accurate placement of central venous catheters: a prospective, randomized, multicenter trial. *Crit Care Med* 1993; 21: 1118-23.
5. Collier PE, Blocker SH, Graff DM, Doyle P. Cardiac tamponade from central venous catheters. *Am J Surg* 1998; 176: 212-4.
6. Conces DJ, Holden RW. Aberrant locations and complications in initial placement of subclavian vein catheters. *Arch Surg* 1984; 119: 293-5.
7. HGW PAW: Bilateral pleural effusions: unexpected complication after left internal jugular venous catheterization. *BJ Anaesth*; 89(4):647-50, 2002.
8. Currarino G. migration of jugular or subclavian venous catheters into inferior tributaries of brachiocephalic veins or into the Azygous veins, with possible complications. *Pediatr Radiol* 1996; 26:439-49.
9. Muhm M, Sunder-Plassmann G, Apsner R et al: Malposition of central venous catheters. *Wien Klin Wochenschr.* 6; 109(11):400-5, 1997.
10. Tripathi M, Dubey pk, ambesh SP. Direction of J – tip of the guidewire, in seldinger technique, is a significant factor in misplacement of subclavian vein catheter: a randomized, controlled study. *Anesth analg* 2005; 100: 21-4.
11. Massimo Cajozzo, Gerlando Cocchiara, Geo Greco, Roberto Vaglica, et al: *J. Surg. Oncol.*2004;88:267-268.
12. PikwerA , Baath L, Davidson B, Perstoft I, Akesson J. *Anaesth Intensive care.*2008 Jan;36(1):30-7

Author Information

Dinesh Malhotra, MD

Senior Resident, Department of anesthesiology and critical care, Govt.Medical College Jammu, J&K India.

Sunny Gupta

Post graduate, Department of anesthesiology and critical care Govt.Medical College Jammu, J&K India

Satyadev Gupta, MD

Ex. Professor and head, Department of anesthesiology and critical care, Govt.Medical College Jammu, J&K India.

BB Kapoor

Professor and Head, Department of anesthesiology and critical care, Govt.Medical College Jammu, J&K India.