

Severe Postural Respiratory Insufficiency Following Interscalene Brachial Plexus Block: A Case Report

X Chen, S B Bhatt, K D Jenkins

Citation

X Chen, S B Bhatt, K D Jenkins. *Severe Postural Respiratory Insufficiency Following Interscalene Brachial Plexus Block: A Case Report*. The Internet Journal of Anesthesiology. 2016 Volume 35 Number 1.

DOI: [10.5580/IJAPA.38892](https://doi.org/10.5580/IJAPA.38892)

Abstract

Background: Phrenic nerve block leading to ipsilateral diaphragmatic paralysis is common following the performance of an interscalene brachial plexus block. The diaphragmatic paralysis is generally well tolerated by most patients. Here, we present a case of severe postural respiratory insufficiency following the performance of an interscalene block, in a patient with unrecognized contralateral diaphragmatic eventration.

Case presentation: A 53-year-old male with a history of a laparotomy following a motor vehicle accident some years previously, was scheduled to undergo arthroscopic repair of his right rotator cuff. The patient was administered an ultrasound-guided interscalene brachial plexus block for post-operative pain control. The patient remained asymptomatic following the placement of the block while he was in the sitting up position. When he was laid supine for the induction of general anesthesia, he developed severe respiratory insufficiency. The surgery was cancelled. Subsequent chest x-ray and CT scan imaging revealed diaphragmatic eventration on the contralateral side.

Conclusion: Unrecognized pathology of the contralateral lung can lead to severe respiratory insufficiency following the placement of an interscalene block.

BACKGROUND

The interscalene brachial plexus block (ISBPB) is frequently performed either as a primary anesthetic or for the provision of post-operative pain relief in patients undergoing shoulder surgical procedures.(1) Although the ISBPB is easy to perform and has few complications, concomitant occurrence of phrenic nerve block is universal.(2,3) The phrenic nerve blockade leads to diaphragmatic paralysis with accompanying decrease in pulmonary function. This decrease in pulmonary function is well tolerated by most patients.(4) For those patients in whom the diaphragmatic paralysis may not be well tolerated, the ISBPB is generally avoided. Due to the risk of diaphragmatic paralysis, it is recommended that the ISBPB not be performed in patients who have severe respiratory disease, contralateral pneumonectomy or contralateral diaphragmatic paralysis.(4) Despite these caveats, the ISBPB occasionally results in respiratory insufficiency. In most reported cases of respiratory insufficiency following the ISBPB, there are preoperatively identifiable risk factors.(5,6,7) Here, we present a case of severe postural respiratory insufficiency

following an ISBPB in a patient in whom the contralateral diaphragmatic pathology was not preoperatively identified. The patient that is the subject of this report has consented to the publication of this report.

CASE REPORT

A 53-year-old Hispanic male was scheduled to undergo arthroscopic repair of his right rotator cuff. His medical history was significant for hypertension treated with lisinopril 10 mg and amlodipine 5 mg, PO daily. He also had a 25-pack-year history of smoking. He was obese with a body mass index (BMI) of 31 Kg/m². He had no symptoms related to his cardiac or respiratory systems. Ten years prior, the patient had undergone laparotomy following a motor vehicle accident that had caused blunt abdominal trauma. He did not have any symptoms related to this laparotomy and was unaware of the actual operative procedure performed. Preoperatively, his vital signs were: non-invasive blood pressure (NBP) 170/102 mm Hg, heart rate (HR) 94/min, respiratory rate (RR) 16 b/min. His pulse oximetric saturation was 98% while breathing room air. Bilaterally, his

lung sounds were clear with no adventitious sounds.

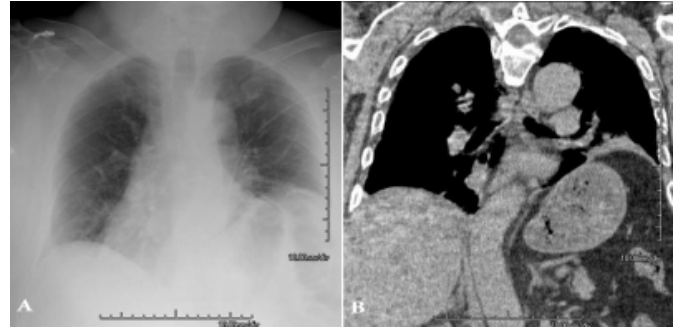Following discussion of his anesthetic options, the patient agreed to undergo his surgical procedure under a general anesthetic and elected to have an ISBPB for postoperative pain relief. An ultrasound guided ISBPB was performed following intravenous administration of 2 mg of midazolam. ISBPB was performed using real time ultrasound guidance. The nerve roots were visualized at the level of the cricoid cartilage and a 22 g short bevel needle was directed using an in-plane technique. A total of 20 ml of 0.25% bupivacaine was injected. After the placement of the block, the patient was placed in a 45 degree head up position and continuously monitored with pulse oximetry. The patient had no complaints while in the pre-operative holding area. Thirty minutes after the placement of the nerve block, the patient was moved to the operating room for his scheduled surgical procedure.

As soon as the patient was transferred to the operating table and laid supine, he experienced severe respiratory difficulty. The patient became tachypneic (respiratory rate 35-40/min) and his SpO₂ dropped to 75% despite breathing 100% oxygen via a face mask. He was using his accessory muscles. Upon sitting up, his symptoms were relieved immediately. His SpO₂ recovered to 96%. After having the patient sit up for 5 minutes, when his respiratory symptoms had subsided, another attempt was made to lay him supine for the induction of general anesthesia. Immediately upon assuming the supine position, the patient developed severe respiratory insufficiency similar to the first attempt. At this stage, his surgery was cancelled. He was placed in a sitting position, and brought to the recovery room for further management.

In order to diagnose the cause of his orthopnea, we performed a 12 lead EKG. This revealed no abnormality. He underwent an echocardiogram which revealed a normal left ventricular function and no wall motion abnormalities. His cardiac enzymes were within normal range. He also underwent a chest X-ray which revealed a left diaphragm elevation suggesting possible diaphragmatic eventration. This was on the contralateral side of his ISBPB (Figure 1A). Subsequent CT scan of his chest confirmed the diagnosis of diaphragmatic eventration (Figure 1B).

Figure 1

Chest imaging study. (A) – chest X ray frontal projection demonstrating elevated left hemidiaphragm suggesting eventration. (B) – Coronal reconstruction of CT scan of the chest showing high and thin left hemidiaphragm consistent with eventration. Also seen is left lower lobe plate like atelectasis and cephalad displacement of abdominal viscera.



Medical records from an outside hospital where he had previously undergone laparotomy for blunt abdominal trauma were obtained. The operative report of his laparotomy revealed that a flaccid and elevated left hemidiaphragm was found, for which a plication/imbrication procedure was performed.

The patient remained asymptomatic while sitting up during the rest of his hospital stay. Later that evening he was discharged home after the effects of the ISBPB had regressed. He came back two weeks later and underwent an uneventful rotator cuff repair under general anesthesia without a nerve block.

DISCUSSION

Due to the well-recognized contraindications of the ISBPB, it is extremely rare to see bilateral diaphragm paralysis. In healthy individuals, the ISBPB rarely causes any symptoms. Phrenic nerve blockade following performance of an ISBPB is common.(2,3) The resulting transient phrenic nerve paralysis is well tolerated by most patients without significant pulmonary pathology.(8)

The phrenic nerve takes origin from C3,4,5 dermatomes and at the level of the cricoid cartilage it is in close proximity to the C5, 6 nerve roots.(9) It is these C5, 6 nerve roots that are targeted when performing an ISBPB for surgical procedures on the shoulder. The proximity of the phrenic nerve to the C5, 6 nerve roots commonly leads to phrenic nerve blockade following performance of an ISBPB.(2,3) This blockade of the phrenic nerve leads to ipsilateral diaphragmatic paralysis.

Investigators have attempted to modify the technique of the ISBPB to reduce the incidence of phrenic nerve blockade.

These modifications include reduced volume of local anesthetic or application of digital pressure.(10,11,12) However, none of these techniques consistently eliminate the risk of phrenic nerve blockade.

The diaphragmatic paralysis caused by an ISBPB causes a decrease in respiratory function. The FVC and FEV1 are decreased about 25%, with a 15% reduction in the peak expiratory flow rate. This diminution of respiratory function caused by the phrenic nerve blockade is well tolerated by most patients. On occasion, patients develop dyspnea or respiratory insufficiency following an ISBPB. In most of these reported cases of respiratory insufficiency following ISBPB there are preoperative identifiable risk factors.(5,6,7)

Respiratory insufficiency in the patient presented here was postural and occurred only when he assumed the supine position. This respiratory insufficiency was immediately relieved by sitting up. The cephalad displacement of the diaphragm on assuming the supine position results in approximately 28% decrease in FRC.(13) This is well tolerated in healthy adults. Additionally, rib cage contribution to tidal respiration is decreased in the supine position, thus making our patient more dependent on his paralyzed diaphragm on the right and the eventrated diaphragm on the left.

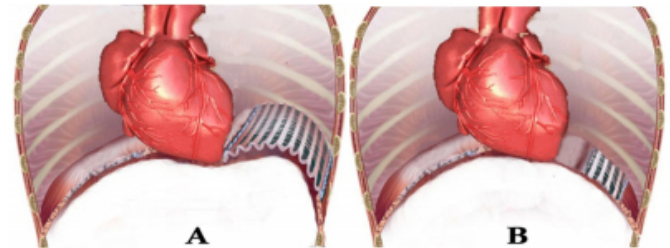
The incidence of eventration is about 1 in 10,000.(14) It is caused by protrusion of the diaphragm due to either incomplete muscularization or thinning of the diaphragm muscles. Diaphragmatic eventration leads to impairment of pulmonary function with the vital capacity being about 70% of normal in the sitting position.(15) When patients with diaphragmatic eventration assume the supine position there is further worsening of the pulmonary function. On average, patients with diaphragmatic eventration lose an additional 32% of their vital capacity in the supine position as compared with the sitting position.

Our patient underwent plication repair after an incidental discovery of his elevated diaphragm in 2002. The etiology of his eventration might be either trauma-induced or congenital. Due to the lack of a baseline chest x-ray, it is difficult to make the definitive diagnosis. However, it is very likely congenital in origin. The chest x ray shows right displacement of the mediastinum, which is a key differential feature for congenital diaphragmatic eventration.(14) The plication procedure is commonly performed to improve PFT. The diaphragm is flattened out through a series of U-

stitches (Figure 2). The final result is a firm and tense diaphragm with significantly improved PFT.

Figure 2

Plication repair of diaphragmatic eventration. (A) A series of U-stitches were placed and tied as tight as possible. (B) The final result is a tense and firm diaphragm (Reproduced from Imaging of the diaphragm: anatomy and function. Nason et al Radiographics 2012;32:E51-70 with permission).



We hypothesize that a combination of phrenic nerve blockade caused by the ISBPB on one side and the eventrated diaphragm on the contralateral side, led to severe postural respiratory insufficiency on assuming the supine position. It is possible that a pre-operative chest X-ray may have revealed the diaphragmatic elevation on the left side and the ISBPB could have been avoided. However, the lack of respiratory symptoms and a negative physical exam led us not to perform a chest X-ray preoperatively.

CONCLUSION

Unrecognized pathology in the contralateral chest can exacerbate the effects of phrenic nerve blockade that accompanies ISBPB. Due to the rare occurrence of diaphragmatic eventration, most anesthesiologists may be unaware of its implications in ISBPB. Unrepaired diaphragm eventration should be considered as an absolute contraindication for any regional procedure that might compromise phrenic nerve function on the contralateral side. If a repair procedure has been performed, a preoperative chest x ray should be reviewed to rule out relapse.

References

1. Hughes MS, Matava MJ, Wright RW, Brophy RH, Smith MV: Interscalene brachial plexus block for arthroscopic shoulder surgery. A systematic review. *Journal of Bone and Joint Surgery*; 2013;95(14):1318-24.
2. Urmeý WF, McDonald M: Hemidiaphragmatic paresis during interscalene brachial plexus block: effects on pulmonary function and chest wall mechanics. *Anesthesia and Analgesia*; 1992;74(3):352-7.
3. Urmeý WF, Talts KH, Sharrock NE: One hundred percent incidence of hemidiaphragmatic paresis associated with interscalene brachial plexus block. *Anesthesia and Analgesia*; 1991;72(4):498-503.
4. Long TR, Wass CT, Burkle CM: Perioperative

- interscalene blockade: An overview of its history and current clinical use. *Journal of Clinical Anesthesia*; 2002, 14:546-56.
5. Wennike N, Thomson A: Interscalene block as a precipitant of respiratory dysfunction. *British Journal of Hospital Medicine*; 2012;73(4):227.
6. Cangiani LH, Rezende LA, Giancoli NA: Phrenic nerve block after interscalene brachial plexus block. Case report. *Revista Brasileira de Anestesiologia*; 2008;58(2):152-9.
7. Rau RH, Chan YL, Chuang HI, Cheng CR, Wong KL, Wu KH, Wei TT: Dyspnea resulting from phrenic nerve paralysis after interscalene brachial plexus block in an obese male—a case report. *Acta Anaesthesiologica Scandinavica*; 1997;35(2):113-8.
8. Long TR, Wass CT, Burkle CM: Perioperative interscalene blockade: An overview of its history and current clinical use. *Journal of Clinical Anesthesia*; 2002;14(7):546-56.
9. Kessler J, Schafhalter-Zoppoth I, Gray AT: An ultrasound study of the phrenic nerve in the posterior cervical triangle: Implications for the interscalene brachial plexus block. *Regional Anesthesia and Pain Medicine*; 2008;33(6):545-50.
10. Riazi S, Carmichael N, Awad I, Holtby RM, McCartney CJL: Effect of local anesthetic volume (20 vs 5 ml) on the efficacy and respiratory consequences of ultrasound-guided interscalene brachial plexus block. *British Journal of Anaesthesia* 2008;101(4):549-56.
11. Lee JH, Cho SH, Kim SH, Chae WS, Jin HC, Lee JS, Kim YI: Ropivacaine for ultrasound-guided interscalene block: 5ml provides similar analgesia but less phrenic nerve paralysis than 10 ml. *Canadian Journal of Anaesthesia*; 2011;58(11):1001-6.
12. Urmey WF, Grossi P, Sharrok NE, Stanton J, Gloeggler PJ: Digital pressure during interscalene block is clinically ineffective in preventing anesthetic spread to the cervical plexus. *Anesthesia and Analgesia*; 1996;83(2):366-70.
13. Lumb AB, Nunn JF: Respiratory function and ribcage contribution to ventilation in body positions commonly used during anesthesia. *Anesthesia and Analgesia*; 1991;73(4):422-6.
14. Kulkarni ML, Sneharoop B, Vani HN, Nawaz S, Kannan B, Kulkarni PM: Eventration of the diaphragm and associations. *Indian Journal of Pediatrics*; 2007;74(2):202-5.
15. Versteegh MIM, Braun J, Voigt PG, Bosman DB, Stolk J, Rabe KF, Dion RAE: Diaphragm plication in adult patients with diaphragm paralysis leads to long-term improvement of pulmonary function and level of dyspnea. *European Journal of Cardiothoracic Surgery*; 2007;32(3):449-56.

Author Information

Xi Chen, MD, PhD.

Department of Anesthesiology, University of Toledo Medical Center
Toledo, OH
Xi.chen2@utoledo.edu

Shashi B. Bhatt, MD, FRCA

Department of Anesthesiology, University of Toledo Medical Center
Toledo, OH
Shashi.bhatt@utoledo.edu

Kimberly D. Jenkins, MD

Department of Anesthesiology, University of Toledo Medical Center
Toledo, OH
Kimberly.jenkins2@utoledo.edu