

Obesity Does Not Affect The Accuracy of Acetabular Cup Implantation in Total Hip Replacement

M Todkar

Citation

M Todkar. *Obesity Does Not Affect The Accuracy of Acetabular Cup Implantation in Total Hip Replacement*. The Internet Journal of Orthopedic Surgery. 2006 Volume 6 Number 1.

Abstract

Post-operative radiographs of 111 patients who had undergone cemented Total Hip Replacement performed or supervised a single surgeon (GCF) were analysed. All surgeries were performed via an anterolateral approach with patients in the lateral position. Patients were stratified according to Body Mass Index (BMI) into three groups (healthy, overweight and obese) and acetabular cup angles measured.

Mean values for cup abduction angle were similar for all three groups (44.5°, 46.8°, 44.0° respectively, $p=0.335$). Furthermore there were no differences in mean cup anteversion between groups (11.6°, 12.2°, 10.7° respectively, $p=0.665$). We conclude that obesity does not influence the accuracy of cup positioning in Total Hip Replacement.

INTRODUCTION

Total hip replacement is one of the most commonly performed adult reconstructive procedures that provides pain relief, functional improvement and improved quality of life for thousands of patients each year worldwide ¹. The accuracy of implantation of total hip replacement (THR) components is fundamental to the function, stability and the longevity of the implants ^{2,3,4}. Whilst the components are inserted as accurately as possible with reference to anatomical landmarks and various intra-operative guides, their position is subject to variation and surgical error ^{5,6}.

Total hip arthroplasty is performed with the patient in a supine or lateral decubitus position. When performed with the patient in the lateral position the pelvis can rotate making positioning of acetabular component more difficult ⁷ with some studies citing a tendency to position the cup in less than ideal anteversion ⁸ and a more abducted or open position ³. Some surgeons believe that obese patients are more likely to be positioned incorrectly on the operating table and therefore the accuracy of implantation of their acetabular components is subjected to greater error.

The purpose of present study is to determine if obesity affects cup anteversion and abduction angle in THR.

MATERIALS AND METHODS

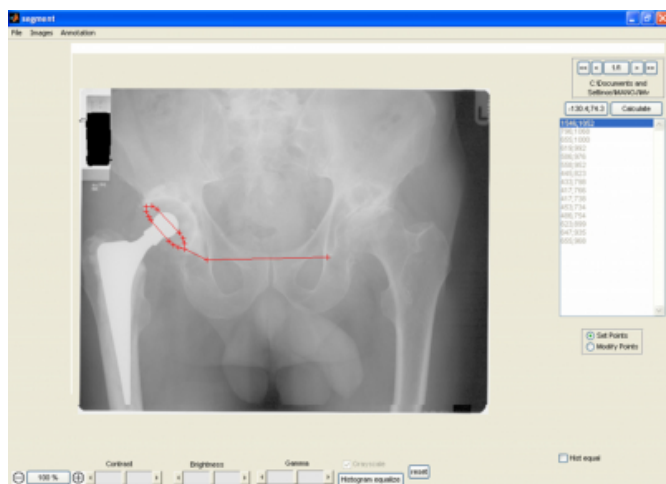
Between 1996 and 2005 two hundred and one Total Hip Replacements using the ZCA® cemented acetabular cup (Zimmer, Warsaw) were reviewed retrospectively. All surgeries were performed or supervised by a single surgeon (GCF). All cases were performed with the patient in the lateral position via an antero-lateral approach and the same bone cement (Palacos®, Zimmer, Warsaw) was used in each case. Of these patients 111 were considered to have sufficiently good quality antero-posterior pelvic or hip postoperative X-Rays available for analysis of cup anteversion and 72 of these patients had antero-posterior pelvic radiographs for measurement of cup abduction. Abduction angle of acetabular cup is the angle between a horizontal reference line (line joining inferior teardrop points or inferior pubic rami or inferior points on sacroiliac joint) and the axis of opening of acetabular cup. On the radiographs of one hip joint the reference line cannot be drawn and abduction angle cannot be measured.

All radiographs were scanned to provide high definition TIFF images and the abduction and anteversion angles were measured using MATLAB® software (The MathWorks, Inc., USA). Cup anteversion angles were measured on either an AP radiograph centered on the hip (111 cases) or on an AP pelvic X-ray (72 cases). An ellipse of best fit was plotted onto the radio opaque wire marker of the acetabular cup and

the anteversion angle was then calculated using the software 10*11*12. A correction factor of 4 degrees was added for anteversion angles measured when pelvic radiographs centred on the pubis symphysis were used as described by Widmer 13.. For the cases with pelvic radiographs abduction angle was calculated by plotting a horizontal reference line between the most inferior point of the acetabular teardrops. The cup inclination or abduction angle was then calculated as the angle between a line through the long axis of the ellipse and the horizontal reference line (Figure 1).

Figure 1

Figure 1: Measurement of inclination and anteversion angles



Patients were stratified into groups for Body Mass Index according to the World Health Organisation Classification of obesity 9. All measurements of BMI were taken less than two weeks pre-operatively. Patients were categorised as: healthy weight (BMI 18.5-24.9), overweight (BMI 25.0-29.9), grade I obese (BMI 30.0–34.9), grade II obese (BMI 35.0–39.9) or grade III obese (BMI ≥40.0). The number of patients who were grade II or grade III obese were small and considered too small for statistical analysis therefore they were grouped with the grade one obese group leaving three study groups – healthy (BMI 18.5-24.9), overweight and obese (BMI ≥30.0).

Of the 111 patients analysed thirty-nine patients were in the healthy weight category, 49 were overweight and 23 were obese (16 grade I obese, 6 grade II obese and 1 grade III obese). Of the 72 patients who had AP pelvic X-Rays to determine cup abduction angle 26 patients were in the healthy weight category, 30 were overweight and 16 were obese (9 grade I obese, 6 grade II obese and 1 grade III obese).

A power calculation was performed which calculated that 7 patients were required in each group to detect a difference of

10 degrees based on a power of 95% and a probability of 0.05 of a Type I error

Statistical analysis was performed using SPSS® (version 13). Differences in mean cup abduction and anteversion angles between groups were sought using analysis of variance (ANOVA) with the Bonferroni correction for multiple comparisons. The significance level was set at 0.05.

RESULTS

Characteristics of the study groups are outlined in Table 1.

Figure 2

Table 1: Characteristics of the study groups.

	Healthy (n=39)	Overweight (n=49)	Obese (n=23)
Mean age (range)	72.6 (55–87)	71.1 (55–85)	68.1 (59–87)
Male: Female	17:22	26:23	7:16
Left: Right side	20:19	24:25	10:13
Mean BMI (range)	22.6 (18.9 – 24.9)	27.1 (25.0– 29.9)	33.4 (30.0 – 48.1)

For all 111 patients in the study the mean cup anteversion angle was $11.7 \pm 6.7^\circ$ sd (range 1.8° to 34.2°). For the 72 patients who had pelvic radiographs centered on the symphysis mean cup abduction angle was $45.4 \pm 7.2^\circ$ sd (range 27.1° to 66.0°).

Neither the cup abduction angle nor the anteversion angle was influenced by BMI (Table 2). Mean cup anteversion angle was 11.6° for the healthy group, 12.2° for the overweight group and 10.7° for the obese group ($p=0.665$). Mean cup abduction angle was 44.5° for the healthy group, 46.8° for the overweight group and 44° for the obese group ($p=0.335$).

Figure 3

Table 2: Mean cup abduction and anteversion angles according to BMI

Grade of obesity	Cup abduction angle (sd)	Cup anteversion angle (sd)
Healthy	$44.5^\circ (7.7^\circ)$	$11.6^\circ (6.6^\circ)$
Overweight	$46.8^\circ (6.7^\circ)$	$12.2^\circ (6.9^\circ)$
Obese	$44.0^\circ (7.3^\circ)$	$10.7^\circ (6.8^\circ)$
p	0.335	0.665

DISCUSSION

The accuracy of implantation of components in Total Hip Replacement is paramount to the success of the procedure. The orientation of the acetabular component affects the longevity of the prosthesis; wear of the bearing surfaces and dislocation rate 2,3. Ideally the acetabular component should

be implanted with an inclination angle of 35 - 45° and an anteversion angle of 0 - 15°¹⁴. Acetabular cups are implanted with the aid of intra-operative alignment guides and the accuracy of implantation depends on the proper positioning of the patient and anatomical landmarks. The pelvis rotates intra-operatively with retraction of soft tissues and femur⁷. It has been postulated that in obese patients proper positioning of the patient upon the operation table is difficult and more retraction of soft tissues and the femur is required for visualisation of the acetabulum.

The aim of the present study was to determine if the accuracy of implantation of cemented acetabular component in total hip replacement is influenced by obesity. This study suggests that obesity has no effect on the accuracy of acetabular component implantation in total hip replacement.

All 111 patients in the present study were operated by or under direct supervision of a single surgeon in the lateral position through anterolateral approach to the hip joint. The same acetabular component and bone cement was used in all the patients. Single observer took all the observations. The observer was blinded while measuring the angles from the radiographs using software.

The present study demonstrates that the obesity does not affect implantation of acetabular component in total hip replacement. Although patient positioning and adequate exposure of the acetabulum may be more difficult in the obese patient it is likely that the operating surgeon takes greater care in positioning the obese patient and in implanting the cup thus maintaining the accuracy of cup implantation.

Of the 23 patients in the Obese group 16 patients were grade one obese, 6 were grade two obese and 1 was grade three obese. The number of patients who were grade 2 and 3 obese were too small for statistical analysis and these patients were therefore grouped with grade 1 obese patients. This study has not addressed whether higher grades of obesity affect the accuracy of cup implantation. We would suggest that this could be an area for further work.

The present study shows that obesity does not affect orientation of acetabular component in total hip replacement however extra care may be required during patient set-up, exposure and cup implantation during Total Hip Replacement.

References

1. Paprosky WG, Sporer SM: Biologic fixation and bone ingrowth. *Orthop Clin North Am*; 36:105-111, 2005.
2. Fackler C, Poss R. Dislocation in total hip arthroplasties. *Clin Orthop*; 151:169-178, 1980
3. Woo R, Morrey B: Dislocations after total hip arthroplasty. *J Bone Joint Surg*; 64-A:1295-1306, 1982.
4. Wolf A, DiGioia A, Mor A, Jaramaz B. A kinematic model for calculating cup alignment error during total hip arthroplasty. *J Biomech*; 38(11):2257-65, 2005.
5. Hassan D, Johnston G, Dust W. Accuracy of intra-operative assessment of acetabular prosthesis placement. *J Arthroplasty*; 13:80-84, 1998.
6. Jaramaz B, DiGioia A, Blackwell M, Nikou C. Computer assisted measurement of cup placement in total hip replacement. *Clin Orthop*; 354:70-81, 1998.
7. Masamitsu E, Masatoshi N, Asayama, Toshiyuki I, Fujisawa: Pelvic motion during total hip arthroplasty with translateral and posterolateral approaches. *Journal of Orthopaedic Science*; 10:167-172, 2005.
8. McCollum BJ, Gray WJ: Dislocation after total hip arthroplasty: Causes and prevention. *Clin Orthop*; 261:159, 1990.
9. Obesity: preventing and managing the global epidemic: report of a World Health Organization Consultation of Obesity, Geneva, 1997. Geneva, World Health Organization, 1998.
10. Kerrigan S, Ricketts IWR, McKenna S, Wigderowitz CA. Measurement of acetabular wear using intelligent ellipses. *British Orthopedic Research Society*; 35, Sept. 2002.
11. Kerrigan S, McKenna S, Ricketts I, Wigderowitz C. Analysis of total hip replacements using active ellipses. In *Medical Image Understanding and Analysis*, pp. 177-180. Sheffield, 2003.
12. Kerrigan S, McKenna S J, Ricketts IW, Wigderowitz CA. Eccentricity error correction for automated estimation of polyethylene wear after total hip arthroplasty. *Medical Image Understanding and Analysis (MIUA)*, Bristol, 255-258, 2005.
13. Widmer KH: A simplified method to determine acetabular cup anteversion from plain radiographs. *J Arthroplasty*; 19:387-390, 2004.
14. Kummer F, Shah S, Iyer S, DiCesare P. The effect of acetabular cup orientations on limiting hip rotation. *J Arthroplasty*; 14(4): 509-13, 1999.
15. Ackland MK, Bourne WB, Uhthoff HK. Anteversion of the acetabular cup: measurement of angle after total hip replacement. *J Bone Joint Surg*; 68-B: 409-413, 1986.

Author Information

Manoj Todkar, MS, DNB, MNAMS, MRCS, MCh, FICS

Consultant arthroplasty and arthroscopy surgeon, Dr Todkar Hospital