

A Distressing Complication in PACU after Ventriculoperitoneal Shunt Externalization

O Cok, H Eker, S Akin, A Aribogan

Citation

O Cok, H Eker, S Akin, A Aribogan. *A Distressing Complication in PACU after Ventriculoperitoneal Shunt Externalization*. The Internet Journal of Anesthesiology. 2007 Volume 16 Number 1.

Abstract

Accurate knowledge and intense care are required for early detection of complications in all stages of anesthesia. Here, we present a three-year old boy who lost consciousness in post-anesthesia care unit after ventriculoperitoneal shunt externalization and discuss the possible causes and immediate treatment. We suggest that an anesthetist should be aware of post-anesthetic early complications, but also he should be ready for outcomes of a controversial surgical procedure.

To the Editor:

The incidence of adverse events in postanesthesia care unit (PACU) exceed 10% to 18% and these complications may be related either anesthesia or surgery, or both (1). Also the type of surgery has a considerable impact on the overall incidence of PACU complications and, here, we present a case of postoperative loss of consciousness in the PACU following a neurosurgical intervention.

Three-year old boy was admitted to hospital with headache, nausea and vomiting. He had a ventriculoperitoneal shunt placed when he was 6 months old. An increase in intracranial pressure (ICP) was suspected in his physical examination, but MRI findings and a low cerebrospinal fluid (CSF) pressure revealed that ICP was below normal level. Pediatric neurologist referred the patient to neurosurgery department for ventriculoperitoneal shunt externalization and ICP management. The anesthetic plan was local anesthesia with midazolam sedation. Shunt was externalized and the drainage was stopped in the operation. After an uneventful intraoperative period, child was completely awake when he was transported to recovery area. His sedation recovery score was 19 according to Vancouver Sedative Recovery Scale for Children (2), which has the highest score as 22, at arrival to the recovery room. After 30 minutes in PACU, child lost consciousness suddenly and his respiration became shallow, his recovery score was 5. Then his ventilation was supported with a closed face mask and flumazenil 0.5 mg was administered immediately to rule out a prolonged sedation because of midazolam, but no recovery was observed. Arterial blood gases and glucose

concentration assessed immediately was in normal limits.

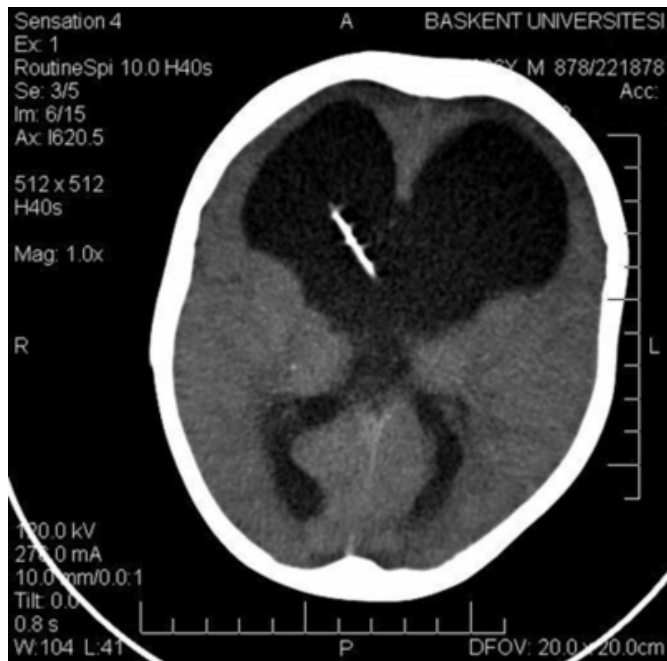
Simultaneous neurological examination revealed dilatation of both pupils to suspect a possible elevation in ICP.

Mannitol (0.5 g/kg) and furosemide (0.5 mg/kg) treatment started immediately for ICP management and thereafter an emergency CT scan was planned for diagnosis. Patient was then intubated to maintain hyperventilation and to ensure the safety of airway during transport. CT scan revealed an acute increase in ICP (Figure 1) and ventriculoperitoneal drainage was started again and 70 ml CSF was drained rapidly.

Patient recovered subsequently and extubated successfully in the intensive care unit.

Figure 1

Figure 1: Axial non-contrast enhanced computed tomography image shows enlarged lateral ventricles and ventricular shunt catheter



Anesthetists sometimes may have to participate in a surgical

procedure although the operation decision is controversial or inappropriate for the patient's actual condition. However anesthetist's responsibility for a patient continues until discharge in general means. But the period in the recovery room is especially important to notice possible early complications and to manage the problem without delay. These complications may include inadequate recovery from anesthesia, seizures, electrolyte imbalance, hypoglycemia and surgical complication as an anticipated ICP elevation as a result of the operation in this case. As loss of consciousness after recovery following an operation remains challenging, anaesthetic complications must always be ruled out as surgical causes are investigated concurrently. We suggest that an anesthetist should be aware of post-anesthetic early complications, but also he should be ready for outcomes of a controversial neurosurgical procedure.

References

1. Tarrac SE. A description of intraoperative and postanesthesia complication rates. *J PeriAnesthesia Nursing* 2006; 2: 88-96.
2. Macnab AJ, Levine M, Glick N, Susak L, Baker-Brown G. A research tool for measurement of recovery from sedation: the Vancouver Sedative Recovery Scale. *J Pediatric Surg* 1991; 26: 1263-1267.

Author Information

Oya Yalcin Cok, MD

Department of Anesthesiology and Reanimation, Faculty of Medicine, Baskent University

H. Evrin Eker, MD

Department of Anesthesiology and Reanimation, Faculty of Medicine, Baskent University

Sule Akin

Assistant Professor, Department of Anesthesiology and Reanimation, Faculty of Medicine, Baskent University

Anis Aribogan

Professor, Department of Anesthesiology and Reanimation, Faculty of Medicine, Baskent University