

Atopic Dermatitis

J Spergel, L Schneider

Citation

J Spergel, L Schneider. *Atopic Dermatitis*. The Internet Journal of Asthma, Allergy and Immunology. 1998 Volume 1 Number 1.

Abstract

Correspondence to:

Lynda C. Schneider, M.D.

Division of Allergy and Immunology

Children Hospital

300 Longwood Avenue

Boston, MA 02115

617-355-6180

INTRODUCTION

Atopic dermatitis (AD) is a chronic inflammatory skin disorder. Like other allergic diseases, the prevalence of atopic dermatitis appears to be rising. In children, the prevalence of AD has increased from 3 -4% in the 1960's to 10-15% in the 1980's. But unlike many other diseases, AD has no primary skin lesions or pathognomonic test. Therefore, the diagnosis of atopic dermatitis has to be made by constellation of physical findings (Table 1). The major features include pruritis, typical morphology and distribution of the lesions. The skin distribution varies with age. In infancy, the face and extensor surfaces of the arms and legs are most commonly affected. Infantile AD may resolve spontaneously or continue into the childhood phase, which is characterized by pruritic papules, xerosis, and lichenification. In the older child and adults, a scaly and lichenified dermatitis on the flexor surfaces of the extremities, neck, and upper trunk is observed. Over 85% of AD presents during the first five years of life, and rarely occurs after 45 years of age .

DIFFERENTIAL DIAGNOSIS

The differential diagnosis of AD includes a number of eczematous dermatitides including contact dermatitis, seborrheic dermatitis, fungal infections, and drug eruptions. In infancy, psoriasis, scabies, Netherton's syndrome, ectodermal dysplasia, Hyper IgE syndrome, Wiskott-Aldrich

syndrome and other immunodeficiencies, and enzyme deficiencies (e.g. phenylketonuria) must also be considered in the differential diagnosis.

HISTOLOGY

The histopathologic changes in atopic dermatitis are nonspecific. Acute lesions, characterized by intensely pruritic, erythematous papules, reveal mild epidermal hyperplasia, intercellular edema of the epidermis (spongiosis), and infiltration of lymphocytes and macrophages along the venous plexus in the dermis. In chronic AD, characterized by lichenification and fibrotic papules, there is increased hyperplasia and hyperkeratosis of the epidermis, and a persistent dermal inflammatory cell infiltrate with lymphocytes and macrophages, as well as increased mast cells and Langerhans cells. Even though, there are few eosinophils seen in the lesions, deposition of the eosinophil granular protein major basic protein (MBP) in large quantities has been observed on immunofluorescent staining of chronic AD skin indicating an role for eosinophils in AD. Recent work has further demonstrated that eosinophils undergo cytolytic degeneration leading to release of granule proteins in lesions of AD .

Immunohistological analysis of skin lesions in AD reveals a mononuclear cell infiltrate, predominantly in the dermis, consisting of activated memory CD4+ T cells bearing HLA-DR+ and CD45RO+ and of macrophages . The mast cell seen in the lesions are MT-type, which may be dependent on T cell for development. Vascular endothelial cells in AD skin lesions have increased expression of the adhesion molecules E-selectin, VCAM-1 and ICAM-1. These adhesion molecules are important for homing of T cells and eosinophils observed in these lesions.

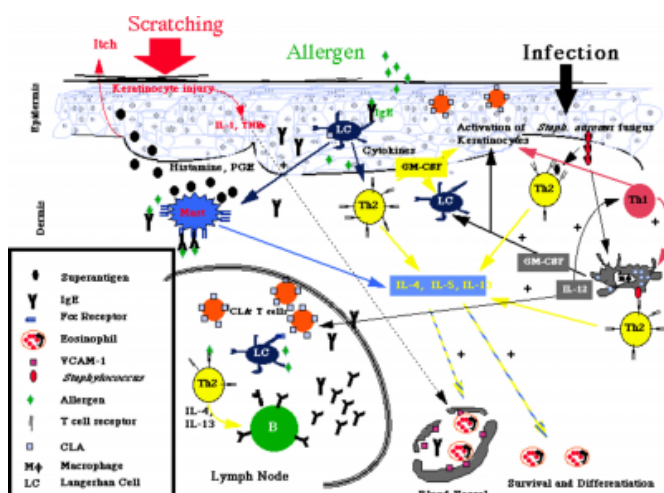
PATHOGENESIS

Genetic and environmental factors induce a complex series

of cellular interactions leading to the symptoms and signs of AD. One potential scenario is that Langerhans cells, which are surface IgE positive, present antigen to T cells leading to their activation and release of cytokines, i.e. IL-1, IL-6 and TNF- α . Simultaneously, physical trauma (scratching) causes the keratinocytes to secrete similar cytokines, which in turn attract and activate CD4+ T lymphocytes. Mast cells are also present and upon activation by cross-linking of IgE or other mechanisms, can release histamine and mediators upregulating adhesions molecules, which in turn may recruit additional inflammatory cells including T cells and eosinophils.

The T cells appear to play a central role in the process. T-cells infiltrating the skin lesion express high levels of cutaneous lymphocyte antigen (CLA), which functions as a skin homing receptor for T lymphocytes by binding to E-selectin. Analysis of skin biopsies by in situ hybridization reveals that AD skin lesions had significantly greater numbers of cells that are positive for mRNA for IL-4, IL-5 and IL-13. Consistent with this result, studies have found the expression of IL-4 and decreased IFN- γ expression was more pronounced in allergen-specific T cells for stimulated by various allergens including that Dermatophagoides pteronyssinus and Lolium perenne (group I grass pollen allergen). Additionally, PBMC show increased IL-5 expression and TH2-like phenotype in CD4+ and CD8+ cells in patients with AD. However, the frequency of these allergen specific T cells that proliferate to Dermatophagoides pteronyssinus are between 0.02 and 0.7% suggesting AD lesions also contains non-specific inflammatory cells.

Figure 1



Recent studies, however, have revealed that in the chronic

eczematous AD skin lesions, the expression of the TH-1 cytokine, IFN- γ predominates compared to TH2 phenotype in the acute lesions. This has also been confirmed by patch testing, when the majority of T cells were found to express IFN- γ mRNA and to secrete IFN- γ protein, either alone or in combination with IL-4 in late lesions. These results suggest that the chronic lesions are not completely TH2, but more likely a combination of TH2 and TH1 phenotypes.

The patterns of cytokine secretion are particularly important because of the known effects of the cytokines. The activated TH2 cells are seen in the acute lesions and probably in the chronic lesions and secrete IL-3, IL-4, IL-5, IL-6, IL-10, IL-13 and GM-CSF. These cytokines promote B cell responses, upregulation of IgE receptors on Langerhans cells and downregulation of TH1 activity and IL-1 receptors on monocytes. The latter effects may account for the lack of delayed-skin reactivity and the cutaneous anergy seen in most patients with AD. Two cytokines have critical roles, IL-4 for in vitro IgE synthesis, and IL-5 promotes the in vitro differentiation and survival of eosinophils. IL-4 can activate keratinocytes, which in turn have enhanced ability to stimulate T cells.

The role of IFN- γ in AD is more controversial. IFN- γ is decreased in many studies but is seen in biopsy of chronic lesions. It is possible to postulate that IFN- γ is increased locally and decreased peripherally. This would be consistent with the studies that found decreased IFN- γ production in PHA stimulated culture supernatants leading to increased IgE. IFN- γ may have a role in the chronic lesions by activating neutrophils, macrophages, endothelial and epithelial cells and fibroblasts and induce expression of HLA-DR on keratinocytes. Keratinocytes production of GM-CSF may also contribute to the establishment and chronicity of AD lesions, in particular to increased number, sustained activation, and enhanced antigen-presenting functions of dendritic cells. Therefore, the pattern of cytokines expressed locally is critical in modulating the nature, extent and persistence of the inflammation in AD. Another mechanism for the persistent inflammation is enhanced survival of inflammatory cells. Cultures of peripheral blood mononuclear cells (PBMC) from patients with AD had less spontaneous apoptosis in comparison to normal donors.

IMMUNOLOGIC ABNORMALITIES

Further evidence for the role of T cells and immune system playing a crucial role in the pathogenesis of AD comes from

clinical observations seen in majority of AD patients: elevated IgE and impaired cell-mediated immunity. The importance of IgE-mediated hypersensitivity is suggested by the clinical findings: (a) most AD patients have significantly elevated IgE levels (b) allergens exacerbate AD and (c) a personal or family history of atopic disease is usually present.

Defective cell-mediated immunity (CMI) may be noted in up to 80 percent of patients with AD, manifested by increased susceptibility to severe skin infections with viruses (herpes simplex, vaccinia, Coxsackie A16); increased susceptibility to chronic dermatophyte infections; a decreased susceptibility to specific contact allergens; and decreased responsiveness to delayed type hypersensitivity skin testing. The immunological basis for this observation may be from the increased number of TH-2-like clones found in AD. A minority of TH-2 clones exhibit cytolytic activity in a 4 h PHA-dependent assay whereas as a majority of TH-1 clones (77%) exhibit cytolytic activity.

Analysis of patients with AD for a unifying immunological abnormality that would make them susceptible to AD has not been found. Nevertheless, some consistent results include that the majority of patients with AD have a decreased proportion of circulating CD3 + T cells and CD8+ suppressor T cells. In contrast, patients with allergic rhinitis, asthma, and other diffuse skin diseases not related to atopy (such as psoriasis or contact dermatitis) did not have a reduction of circulating suppressor/cytotoxic T cells. AD patients have decreased chemotactic response to IL-8 which might account for increased cutaneous infections or defective CMI seen in AD.

ANATOMICAL CHANGES

A number of skin abnormalities have been found in atopic dermatitis such as increased transepidermal water loss, decreased sebum production, and altered fatty acid content of the sebum. These factors contribute to the dry, itchy skin.

Abnormal cutaneous vascular responses are observed. A vasoconstrictor mechanism is thought to be responsible for the white dermatographism, delayed blanch to cholinergic stimuli, and paradoxical response to nicotinic acid observed in AD patients. Consistent with this result, low cyclic AMP (cAMP) levels were found in AD leukocytes.

INFLAMMATORY CELLS AND MEDIATORS

The local synthesis of allergen specific IgE in the skin likely results in mast cell cross-linking and activation and release

of mediators. The clinical symptoms of AD (namely the itch and the eczematous lichenified skin lesions) are produced by these mediators, histamine, leukotrienes and cytokines. Evidence for the involvement of these mediators include elevated plasma and tissue histamine, increase basophil release of histamines, increased cAMP specific phosphodiesterase and elevated levels of leukotriene B₄ [30, 31] and histamine-releasing factor.

SUMMARY OF PATHOGENESIS

Genetic factors are likely responsible for a variety of dermatologic and/or immunologic abnormalities which underlie AD. The immunologic abnormalities include hypersensitivity reactions, impaired immunoregulation of IgE, increased phosphodiesterase, impaired macrophage functions and increased mast cell releasability. With appropriate allergen stimulation, mast cells release mediators which lead to itching. Additionally, antigen stimulation causes T cells to differentiate into Th2 cells and secrete cytokines leading to increased IgE and recruitment of eosinophils and other inflammatory cells. Elevated IgE and eosinophil products cause increased mast cell release of histamine and cytokines further potentiating the cycle of inflammation. The physical trauma of itching results in IL-1 and IL-3 secretion by keratinocytes; activation of Langerhans cells leading to secretion of IL-1, TNF- α , platelet activating factor and histamine releasing factor and additional activation of T cells, which further perpetuate the reaction.

TRIGGERS OF AD

Many factors exacerbate AD. The atopic skin is associated with a lowered threshold of irritant responsiveness and pruritus. Common triggers include: irritants, dry skin (xerosis), infections, allergens, sweating, changes in temperature, illness or fatigue, and emotional stress. Important irritants in atopic dermatitis are wool and acrylic in clothing, perfumes and perfumed products, cosmetics, soaps, cleaning agents, alcohol containing products, sand, tobacco smoke, paint, chlorine in swimming pools, and citrus foods.

The mechanism of how infections can exacerbate AD is becoming clearer by several studies on staphylococcus aureus. Over 90% of patients with AD are colonized with Staph aureus. Recent studies suggest that Staph. aureus can exacerbate or maintain skin inflammation in AD by secreting a group of toxins known to act as superantigens which stimulate significant percentage of T cells and macrophages.

Nearly half of AD patients produce IgE directed to staphylococcal toxins, particularly SEA, SEB, and Toxic shock syndrome toxin-1 (TSST-1). Staphylococcal superantigen have been demonstrated to induce T cell expression of the skin homing receptor (CLA) through stimulation of IL-12 production. IL-12 can be secreted by Langerhans and T cells. Further evidence is T cells from patients with atopic dermatitis have preferential expression of a particular T cell heavy chain receptor β 3, 8 and 12, which can be stimulate by staphylococcus superantigens to increase IL-5 production and T cell proliferation thus modulating tissue inflammation . These studies indicate that AD patients have greater potential to react and generate inflammation to staphylococcal infections. Additionally, basophils from AD patients who produce IgE anti-toxin, release histamine on exposure to the relevant exotoxin. These findings suggest the possibility that local production of staphylococcal exotoxins at the skin surface could cause IgE-mediated histamine release and thereby trigger the itch-scratch cycle which can exacerbate AD.

Other infections that worsen or seen in AD include eczema herpeticum (disseminated Herpes simplex virus) and superficial fungal infections. *Pityrosporum ovale* as well as other fungi have been found in patients with AD. Similar to staphylococcal proteins, specific IgE to *pityrosporum ovale* has been described. *Pityrosporum orbiculare* like aeroallergens can cause proliferation of T cell clones and increased production of TH2-like cytokines. Reduction in AD severity is seen following treatment with antifungal agents. . Fujimura and colleagues recently reported a case of severe AD resolving after a varicella infection with a switch of PBMC phenotype from TH2 to TH1. It is possible that virus infections or dendritic cells could induce IL-12 causing the switch from TH2 to TH1.

In some cases, foods or inhalants (e.g. dust mites, pollens, animals) are important allergic triggers. Mites and other allergens trigger T cells from AD patients to secrete increased IL-4 and decreased IFN- γ leading to exacerbation of AD as described in detail above. Although allergens are significant triggers of AD, interpretation of positive RAST tests and skin tests is difficult because false positives occur. Sampson studied 113 children with severe atopic dermatitis by double blind placebo controlled food challenges. Although the patients had multiple positive skin and RAST tests, 90% of patients reacted on challenge to only one or two foods. Egg, peanut, milk, soy, wheat, and fish accounted for the majority of the reactions . Patients with AD and food

hypersensitivity have a higher a rate of spontaneous release of histamine from basophils than controls. Mononuclear cells from food allergic patients produced a histamine-releasing factor that provoked the release of histamine from basophils of other food allergic patients but not from normal subjects. Allergen avoidance for one year lead to a decrease in basophil histamine release and mononuclear cell HRF production.

Additional evidence that allergens are important triggers of atopic dermatitis comes from the work examining the role of mite in AD. Delayed cutaneous testing and inhalation challenge with aeroallergens have identified mite, ragweed and mold causing flares of atopic dermatitis in subset of patients . Avoidance of these patch test positive aeroallergens resulted in improvement or resolution of dermatitis. This study was recently confirmed on a larger scale of 48 patients in avoidance of house dust mite allergen. They found that the active avoidance showed significantly greater improvements in severity score and body surface area affected than the control group .

MANAGEMENT OF AD

1. Moisturizers are the first line of topical therapy for AD, and are important to reduce and prevent the dry itchy skin of AD. Petroleum products such as Vaseline or hydrated petrolatum are the best moisturizers. Non-perfumed skin creams can also be effective. Moisturizers should be applied to the skin immediately after a tepid bath (while the skin is still moist).
2. Tar preparations may act as antipruritics, disinfectants, antiinflammatory and desquamating agents when put in the bath or applied topically, and are often beneficial in both the acute and chronic phases of AD.
3. Avoidance of irritants is crucial to controlling AD. A mild non-perfumed soap should be used and excessive scrubbing should be avoided. All cotton clothing and bedding are less irritating than synthetic or wool fabrics.
4. In a subset of patients with atopic dermatitis, allergens can trigger a flare of AD should be avoided. However, diagnosis of food or inhalant allergies in patients with atopic dermatitis can be difficult since skin testing may yield false positive results. In order to clarify whether a food is a

trigger for atopic dermatitis, double blind placebo controlled food challenges or elimination diets are required. Additionally, some recent studies have demonstrate that food allergen avoidance in neonates from families with a history of atopy will prevent some cases of AD .

5. Infections can worsen AD, and should be treated early with topical and/or oral antibiotics, antifungals, or anti-viral agents. Early *Staphylococcus aureus* infections can be treated with topical antibacterial agents such as mupirocin (Bactroban®). For more widespread infection, oral anti-Staphylococcal agents such as dicloxacillin, erythromycin, or cephalexin should be prescribed. Intravenous or oral anti-viral agents are beneficial in decreasing severity and duration of the eruption and should be used for eczema herpeticum.
6. Emotional stress can exacerbate atopic dermatitis. Children with AD often have disrupted sleep and daytime behavioral difficulties associated with insufficient sleep. Also, AD patients were more depressive and psychomatic-prone than normal controls and suggest that some patients with atopic dermatitis should be treated both dermatologically and psychiatrically . Hypnotherapy has been useful for some patients with intense pruritus and sleep abnormalities. In addition, the intense itching and skin appearance can lead to stress for the family and patient. Lay organizations such as the Eczema Association for Science and Education (EASE), the Food Allergy Network, and the Asthma and Allergy Foundation of America (AAFA) provide patients with information and support. This is emphasized by an enlightening piece written by Irene Crosby entitled “My skin is only the top layer of the problem”.
7. Topical steroid ointments or creams are needed for acute flares of atopic dermatitis. Topical steroids should not be the sole treatment for atopic dermatitis, but should be used in conjunction with other forms of therapy, especially emollients. For acute flares a potent topical steroid, such as the diflorinated or the fluorochlorinated preparations, should be used for 7 to 10 days and then replaced with a low to midpotency topical steroid for 2 to 3 weeks until the lesions have resolved. Severely affected patients may require chronic use of a low potency topical steroid in conjunction with lubricants. Fluorinated steroids should not be chronically applied to the face, genitals, axillae, inguinal region, or skin folds and they should not be used in infants. Excessive or prolonged use of high potency topical steroids can lead to local atrophy. Significant systemic absorption is a potential hazard of topical steroids.
8. Antihistamines may be helpful especially at night to control the itching associated with atopic dermatitis. Hydroxyzine or cetirizine and diphenhydramine are frequently prescribed. Nonsedating antihistamines such as astemizole, loratidine, terfenadine occasionally provide relief for patients. Topical doxepine has recently been shown to be effective in reducing pruritis in AD, however, may cause localized stinging and drowsiness. Topical diphenhydramine should be avoided because of low efficacy and high likelihood of skin sensitization.
9. In spite of the above therapies, some patients have recalcitrant or severe AD. For such patients with severe disease, short term phototherapy using ultraviolet radiation (UVB or PUVA) is often beneficial . However, the usefulness of this therapy is limited by the long term risks, inconvenience and expense. A recent study has shown that cyclosporin (5 mg/kg per day) is an effective short term therapy for refractory AD. Recombinant IFN- γ has shown promising preliminary results for patients with severe AD and may be appropriate for chronic therapy. [. Recent trials of topical tacrolimus (FK-506) ointment have shown promising results and additional studies are now underway . As the immunology of atopic dermatitis is better understood, specific cytokine or cytokine receptor antagonists may be important therapies for severe disease.

SUMMARY

In summary, AD is a disorder that affects about 10% of the population and creating stress for the patient and family from sever pruritus and significant skin findings. IgE-mediated immediate and cellular responses have a major role in pathogenesis. However, the exact pathogenesis is unknown, hopefully through the use of three recent murine models, we will begin to have better understanding the

disease and develop a better treatment and cure. Until that point, a comprehensive approach in management and treatment should be used.

TABLE 1. ATOPIC DERMATITIS DIAGNOSTIC CRITERIA

MUST HAVE 3 OR MORE MAJOR FEATURES

- 1. Pruritis
- 2. Typical morphology and distribution:
 - a. Flexural lichenification or linearity in adults
 - b. Facial and extensor involvement in infant and children
- 3. Chronic or chronically relapsing dermatitis
- 4. Personal or family history of atopy (asthma, allergic rhinitis, AD)

PLUS 3 OR MORE MINOR FEATURES

1. Xerosis
2. Ichthyosis/ Palmar hyperlinearity/ Keratosis pilaris
3. Immediate (type I) skin test reactivity
4. Elevated serum IgE
5. Early age of onset
6. Tendency toward cutaneous infection/ impaired cell-mediated immunity
7. Tendency toward nonspecific hand or foot dermatitis
8. Nipple eczema
9. Cheilitis
10. Recurrent conjunctivitis
11. Dennie-Morgan infraorbital fold
12. Keratoconus
13. Anterior subcapsular cataracts
14. Orbital darkening
15. Facial pallor / facial erythema
16. Pityriasis alba

17. Anterior neck folds
18. Itch when sweating
19. Intolerance to wool and lipid solvents
20. Perifollicular accentuation
21. Food allergy
22. Course influenced by environmental / emotional factors
23. White dermatographism / delayed blanch

TABLE 2. ATOPIC DERMATITIS IN INFANCY DIAGNOSTIC CRITERIA

MAJOR FEATURES:

1. Pruritic dermatitis
2. Typical facial or extensor eczematous or lichenified dermatitis
3. Family history of atopy (asthma, allergic rhinitis, AD)

MINOR FEATURES

1. Xerosis/Ichthyosis/hyperlinear palms
2. Perifollicular accentuation
3. Chronic scalp scaling
4. Peri-auricular fissures

References

- r-0. 1. Larsen, F., N. Holm, and K. Henningsen, Atopic dermatitis: a genetic-epidemiologic study in a population-based twin sample. *J Am Acad Dermatol*, 1986. 15: p. 487-496.
- r-1. 2. Hanifin, J. and G. Rajka, Diagnostic features of atopic dermatitis. *Acta Derm Venereol*, 1980. 92: p. 44-47.
- r-2. 3. Leung, D., et al., Atopic Dermatitis, in *Dermatology in General Medicine*, T. Fitzpatrick, et al., Editors. 1993, McGraw-Hill, Inc.: New York. p. 1543-1563.
- r-3. 4. Leiferman, K., S. Ackerman, H. Sampson, H. Haugen, P. Venencie, and G. Gleich., Dermal deposition of eosinophil-granule major basic protein in atopic dermatitis: comparison with onchocerciasis. *N Engl J Med*, 1985. 313: p. 282-285.
- r-4. 5. Cheng, J., et al., Dermal eosinophils in atopic dermatitis undergo cytolytic degeneration. *J Allergy Clin Immunol*, 1997. 99(5): p. 683-692.
- r-5. 6. Leung, D., *Immunopathology of atopic dermatitis*. Springer Sem. Immunopathol., 1992. 13: p. 427-440.
- r-6. 7. Jung, K., F. Linse, R. Heller, C. Moths, R. Goebel, and C. Neumann., Adhesion molecules in atopic dermatitis:

- VCAM-1 and ICAM-1 expression is increased in healthy-appeared skin. *Allergy*, 1996. 51(7): p. 452-460.
- r-7. 8. Wakite, H., T. Sakamoto, Y. Tokura, and M. Takigawa., E-selectin and vascular cell adhesion molecule-1 as critical adhesion molecules for infiltration of T lymphocytes and eosinophils in atopic dermatitis. *J Cutan Pathol*, 1994. 21: p. 33-39.
- r-8. 9. Leung, D., Atopic dermatitis: the skin as a window into the pathogenesis of chronic allergic disease. *J. Allergy Clin Immunol*, 1995. 96: p. 312-319.
- r-9. 10. Hamid, Q., et al., In vivo expression of IL-12 and IL-13 in atopic dermatitis. *J Allergy Clin Immunol*, 1996. 98: p. 225-31.
- r-10. 11. Hamid, Q., M. Boguniewicz, and D. Leung, Differential in situ cytokine gene expression in acute versus chronic atopic dermatitis. *J Clin Invest*, 1994. 94: p. 870-876.
- r-11. 12. Van der Heijden, F., et al., High frequency of IL-4 producing CD4+ allergen-specific T lymphocytes in atopic dermatitis lesional skin. *J Invest Dermatol*, 1991. 97: p. 389-394.
- r-12. 13. Parronchi, P., et al., Allergen- and bacterial antigen-specific T cell clones established from atopic donors show a different profile of cytokine production. *Proc Natl Acad Sci*, 1991. 88: p. 4538-4542.
- r-13. 14. Yamamoto, S., et al., Unbalanced production of interleukin-5 and interleukin-2 in children with atopic dermatitis. *Annals Asthma Allergy Immunol*, 1997. 78: p. 517-23.
- r-14. 15. Nakazawa, M., et al., Predominance of type cytokines-producing CD4+ and CD8+ cells in patients with Atopic Dermatitis. *J Aller Clinical Immunol*, 1997. 99: p. 673-82.
- r-15. 16. Werfel, T., et al., Allergen specificity of skin-infiltrating T cells is not restricted to type-2 cytokine pattern in chronic skin lesions of atopic dermatitis. *J Invest Dermatol*, 1996. 107(6): p.871-876.
- r-16. 17. Thepen, T., E. Langeveld-Wildschut, I. Bihari, D.van. Wichen, F.van Reijssen, G. Mudde, and C. Bruijnzeel-Koomen, Biphasic response against r-17. aeroallergen in atopic dermatitis showing a switch from an initial Th2 response to a Th1 response in situ: An immunocytochemical study. *J Allergy Clin Immunol.*, 1996. 97: p. 828-837.
- r-18. 18. Lester, M., et al., Down-regulating effects of IL-4 and IL-10 on the IFN-gamma response in atopic dermatitis. *J Immunol*, 1995. 154: p.6174-6181.
- r-19. 19. Vercelli, D and RS Geha, Regulation of Isotype Switching. *Curr Op in Immunology*, 1992. 4: p. 794-797.
- r-20. 20. Leiferman, K., Eosinophils in atopic dermatitis. *J Allergy Clin Immunol*, 1994. 94: p. 1310-1317.
- r-21. 21. Junghans, V., T. Jung, and C. Neumann, Human keratinocytes constitutively express IL-4 receptor molecules and respond to IL-4 with an increase in B7/BB1 expression. *Exp Dermatol*, 1996. 5(6): p. 316-324.
- r-22. 22. Reinhold, U., et al., Cytokine release from cultured peripheral blood mononuclear cells of patients with severe atopic dermatitis. *Acta Derm Venereol (Stockh)*, 1989. 69: p. 497-502.
- r-23. 23. Pastore, S., et al., Granulocytes macrophages colony-stimulating factor is overproduced in keratinocytes in atopic dermatitis. *J. Clin. Invest.*, 1997. 99: p. 3009-3017.
- r-24. 24. Byrom, N. and D. Timlin, Immune status in atopic eczema: a survey. *Br J Dermatol*, 1979. 100: p. 499.
- r-25. 25. Leung, D., A. Rhodes, and R. Geha, Enumeration of T cell subsets in atopic dermatitis using monoclonal antibodies. *J Allergy Clin Immunol*, 1981. 67: p. 450-55.
- r-26. 26. Zheng, M., G. Sun, and U. Mrowietz, The chemotactic activity of T-lymphocytes in response to interleukin 8 is significantly decreased in patients with psoriasis and atopic dermatitis. *Exp. Derm.*, 1996. 5(6):p. 334-40.
- r-27. 27. Trask, D., et al., Altered leukocyte activity in atopic dermatitis. *J Invest Dermatol*, 1988. 90: p. 526-31.
- r-28. 28. Sampson, H., K. Broadbent, and J. Bernhisel-Broadbent, Spontaneous release of histamine from basophils and histamine-releasing factor in patients with atopic dermatitis and food hypersensitivity. *New Eng J Med*, 1989. 321: p. 228-232.
- r-29. 29. Chan, S., et al., Altered prostaglandin E2 regulation of cytokine +production in atopic dermatitis. *J Immunol*, 1993. 151: p. 3345-52.
- r-30. 30. Ruzicka, T. and J. Ring, Enhanced releasability of prostaglandin E2 and leukotrienes B4 and C4 from leukocytes of patients with atopic eczema. *Acta Derm Venereo*, 1987. 67: p. 469.
- r-31. 31. Okano-Mitani, H., K. Ikai, and S. Imamura, Leukotriene A4 hydrolase in peripheral leukocytes of patients in atopic dermatitis. *Arch Dermatol Research*, 1996. 288: p. 168-72.
- r-32. 32. Leung, D., et al., Presence of IgE antibodies to staphylococcal exotoxins on the skin of patients with atopic dermatitis; evidence for a new group of allergens. *J Clin Invest*, 1993. 92: p. 1374-1380.
- r-33. 33. Leung, D., et al., Bacterial superantigens induce T cell expression of the skin-selective homing receptor, the cutaneous lymphocyte-associated antigen. *J Exp Med*, 1995. 181: p. 747-53.
- r-34. 34. Neuber, J., et al., Preferential expression of T-cell receptor V beta-chains in atopic eczema. *Acta Dermato-Vener.*, 1996. 76(3): p. 214-218.
- r-35. 35. Lintu, P., J. Savolainen, and K. Kalimo, IgE antibodies to protein and mannan antigens of pityrosporum ovale in atopic dermatitis patients. *Clin Exp Allergy*, 1997. 27: p. 87-95.
- r-36. 36. Linder, M.T., et al., Detection of Pityrosporum orbiculare reactive T cell clones from skin and blood in atopic dermatitis and characterization of cytokine profiles. *Clin Exp Allergy*, 1996. 26: p.1286-97.
- r-37. 37. Kieffer, M., et al., Immune reactions to Pityrosporum ovale in adult patients with atopic and seborrheic dermatitis. *J Amen Acad Dermatol*, 1990. 22: p. 739-742.
- r-38. 38. Fujimura, T., et al., Conversion of the CD4+ T cell profile from Th2-dominant type to Th1-dominant type after varicella-zoster infection in atopic dermatitis. *J Allergy Clin Immunol*, 1997. 100: p. 274-282.
- r-39. 39. Vezzio, N., et al., Human Th2-like clones induce IL-12 production by dendritic cells and may express several cytokine profiles. *Inter Immunol*, 1996. 8(12): p. 1963-1970.
- r-40. 40. Sampson, H. and C. McCaskill, Food hypersensitivity and atopic dermatitis: Evaluation of 113 patients. *J Pediatr*, 1985. 107: p. 669-675.
- r-41. 41. Clark, R. and A. Adinoff, Aeroallergen contact can exacerbate atopic dermatitis: Patch tests as a diagnostic tool. *J Am Acad Dermatol*, 1989.20: p. 617-629.
- r-42. 42. Mitchell, E., J. Crow, M. Chapman, S. Jouhal, F. Popr, and T. Platts-Mill., Basophils in allergen-induced patch test sites in atopic dermatitis. *Lancet*, 1982. 1: p. 127-130.
- r-43. 43. Tuft, L. and V. Heck, Studies in atopic dermatitis IV: Importance of seasonal inhalant allergens, especially ragweed. *J Allergy*, 1952. 21: p.181-186.
- r-44. 44. Tan, B., et al., Double-blind controlled trial of effect of housedust-mite allergen avoidance on atopic dermatitis. *Lancet*, 1996.347: p. 15--18.

- r-45. 45. Chandra, R., P. Shakuntla, and A. Hamed, Influence of maternal diet during lactation and use of formula feeds on development of atopic eczema in high risk infants. *Brit J Med*, 1989. 299: p. 228-230.
- r-46. 46. Saarinen, U. and M. Kajosaari, Breastfeeding as prophylaxis against atopic disease: prospective follow-up study until 17 years old. *Lancet*, 1995. 346: p. 1065-69.
- r-47. 47. Sigurs, N., G. Hattevig, and B. Kjellman, Maternal avoidance of eggs, cow's milk, and fish during lactation: effect on allergic manifestations, skin-prick tests, and specific IgE antibodies in children at age 4 years. *Pediatrics*, 1992. 89: p. 735-739.
- r-48. 48. Dahl, R., et al., Sleep disturbances in children with atopic dermatitis. *Arch pediatr Adolesc Med*, 1995. 149: p. 856-860.
- r-49. 49. Hashiro, M. and M. Okumura, Anxiety, depression and psychomatic symptoms in patients with atopic dermatitis: comparison with normal controls and among groups of different degrees of severity. *J Derm Science*, 1997. 14(1): p. 63-67.
- r-50. 50. Stewart, A. and S. Thomas, Hypnotherapy as a treatment for atopic dermatitis in adults and children. *Br J Dermatol*, 1995. 132: p. 778-783.
- r-51. 51. Crosby, I., My skin is only the top layer of the problem. *Arch Dermatol*, 1995. 131: p. 783--785.
- r-52. 52. Drake, L., J. Fallon, and A. Sober, Relief of pruritus in patients with atopic dermatitis after treatment with topical doxepin cream. *J Am Acad of Dermatol*, 1993. 31(4): p. 613-616.
- r-53. 53. Collins, P. and J. Ferguson, Narrowband (TL-01) UVB air-conditioned phototherapy for atopic eczema in children. *Br J Dermatol*, 1995. 133: p.653-667.
- r-54. 54. Sowden, J., et al., Double -blind, controlled, crossover study of cyclosporin in adults with severe refractory atopic dermatitis. *Lancet*, 1991. 338: p. 137-140.
- r-55. 55. Hanifin, J., et al., Recombinant interferon gamma therapy for atopic dermatitis. *J Am Acad Dermatol*, 1993. 28: p. 189-97.
- r-56. 56. Musiel, J., et al., Interferon-gamma in the treatment of atopic dermatitis: influence on T-cell activation. *Allergy*, 1995. 50: p.520-523.
- r-57. 57. Schneider, L., et al., Safety of long term therapy with recombinant interferon-gamma for atopic dermatitis. *J. Aller Clin Immunol*, 1997. 99:p. S477.
- r-58. 58. Nakagawa, H., et al., Tacrolimus ointment for atopic dermatitis. *Lancet*, 1994. 344: p. 883.
- r-59. 59. Aoyama, H., et al., Successful treatment of resistant facial lesions of atopic dermatitis with 0.1% FK506 ointment. *Br J Dermatol*, 1995. 133:p. 494-495.
- r-60. 60. Ruzicka, T., et al., A short-term trial of tacrolimus ointment for atopic dermatitis. *N Engl J Med*, 1997;337:p. 816-821.
- r-61. 61. Matsuda, H., N. Watanabe, G. Geba, J. Speri, M. Tsudzuki, J. Hiroi, M. Matsumoto, H. Ushio, S. Saito, P. Askenase, and C. Ra., Development of atopic dermatitis-like skin lesion with IgE hyperproduction in NC/Nga mice. *Inter. Immunol.*, 1997. 9(3): p. 461-466.
- r-62. 62. Hsu, C.-H., K.-Y. Chua, S.-K. Huang, I.-P. Chiang, and K.-H. Hsieh., Glutathione-S-transferase induces murine dermatitis that resembles human
- r-63. atopic dermatitis. *Clin. Exp. Allergy*, 1996. 26: p. 1329-1337.
- r-64. 63. Spergel, J., E Mizoguchi, J Brewer, TR Martin, AK Bhan and RS Geha, Epicutaneous sensitization of protein antigen induces local allergic dermatitis and hyperresponsiveness to methacholine after a single aerosolized exposure to antigen in mice. (submitted). 1997

Author Information

Jonathan M Spergel, M.D., PhD.

Division of Immunology, Children's Hospital and Harvard Medical School

Linda C Schneider, M.D.

Division of Immunology, Children's Hospital and Harvard Medical School