

Fatal depressed cranial fracture and living organ donation

P Kafas, G Pipi

Citation

P Kafas, G Pipi. *Fatal depressed cranial fracture and living organ donation*. The Internet Journal of Law, Healthcare and Ethics. 2008 Volume 5 Number 2.

Abstract

Sir,

A 16-year-old child fell down into a rough and rocky place, 3m above the sea level (Figure. 1). Computerized tomography revealed multiple depressed craniofacial fractures (Figure. 2). Brain death was confirmed in ICU post surgery. Living organ donation performed via the National Transplantation System connected to similar European Networks.

We would like to emphasize the importance of preventing sea injuries. Action of children in such areas should be prohibited due to high risk of fatality. Furthermore, the magnitude of living organ donation is a superior achievement. Useful information may be found in the British Transplantation Society website.[1]

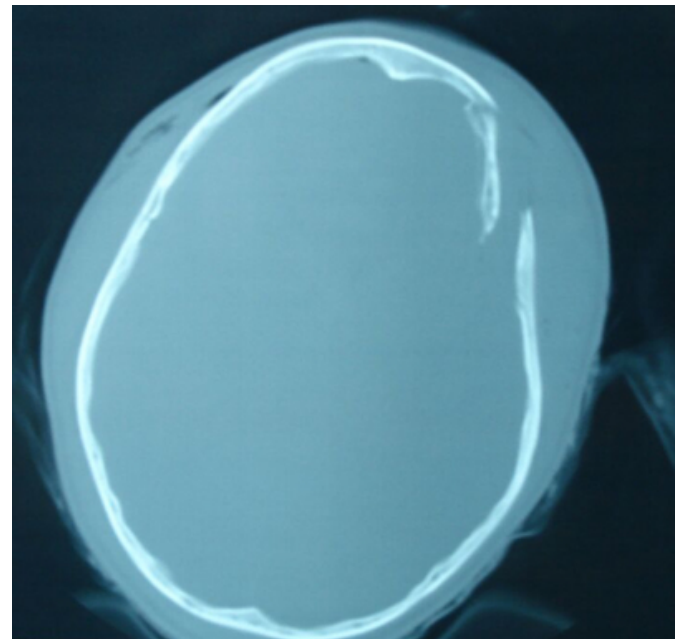
Figure 1

Figure 1



Figure 2

Figure 2



CORRESPONDENCE TO

Panagiotis Kafas 3 Kassandrou 65403 Kavala Greece
pankafas@yahoo.com

References

1. Bts.org.uk [homepage on the Internet]. Cheshire: The British Transplantation Society; c2007. Available from: www.bts.org.uk/.

Author Information

Panagiotis Kafas, DMD, MSc, PhD candidate

Department of Oral Surgery and Radiology, School of Dentistry, Aristotle University

Giovanni Pipi, MD

Department of Intensive Care Unit, General Hospital of Kavala