

# Endovascular papillary angioendothelioma in soft tissue of the gluteal region

X Dai Long, D Ying Qu, Y Zhi Huang, Y Ming Lu

## Citation

X Dai Long, D Ying Qu, Y Zhi Huang, Y Ming Lu. *Endovascular papillary angioendothelioma in soft tissue of the gluteal region*. The Internet Journal of Pathology. 2007 Volume 7 Number 2.

## Abstract

The endovascular papillary angioendothelioma (EPA), known as Dabska tumor, is a very rare type of hemangioendothelioma characterized by intraluminal papillary endothelial structures, most of which are superficial in location but occurrence in deeper tissues is also known. Here, we describe case report of soft tissue EPA of left gluteal region in a child. To the best of our knowledge this is the first case report describing the occurrence of this tumor from Chinese population.

## INTRODUCTION

Endovascular papillary angioendothelioma (EPA) known as Dabska tumor is a very rare vascular neoplasm characterized by anastomosing vascular channels which contain intraluminal papillary projections of endothelial cells [1]. This lesion, first described in 1969 by Dabska, was regarded as malignant because two of six patients had lymph node metastases [2]. Previous reported cases indicated that this lesion almost occurs in the skin or subcutis of infants and young children [3]. Recently, some pathologists have reported this tumor also occurs in deeper location such as spleen [4], soft tissue [5], bone [6], tongue [7], and testis [8]. However, there is no case report describing the occurrence of deep soft tissue in the gluteal region. We therefore report first case of EPA arising in the deep soft tissue of left gluteal region of 1 year, 1 month old child from Chinese population.

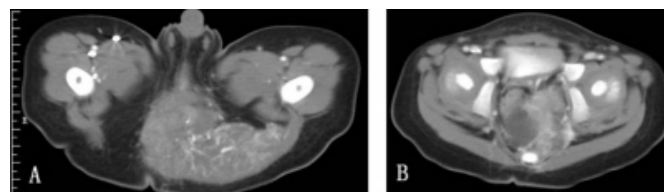
## CASE REPORT

A 1 year 1 month old child was referred to our pediatric surgery department for left gluteal tumor and intractable constipation for past 2 months. There was no history of any trauma to gluteal region. Physical examination showed a large tumor in the deep tissue of left gluteal region. Computerized tomography (CT) examination demonstrated a 9 cm × 6 cm × 5 cm tumor which existed at the soft tissue of left gluteal region (Figure 1A) and extended to deep soft tissue of perineal region and presacral space (Figure 1B). Additionally, tumor tissue invaded into the left gluteal muscles and infiltrated to anal sphincter. Microscopic examination showed a vascular tumor composed of anastomosing, irregular vascular channels forming papillae

in some areas (Figure 2). These papillae had hyalinized cores and were lined by atypical endothelial cells. The vascular channels were also lined by plump cuboidal endothelial cells with focal hobnailed appearance and lymphocytic sprinkling (Figure 3). Immunohistochemically, the tumor cells showed strong positively for CD34 and vascular endothelial growth factor receptor-3 (VEGER-3).

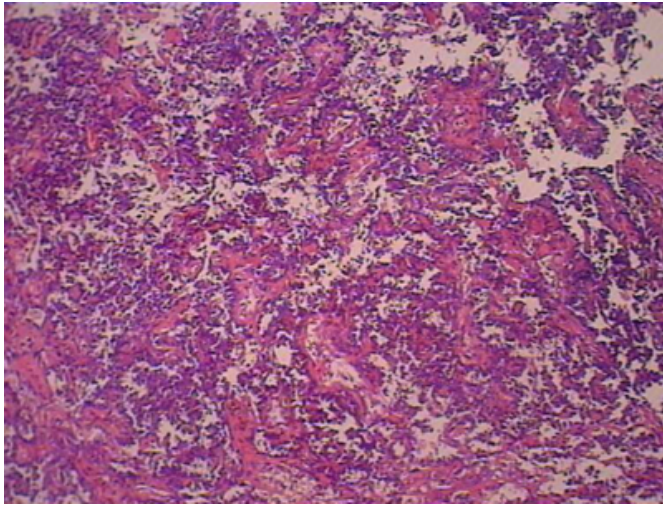
## Figure 1

Figure 1: CT images. CT examination showed a large tumor in the soft tissue of the left gluteal region. Tumor invaded into the left gluteal muscles (A), and deep soft tissue of perineal region and presacral space (B).



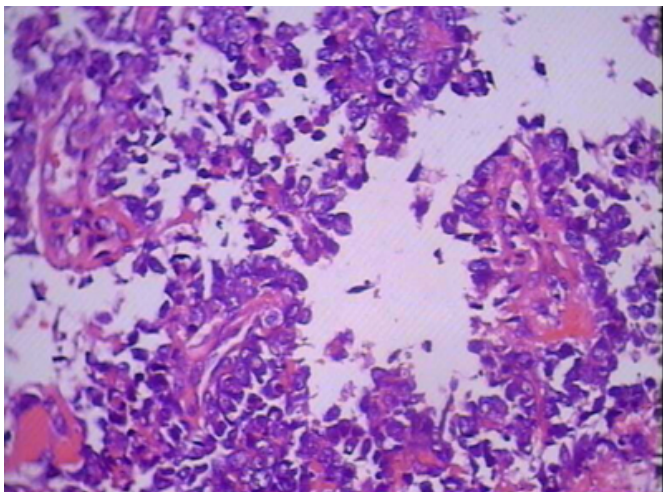
**Figure 2**

Figure 2: Low-power photomicrograph of the lesion showing papillae with hyalinized cores



**Figure 3**

Figure 3: High power view showing a vascular tumor with papillary tuft of cuboidal tumor cells.



## DISCUSSION

EPA is rare vascular tumor, first described in 1969 by Maria Dabska in skin and subcutis in infants and young children [2]. Since then approximately 31 cases, including 19 children and 12 adults, have been reported in the literature. The age of the patients ranges from birth to 83 years and there is no sex predilection [3]. Besides skin and subcutaneous tissue, the tumor also occurs in other deeper locations like spleen, bone, lip, testis, and soft tissues [4,5,6,7,8]. Clinically it presents as a slow-growing, painless, usually intradermal nodule that grows 2-3 cm in diameter. In our case, however, this tumor presented a larger volume (9 cm × 6 cm × 5 cm). This may imply that tumor tissue showed dissimilar growth

ability in dissimilar sites. Previous reported cases showed that EPA was low grade lesion with a capacity to invade into peripheral tissue and extend to regional lymph nodes [1,2,3]. Evidence of local infiltrative capacity for this tumor was also found in present case. At low power, this tumor appears similar to cavernous lymphangiomas. The cuboidal endothelial cells lining the vascular structures are characterized by a high nuclear cytoplasmic ratio and an apically placed nucleus that produces a surface bulge, accounting for the term “hobnail” or “matchstick”. Individual endothelial cells vary in size and shape, from small lymphocytoid cells to larger cuboidal cells and tall cylindrical cells with vacuolated cytoplasm and hyperchromatic eccentric nuclei on their luminal border. Additionally, both mitotic figures of tumor cells may be seen and many intraluminal lymphocytes which often attaches to the endothelial cells may also be evident [1]. All above features were noted in our case. Immunohistochemically, the tumor cells usually express CD31, CD34, von Willebrand factor, and VEGF-3. In the present case strong positive expression for CD34 and VEGF-3 was observed in tumor cells. In addition, this tumor may be associated with previously existing benign vascular lesions like vascular malformation [9]. In our case no vascular malformation like areas could be found even after extensive sampling. Because EPA has been regarded as a low-grade malignant lesion, orchidectomy is the best treatment of choice. In this report, the patient had a complete removal of his lesion; therefore, we feel that the prognosis is excellent. He is asymptomatic without evidence of recurrence six months post surgery.

In conclusion, to the best of our knowledge, present case is the first report for EPA from Chinese population. It also highlights the ability of local invasion.

## ACKNOWLEDGEMENT

We thank Han Shan Lu for his help about immunohistochemical examination. We also thank all members of Department of Pathology, Youjiang Medical College for Nationalities for their help.

This immunohistochemical examination of histological sample is supported by the Science Foundation of Youjiang Medical College for Nationalities (No. 2005).

## References

1. Weiss SW, Goldblum JR. Hemangioendothelioma: Vascular tumors of intermediate malignancy. In: Enzinger FM, Weiss SW, eds. Soft tissue tumors 4th edition. Mosby: St. Louis; 2001:891-915.
2. Dabska M. Malignant endovascular papillary

- angioendothelioma of the skin in children. *Cancer*. 1969; 24(3):503-510.
3. Schwartz RA, Dabski C, Dabska M. The Dabska tumor: a thirty-year retrospect. *Dermatology*. 2000; 201(1):1-5. Review.
4. Katz JA, Mahoney DH, Shukla LW, et al. Endovascular papillary angioendothelioma in the spleen. *Pediatr Pathol*. 1988; 8(2):185-193.
5. Argani P, Athanasian E. Malignant endovascular papillary angioendothelioma (Dabska tumor) arising within a deep intramuscular hemangioma. *Arch Pathol Lab Med*. 1997; 121(9): 992-995. Review.
6. McCarthy EF, Lietman S, Argani P, et al. Endovascular papillary angioendothelioma (Dabska tumor) of bone. *Skeletal Radiol*. 1999; 28(2):100-103.
7. Takaoka K, Sakurai K, Noguchi K, et al. Endovascular papillary angioendothelioma (Dabska tumor) of the tongue: report of a case. *J Oral Pathol Med*. 2003; 32(8):492-495.
8. Bhatia A, Nada R, Kumar Y, et al. Dabska tumor (endovascular papillary angioendothelioma) of testis: a case report with brief review of literature. *Diagn Pathol*. 2006; 1:12.
9. Quecedo E, Martínez-Escribano JA, Febrer I, et al. Dabska tumor developing within a preexisting vascular malformation. *Am J Dermatopathol*. 1996;18(3):302-307

**Author Information**

**Xi Dai Long**

Department of Pathology, Youjiang Medical College for Nationalities

**De Ying Qu**

Department of Pathology, Youjiang Medical College for Nationalities

**Yong Zhi Huang**

Department of Pathology, Youjiang Medical College for Nationalities

**Yu Ming Lu**

Department of CT, Affiliated Hospital of Youjiang Medical College for Nationalities