

Re-Emergence Of Coin In Nigerian Currency: Implication In Medical Practice

O Afolabi, A Okhakhu, A Adeosun

Citation

O Afolabi, A Okhakhu, A Adeosun. *Re-Emergence Of Coin In Nigerian Currency: Implication In Medical Practice*. The Internet Journal of Otorhinolaryngology. 2008 Volume 9 Number 1.

Abstract

Background

The reintroduction of the coins into the Nigerian currency in recent times in view of their economic status has brought back the already declining situation of coin in the aero-digestive tract. The aim of the study was to re-emphasize the implication of coin re-introduction on medical practice in Nigeria.

Material and methods

A retrospective review of all cases of patients with coin impaction in the aerodigestive tracts through June '99-May 2007. The information retrieved included biodata, clinical presentation treatment and outcome.

Result

The total number of 72 patients were studied with age range 2-9years, mean age of 3.83yrs (S.D=1.56). Highest incidence of 16.7% over three months after coin introduction and among under fives (91.6%). Male to female ratio was 1.3:1.0. About 52 (72.2%) were noticed by the parents and commonest symptom was drooling and dysphagia in 30.8%. Only 28% presented within 12 hours. All the patients were admitted with an average hospital stay of 1-5days. All the patients had rigid oesophagoscopy with 69.4% of coin located in cervical oesophagus. Post operative complication was noticed in 69.4%. Successful removal of the coin in 98.6% except for one who passed it out.

Conclusion

Coin in the aerodigestive tract is a preventable problem, 250% rise can be reduced or eliminated if caregivers can keep away the coin.

INTRODUCTION

Ingestion of foreign body is relatively common in the aero-digestive tract. However some of them get impacted because of their large size and shapes ^{1,2,3,4,5}. Once impacted they become associated with dramatic presentation of drooling or dysphagia which may be a source of apprehension among the care giver and the healthcare providers.

The Nigerian coins of fifty kobo, one naira and two naira have a dimension 24.50mm, 24.50mm and 27.50mm in diameter respectively with an average weight of 5.50gm, 5.50gm and 12.00gm respectively and made of nickel and gold materials ⁶, all released into circulation on February 28th 2007 ⁶. The reintroduction of the coins into the Nigerian currency in recent times in view of their economic status has brought back the already declining situation of coin in the

aero-digestive tract.

Following ingestion of a coin, this could spontaneously move down the oesophagus and expelled subsequently through the lower gastrointestinal tract or get impacted thereby necessitating an oesophagoscopy or lateral pharyngotomy for removal ^{7,8}.

The majority of foreign body ingestions occur in the pediatric population with a peak incidence between ages 6 months and 6 years. ^{8,9,10,11} In adults, true foreign object ingestion occurs more commonly among those with psychiatric disorders, mental retardation or impairment caused by alcohol, and those seeking some secondary gain with access to a

medical facility. ^{8,12,13} Ingestion of multiple foreign objects

and repeated episodes are not uncommon. Edentulous adults are also at greater risk for foreign body ingestion, including of their dental prosthesis^{12,14}. This study was carried out to re-emphasize the implication of coin re-introduction into the Nigerian currency and its effect has started manifesting with the re-emergence of impacted coin in the oesophagus.

MATERIALS AND METHODS

This was a retrospective study of all the patients that presented to the Accident and Emergency, Emergency paediatric departments and the ENT clinics and wards with coin impaction in the aerodigestive tract through June 1999 and May 2007. Their records were retrieved and the data extracted from the records included the biodata such as age, sex, their socioeconomics status, who noticed the symptoms, variable complaints, the duration of the foreign body in the oesophagus, surgical intervention findings, the duration of hospital stay, outcome, associated complications and follow up. All these were entered into SPSS version 11.0 soft ware and results presented in tables and figures.

RESULTS

The total number of patients were studied were 72 with a mean age of 3.83years (S.D= 1.56) while the modal age was 3.50years. The age range from the study was between 2-9years with the highest incidence among the under fives (5years and below) in about 66 (91.6%) out of which age 3.0years constituted about one third (Table 1.0).

Figure 1

Table 1: Age-Frequency

Age of patients (yrs)	Frequency (%)
2.00	14 (19.4%)
3.00	22 (30.6%)
4.00	12 (16.7%)
5.00	18 (25.0%)
6.00	2 (2.8%)
7.00	2 (2.8%)
9.00	2 (2.8%)
Total	72 (100%)

Male to female ratio was found to be 1.3:1.0 (40males and 32 females). Increased incidence was noticed after introduction of coin with 12 (16.7%) of patients seen over the last three months of the study when coin was introduced with an average of 4 patients per month. Socioeconomic stratification showed 54 (75%) in the class III while about 16 were in the class IV socioeconomic class and only one in the class I socioeconomic class. About 52 (72.2%) were noticed by the parents, 16 (22.2%) were volunteered by the patients themselves and 2 (2.8%) each by peer group and sibling. Majority of the patients presented with drooling and dysphagia as their presenting complaints in 22 (30.8%) followed by dysphagia alone in 12 (16.7%) and the rest presentation constituted about 53.5% (Table 2.0).

Figure 2

Table 2: Symptoms at presentation

Symptoms	Frequency
Cough/vomiting/dysphagia	2 (2.8%)
Cough/wheeze/dyspnoea	2 (2.8%)
Coughing	2 (2.8%)
Drizzling	4 (5.6%)
Drizzling/vomiting	4 (5.6%)
Dysphagia	12 (16.7%)
Dysphagia/drizzling	22 (30.8%)
dysphagia	2 (2.8%)
Odynophagia/drizzling	2 (2.8%)
Swallowing of coin/drizzling	10 (14.0%)
Swallowing of coin/dysphagia	2 (2.8%)
Swallowing of coin/drizzling/vomit	4 (5.6%)
Vomiting/dysphagia	2 (2.8%)
Total	72 (100%)

Most of the patients (84%) presented within the first five days of the occurrence of symptoms, with 16.8% within 6hours, 11.2% within 12hours and 25.2% within 24hour (Table 3.0).

Figure 3

Table 3: Duration before presentation

Duration	Frequency
<1hour	0 (0%)
1-6hours	12 (16.8%)
>6-12hours	8 (11.2%)
>12-24hours	18 (25.2%)
>1-5days	22 (30.8%)
>5days-2weeks	6 (8.4%)
>2weeks-4weeks	0 (0%)
>1-6months	6 (8.4%)
>6months	0 (0%)
Total	72 (100%)

All the patients were admitted with postoperatively hospital stay between 1-3days in 24 patients (33.4%), 3-5days in 22 (30.6%) (Table 4.0).

Figure 4

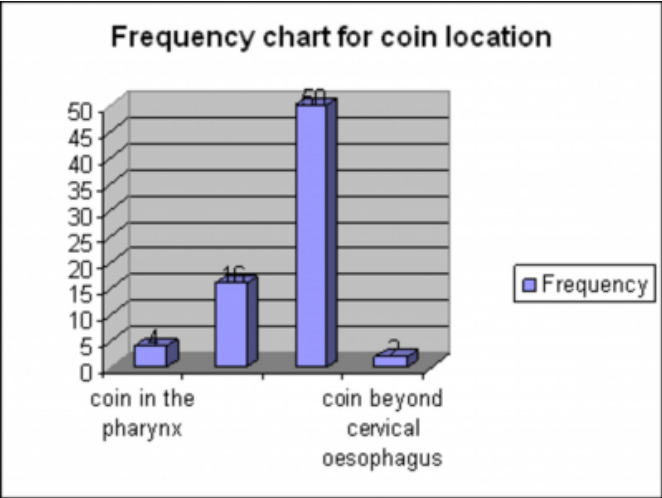
Table 4: Duration of Hospital stay

Duration	Frequency
1-3days	24 (33.4%)
>3-5days	22 (30.6%)
>5-7days	14 (19.4%)
>7-14days	8 (11.1%)
>2weeks	4 (5.6%)
Total	72 (100%)

Attempt at removal was observed despite the inability to see the foreign body in 26 (36.1%) of the patients, no attempt in 34 (47.2%) and no information in 12 (16.7%). All the patients had rigid oesophagoscopy and the Intraoperative finding showed coin in cervical oesophagus in 69.4% patients (Figure 1.0).

Figure 5


Figure 1: Intraoperative findings



Post operative complication was noticed also in 69.4% patients which included hyperemia/oedema in 24 (33.3%), bronchopneumonia in 6 (8.3%) and bruises and bleeding in 20 (27.8%) (Figure 2.0).

Figure 6

Figure 2: Complication post extraction of coin



Almost all the patient had successful removal of the coin in the oesophagus except one who passed it out.

DISCUSSION

The re-introduction of coin into the Nigerian economic system brought back the memory of impacted coin which has gone down remarkably from the available data in our centre, only less than five in three years.

Management of impacted foreign body in the oesophagus is influenced by the patient's age and clinical condition; the size, shape, and classification of the ingested material; the anatomic location in which the object is lodged; and the

technical abilities of the endoscopist. ^{15,16}

Our study showed that majority of the foreign body were found among the under fives as compared to okoye et al who found it among the under ten ¹⁷. Male more than female this can be associated with high level of inquisitiveness among the male children and it is similar to finding from other workers, majority of these children are from the middle and low socioeconomic classes who are predispose to keeping a lot of these dangerous but economically viable but weak currency at home for their use or for the children's use.

Increased incidence was noticed after introduction of coin with about 12 (16.7%) over the last three month with an average of 4 cases per month compared to about 60 patients seen over 93months with an average of 1.5 patients per month which represent about 250% rise. This is extremely high and it is demanding on the normal flow of practice with increase manpower diversion towards solving this preventable problems as well as increasing its morbidity.

The increasing availability of coin in our various home which are either displayed recklessly of used as toy by the children who are in their explorative stage may have access to such material which are ingested. They are available in different denominations of fifty kobo, one naira and two naira, in various sizes ⁶ and the highest of such denomination today is economically worthless to a Nigerian compared to the enormous inflation. The time and attending complication associated with the impaction of this foreign body, its removal and the cost to both the parents and the patients which cannot be quantified.

Impacted oesophageal foreign body may be associated with complication such as haematemesis, oesophagia perforation, mediastinitis, pneumothorax, pleural effusion, tracheoesophagia fistula, septicemia, pneumonia, aspiration and sometimes death could result ¹¹ however in our study only 69.4% had complications and these may be associated to late presentation by the patients as those that presented early has no attendant complications

Almost three quarter of the patient's symptom were noticed by the observant parents when the object the child was playing with could not be located around the child that suggested an option of swallow. Self reporting was also noticed among the older, fully conscious, communicative children who may still be able to localize the point or position of the swallowed coin however this is often not reliable ¹⁸. In many instances the ingestion goes

unrecognized or unreported until the onset of symptoms, which may be remote from the time of ingestion^{19,20,21,22} The commonest symptom reported by most of our patients/caregiver was drooling and dysphagia, then dysphagia when they are able to swallow saliva. The anatomic proximity of the upper airway and oesophagus permit the development of respiratory symptoms like cough and stridor as observed in our study¹⁷ Young children, the mentally impaired, or the psychiatrically deranged may present with choking, refusal to eat, vomiting, drooling, wheezing, bloodstained saliva, or respiratory distress.^{23,24,25} which should also suggest foreign body ingestion in this group of children thus the need to further evaluate them. All our diagnosis were supported with plain radiograph not only to make diagnosis but also to localize the coin, for medicolegal reason, and follow up of patients The lateral projection confirms location in the esophagus and may reveal the presence of more than one coin which was not found in our study, However, fish or chicken bones, wood, plastic, most glass, and thin metal objects are not readily seen.²³ A contrast examination should not be performed routinely because of the risk of aspiration and because coating of the foreign body and esophageal mucosa compromises subsequent endoscopy¹⁵.

Management of the patient is influenced by the patient's age and clinical condition; the size, position of the coin if vertical or horizontal, shape, and classification of the ingested material; the anatomic location in which the object is lodged; and the technical abilities of the endoscopist.^{15,16} The timing of endoscopic intervention in foreign body ingestion is dictated by the perceived risks of aspiration and/or perforation base on the position/placement. In children, the true duration of the foreign body in the esophagus may be unknown until it is discomforting. The earliest presentation noted in our study was 1-6hours in 16.8% when the symptom was observed while over half of the patients presented within 24hours of complaint to the caregiver. More than one third of the patients were still able to tolerate the coin between 1-5days before presentation this may be at the influence of the care giver who will want to wait and watch if the child will pass it out as this is risky as only a quarter will pass out the coin from studies by waltzman et al²⁶

Minimum hospital stay observed from the study was 1-3days in about a third of the patients this is just to observe for oesophageal perforation as compared to 16hours observation in endoscopic removal in boston based study²⁶ and as stated

earlier the true duration in children can not be ascertained so precaution is taken. Only four patients were observed to have 2weeks admission this was due to pneumonic complication the child is being managed for, coupled with their distance to the health facility and the ability of the caregiver to continue home management for better outcome. Despite the risk associated with the aerodigestive foreign bodies attempted removal with various methods such as induction of vomiting, finger insertion into the child's oropharynx was noted in more than one third of the patients in the study. This could further impact the coin or increase the risk of perforation. All the foreign bodies were removed using rigid oesophagoscope and almost all were removed with minimal complication which is within acceptable level and only two (2.8%) could not be located and patient subsequently passed it out. There was no death reported from our study similar to findings elsewhere^{27,28}

In conclusion the re-emergence of coin into the Nigerian economy as a mean of transaction has brought back the menace of coin impaction in the aerodigestive tracts with increased incidence recorded in the last three months with 250% rise, common among the under fives, male with slight delayed presentation and hospital admission. These have effect on the normal flow or routine work with focusing of attention on a preventable accident, parental economic input into the community as well as unexpected medical expenses on the parents thus the need for extra care by the caregiver to avoid unnecessary wastage spending.

CORRESPONDENCE TO

Dr O.A. Afolabi P.O. Box 931, Ilorin, Nigeria. E-mail: droaafolabi@yahoo.com Tel : +2348035727069

References

1. Amadasun EO, Coin as oesophagia foreign body: Effect of change in minting. Afr. Med. Rev.1995;6-8
2. Hawkins DB, Removal of blunt foreign bodies from oesophagus. Ann. Otol Rhinol Laryngol 1990;9:684-688
3. Crysdal WS, Sendi KS, Yoo J. Oesophageal foreign bodies in children: 15 years review of 684 cases. Ann Oto Rhinol Laryngol 1991;100:320-68
4. Davey WW and Burkitt DP. Foreign body in the oesophagus in : companion to surgery in Africa. Churchill livingstone ,London,1989, P182
5. Jackler RK and Kaplan MJ. Oesophageal foreign bodies in Schroeder SA, Krupp MA, Trerney TR and Stephen-Agrwalk TM (eds) Current Medical diagnosis and Treatment. Lange (publisher) London 1989, P. 128
6. New central bank of Nigeria website www.cenbank.org/currency/gallery/50k/N2/N1, viewed on 6th October 2007
7. Clarke PO. Foreign body in the oesophagus in Dudley

- HAF (eds). Hamilton Bailey's Emergency surgery. Wright (Publisher) Bristol, 1977,P 330-332.
8. Webb WA. Management of foreign bodies of the upper gastrointestinal tract: update. *Gastrointest Endosc* 1995;41:39-51.
9. Cheng W, Tam PK. Foreign-body ingestion in children in children: experience with 1265 cases. *J Pediatr Surg* 1999;34: 1472-6.
10. Panieri E, Bass DH. The management of ingested foreign bodies in children-a review of 663 cases. *Eur J Emerg Med* 1995;2:83-7.
11. Hachimi-Idrissi S, Corne L, Vandenplas Y. Management of ingested foreign bodies in childhood: our experience and review of the literature. *Eur J Emerg Med* 1998;5:319-23.
12. Blaho KE, Merigian KS, Winbery SL, Park LJ, Cockrell M. Foreign body ingestions in the emergency department: case reports and review of treatment. *J Emerg Med* 1998;16:21-6.
13. Kamal I, Thompson J, Paquette DM. The hazards of vinyl glove ingestion in the mentally retarded patient with pica: new implications for surgical management. *Can J Surg* 1999;42:201-4.
14. Abdullah BJJ, Teong LK, Mahadevan J, Jalaludin A. Dental prosthesis ingested and impacted in the esophagus and orolaryngopharynx. *J Otolaryngol* 1998;27:190-4.
15. Ginsberg GG. Management of ingested foreign objects and food bolus impactions. *Gastrointest Endosc* 1995;41:33-8.
16. Faigel DO, Stotland BR, Kochman ML, Hoops T, Judge T, Kroser J, et al. Device choice and experience level in endoscopic foreign object retrieval: an in vivo study. *Gastrointest Endosc* 1997;45:490-2.
17. Okoye II, Imo AO, Okwulehie V. Radiologic management of impacted coin in the oesophagus--a case report. *Niger J Clin Pract*. 2005 Jun;8(9):56-9
18. Connolly AA, Birchall M, Walsh-Waring GP, Moore-Gillon V. Ingested foreign bodies: patient guided localization is a useful clinical tool. *Clin Otolaryngol* 1992;17:520-4.
19. Adams DB. Endoscopic removal of entrapped coins from an intraluminal duodenal diverticulum 20 years after ingestion. *Gastrointest Endosc* 1986;32:415-6.
20. Kirberg AE. Long standing esophageal foreign body. *Gastrointest Endosc* 1986;32:304-5.
21. Yamamoto M. A chopstick is removed after 60 years in the duodenum. *Gastrointest Endosc* 1985;31:51.
22. Tsui BCH, Mossey J. Occults liver abscess following clinically unsuspected ingestion of foreign bodies. *Can J Gastroenterol* 1997;11:445-8.
23. Cheng W, Tam PK. Foreign-body ingestion in children in children: experience with 1265 cases. *J Pediatr Surg* 1999;34:1472-6.
24. Kamal I, Thompson J, Paquette DM. The hazards of vinyl glove ingestion in the mentally retarded patient with pica: new implications for surgical management. *Can J Surg* 1999;42:201-4.
25. Choudhurg CR, Bricknell MC, MacIver D. Oesophageal foreign body: an unusual cause of respiratory symptoms in a three-week-old baby. *J Laryngol Otol* 1992;106:556-7.
26. Waltzman ML et al. A randomized clinical trial in the management of esophageal coins in children. *Pediatrics* 2005 Sep; 116:614-9.
27. Simic MA, Budakov BM. Fatal upper esophageal hemorrhage caused by a previously ingested chicken bone: case report. *Am J Forensic Med Pathol* 1998;19:166-8.
28. Bennet DR, Baird CJ, Chan KM, Crookes PF, Bremner CG, Gottlieb MM, et al. Zinc toxicity following massive coin ingestion. *Am J Forensic Med Pathol* 1997;18:148-53.

Author Information

Olushola A. Afolabi, FWACS

Post fellowship senior registrar, Department Of Otorhinolaryngology, University College Hospital

Amina L. Okhakhu, FWACS, FMCORL

Post fellowship senior registrar, Department Of Otorhinolaryngology, University College Hospital

Aderemi A. Adeosun, FWACS, FMCORL

Senior lecturer/consultant, Department Of Otorhinolaryngology, University College Hospital