

# A rare case of Periurethral Leiomyoma with unusual expression of estrogen and progesterone receptors

V Hanchanale, A Rao, W Al-Salti, H Motiwala

## Citation

V Hanchanale, A Rao, W Al-Salti, H Motiwala. *A rare case of Periurethral Leiomyoma with unusual expression of estrogen and progesterone receptors*. The Internet Journal of Urology. 2007 Volume 5 Number 2.

## Abstract

Urethral tumours are rare and can arise from its lining epithelium, glandular epithelium or the smooth and striated muscle fibers. Periurethral leiomyoma, a benign tumour arising from the smooth muscle fibers is extremely rare that can present with varying clinical features. Excision biopsy should be carried out to differentiate it from malignant lesions. Peri-urethral leiomyomas have been shown to express estrogen and progesterone receptors, therefore can increase rapidly in size during pregnancy. Less than 5 cases with such receptor expression mainly in pregnant females have been reported in literature. We present a rare case of peri-urethral leiomyoma with positive estrogen and progesterone receptor expression in non-pregnant lady that was rapidly increasing in size.

## INTRODUCTION

Periurethral leiomyoma is a rare benign tumour that has rarely been shown to express the estrogen and progesterone receptors. Prompt diagnosis, differentiation from the malignant tumour and treatment of this unusual tumour is necessary to prevent complications.

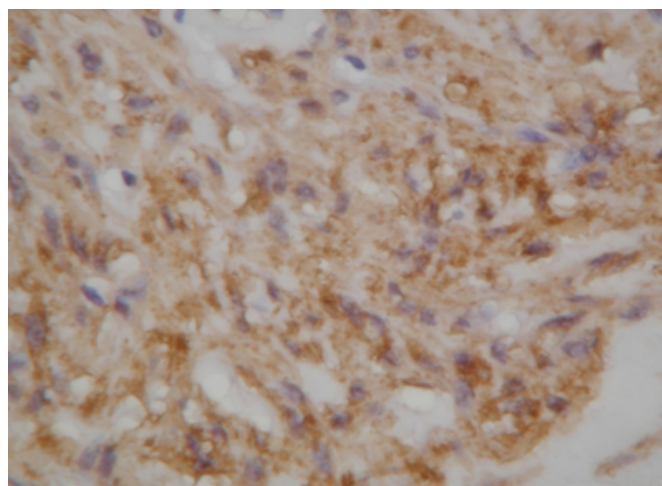
## CASE HISTORY

An Asian woman aged 27 presented with a two-month history of a lump in the vagina, two episodes of blood in the urine and mild obstructive lower urinary tract symptoms. She had been married for two years, had no children and was not on any medication. Clinical examination revealed a 6cm smooth firm swelling situated on the left side of the external urethral meatus. Ultrasound of abdomen and pelvis and intravenous urogram was entirely normal. Flexible cystoscopy and examination under anesthesia showed an engorged vascular lump in the urethral wall. Surgical exploration revealed a totally encapsulated tumour extending towards but not involving the external sphincter. The tumour was completely excised. The histology revealed an encapsulated tumour with smooth muscle fibers suggesting a benign leiomyoma (Fig. 1). Immunohistochemical staining was positive for smooth muscle actin (Fig. 2) and negative for S-100 protein (stains neural tissue). Staining for estrogen receptors (Fig. 3) and progesterone receptors (Fig. 4) was strongly positive. This suggests possibility of a hormone sensitive tumour. At 6 months follow-up, she was continent

with no evidence of recurrence.

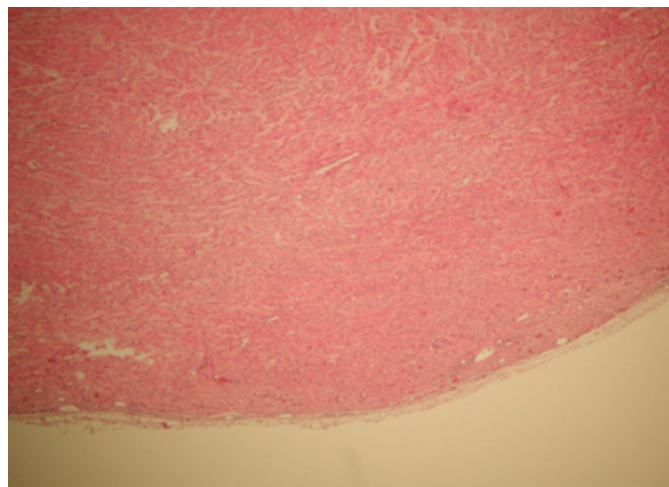
## Figure 1

Figure 1: Low Power view showing smooth muscle fibers and the capsule



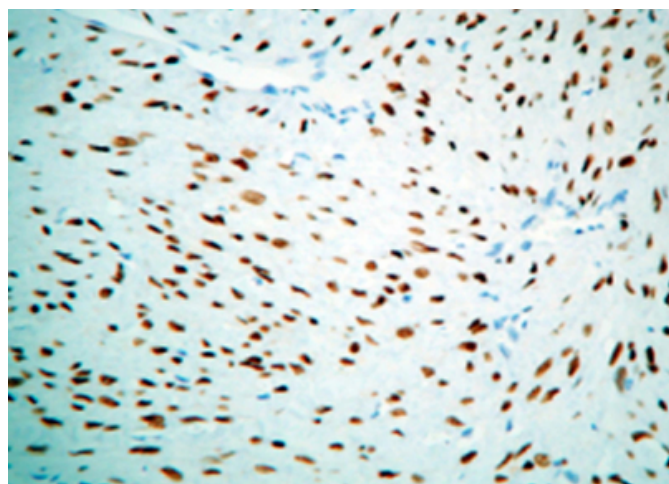
**Figure 2**

Figure 2: Immunohistochemical staining for smooth muscle actin (SMA)



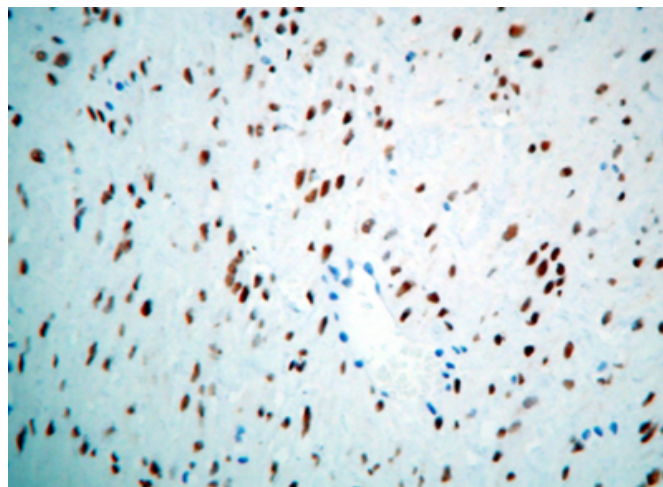
**Figure 3**

Figure 3: Immunohistochemical staining for Estrogen receptor



**Figure 4**

Figure 4: Immunohistochemical staining for Progesterone receptor



## DISCUSSION

Urethral tumours are rare and can arise from its lining epithelium, glandular epithelium or the smooth and striated muscle fibers. Leiomyomas affecting the kidney, ureter, bladder, prostate, testis, epididymis, urethra and the penis have been described in the literature.<sup>1,2,3</sup> Peri-urethral leiomyomas, benign tumours arising from the smooth muscle fibers are extremely rare that can present with varying clinical features. The first reported case was by Buttner in 1984.<sup>4</sup> Tumours most commonly occur in women of reproductive age and mostly involve the proximal urethra.<sup>5</sup> Complications may include obstruction to urethra causing urinary tract infection and retention of urine. There is no reported case of malignant degeneration of an existing urethra leiomyoma. Although symptomatic swelling is the most common mode of presentation, patients presenting with hematuria, dyspareunia, repeated UTI, urinary retention, acute renal failure and chronic renal failure have also been described.<sup>1</sup> Less than five cases have reported the presence of estrogen and progesterone receptors in peri-urethral leiomyomas, suggesting a possible role of sex hormones. Reports of rapid enlargement of the tumour during pregnancy further supports the influence of sex hormones on these benign tumours.<sup>6,7</sup> Our case was unique as it was rapidly increasing tumor inspite of her not being pregnant as well as its expression of estrogen and progesterone receptors.

Investigations include ultrasound scan of urinary tract to exclude chronic obstruction. MRI scan of the pelvis is indicated if malignancy is considered or in case there is a suspicion of tumour extending into the external sphincter.<sup>2</sup>

Complete surgical excision is the treatment of choice, although cases of transurethral resection of the tumour have been documented without recurrence.<sup>8</sup> Due to the possibility of hormonal influence on these tumours, conservative management using GnRH analogues may find a place in the future. The role of GnRH analogues should be carefully sought balancing between the side effects and the resurgence of disease on cessation of the treatment. As numerous studies have shown contradictory evidence to each other, the association of these leiomyoma with sex hormones still remains controversial.<sup>2,3,9,10</sup> Complete local excision is the treatment of choice, until further research is done to support hormonal manipulation to treat these tumours.

### **CORRESPONDENCE TO**

Mr Vishwanath Hanchanale Research Fellow, Urology  
Leighton Hospital Crewe, Cheshire CW1 4QJ United  
Kingdom Tel: 00 44 7708090688 Email:  
vishwanath.hanchanale@gmail.com

### **References**

1. Belis JA, Post GJ, Rochman SC. Genitourinary

- leiomyomas. *Urology* 1979; 13(4): 424-9.
2. Goldman HB, McAchran SE, MacLennan GT. Leiomyoma of the Urethra and Bladder. *J Urol* 2007; 177(5): 1890.
3. Bai SW, Jung HJ, Jeon MJ, Jung da J, Kim SK, Kim JW. Leiomyomas of the female urethra and bladder: a report of five cases and review of the literature. *Int Urogynecol J Pelvic Floor Dysfunct.* 2007; 18(8): 913-7.
4. Buttner C. Ein fall von Myom der Weiblichen Urethra. *Z Geburshc* 1984; 28: 135-6.
5. Cornella JL, Larson TR, Lee RA. Leiomyoma of the female urethra and bladder: report of twenty-three patients and review of the literature. *Am J Obstet Gynecol* 1997; 176(6): 1278-85.
6. Kesari D, Gerner O, Segal S. Estrogen receptors in a urethral leiomyoma presenting in pregnancy. *Int J Gynaecol Obstet* 1994; 47(1): 59-60.
7. Alvarado-Cabrero I, Candanedo-Gonzalez F, Sosa-Romero A. Leiomyoma of the urethra in a Mexican woman: a rare neoplasm associated with the expression of estrogen receptors by immunohistochemistry. *Arch Med Res* 2001; 31(1): 88-90.
8. Joshi HB, Beck RO. Leiomyoma of the female urethra with upper tract dilation and treatment with transurethral resection: a case report and literature review. *Tech Urol* 2000; 6(3): 223-5.
9. Shield DE, Weiss RM. Leiomyoma of the female urethra. *J Urol* 1973; 109(3): 430-1.
10. Strang A, Lissan SW, Petrou SP. Urethral endometriosis and coexistent urethral leiomyoma in a postmenopausal women. *Int Braz J Urol* 2004; 30(6): 496-8.

**Author Information**

**Vishwanath Hanchanale, MS, MRCS**

Research Fellow, Urology, Leighton Hospital

**Amrith Raj Rao, MS, DNB, FRCS**

Specialist Registrar, Wexham Park Hospital

**Wasim Al-Salti, FRCS**

Consultant Pathologist, Wexham Park Hospital

**Hanif Motiwala**

Consultant Urologist, Wexham Park Hospital