

Giant Lipoma

A Hafeez, A Darzi, H Zargar, T Javeed

Citation

A Hafeez, A Darzi, H Zargar, T Javeed. *Giant Lipoma*. The Internet Journal of Plastic Surgery. 2006 Volume 4 Number 2.

Abstract

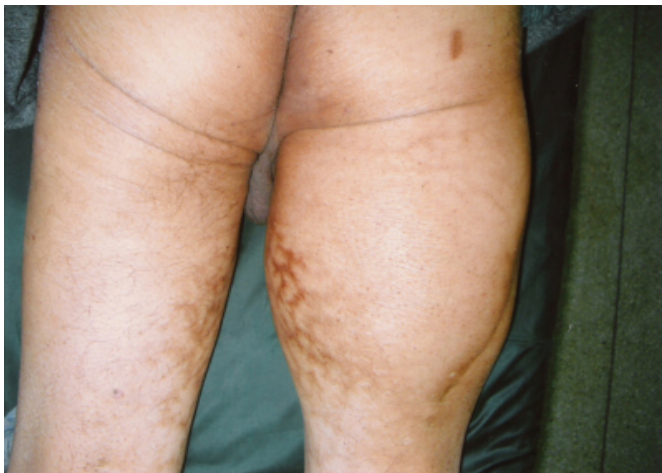Lipoma is one of the commonest benign mesenchymal tumors in body and found almost in all organs where the fat exists. It is usually small but giant lipomas can be present in thigh, shoulder be trunk. The present study describes a 60 year old male with a huge mass right thigh which on histopathology revealed features suggestive of lipoma.

CASE REPORT

A 60 year old male presented in out patient clinic with history of progressively increasing swelling in right thigh, which he noticed 3½ years back. Swelling was otherwise asymptomatic except that he had to wear loose fitting trousers.

On examination, right thigh girth was grossly increased as compared to the left thigh(Fig.1).

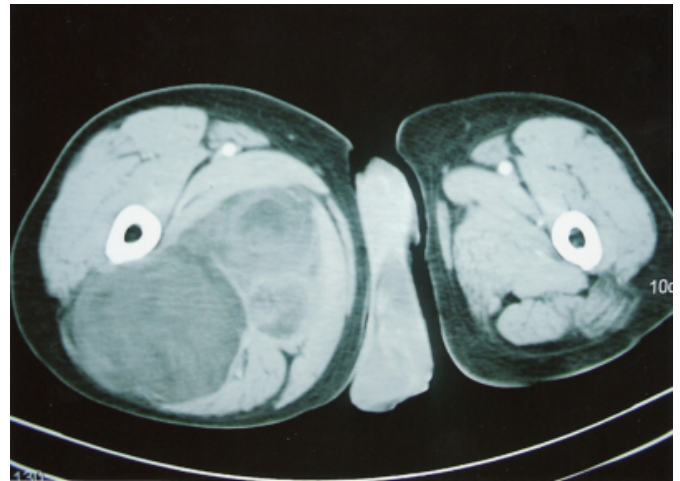
Figure 1



There were erythema ab agni over the medial aspect of both thighs (as is usual in Kashmiri people because of Kangri – “the fire pot”). The swelling was firm, non-tender and free from underlying structures.

CT scan of the right thigh was done which revealed a hypodense mass in the posterior compartment of the thigh beneath the hamstring muscles (Fig.2).

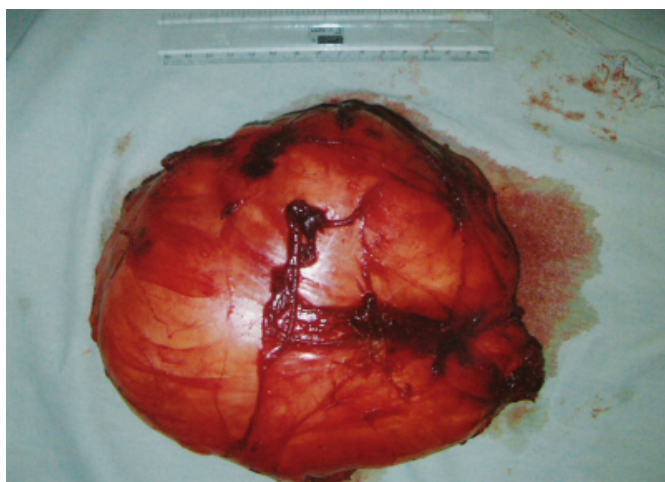
Figure 2



FNAC of the swelling revealed mature fat cells, suggestive of lipoma.

The patient was operated on under general anaesthesia, in prone position and the tumour was found beneath the hamstring muscles and was dissected out easily because of the pseudocapsule. Wound was closed in layers, leaving a suction drain inside the cavity. Healing progressed uneventfully. Histopathological examination revealed features consistent with lipoma. The tumour removed measured 21x17x14cm in size and weighed 2950gms(Fig.3).

Figure 3



Six months after surgery, the patient is symptom free and has no signs of recurrence.

DISCUSSION

Lipoma is one of the commonest benign mesenchymal tumour in the body composed of mature adipose cells. It is found in almost all the organs⁽¹⁾ of the body where normally fat exists that is why it is also known as ubiquitous tumour or universal tumour.

Most of the lipomas present as small subcutaneous swellings without any specific symptom. Giant lipomas, though rare, can present in thigh, shoulder or trunk. Clinical features of these giant lipomas are mainly because of their size which includes pain because of stretching of adjacent nerves⁽³⁾, restriction in movements of the part involved or social embarrassment because of mere size of the swelling.

Although definitive diagnosis of giant lipoma can be made only by histopathological examination, but once suspected, other investigations can provide additional information about the tumour. The characteristics of benign lipoms on ultrasonography⁽²⁾, CT⁽¹⁰⁾ and MRI⁽⁷⁾ have been well

established and even Tc⁹⁹ DTPA scan have been used to confirm the diagnosis.

Surgery is the treatment of choice⁽⁶⁾ of these giant swellings due to their tendency to recur and their potential hazard of malignant transformation⁽⁸⁾, other option for treatment of these giant swelling is liposuction⁽⁶⁾. The dissection of these lipomas is usually easy because of continuous pressure on the surrounding tissue, a well defined pseudocapsule is formed. Dead space created because of dissection of the giant lipomas is usually drained with the help of a suction drain to avoid collection. As already mentioned, these tumours have tendency to recur and can have malignant transformation, therefore, should be followed meticulously.

References

1. Devis C Jr and Gruhn JG. Giant lipoma of the thigh. Arch Surg 1967;95:151.
2. Fornage BD, Tassin GB. Sonographic appearance of superficial soft tissue lipomas. J Clin Ultrasound 1991;19:215.
3. Gluscek S. Giant limpma of thigh. Wiad Lek. 1987 Jun 15;40(12):845-8.
4. Goshen E, Mellen I, Lantsberg S et al. Radionucleotide imaging of soft tissue masses with TC-99m DTPA. Clin Nucl Med 1991;16:636.
5. Hakim E, Kolanden Y, Meller Y, Moses M and Sagi A. Gigantic lipomas. Plast Reconstr Surg 1994 Aug;94(2):369-71.
6. Nichter LS, Gupta BR. Liposuction of giant lipomas. Ann Plast Surg 1990 Apr;24(4):362-5.
7. Sundram M, Baran G, Merenda G and McDonald DJ. Myxoid liposarcoma. Magnetic resonance imaging appearance and clinical and histological correction. Skeletal Radiol 1990;19:359.
8. Terzioğlu A, Tuncali D, Yuksel A, Bingul F, Aslan G. Giant Lipoma: a series of 12 consecutive cases and a giant liposarcoma of thigh. Dermatol Surg 2004 Mar;39(3):463-7.
9. Tocchi A, Maggiolini F, Lepre L, Costa G, Liotta G, Mazzoni G. Giant lipoma of thigh: report of a case. G Chir 1999 Aug-Sep;20(8-9):351-3.
10. Wolfe SW, Bansal M, Heely JH et al. Computed tomographic evaluation of fatty neoplasms of extremities. A Clinical radiographic and histologic review of cases. Orthopedics 1989;12:1351.

Author Information

Adil Hafeez, MBBS, MS, DNB, FICS, MNAMS

Department of Plastic and Reconstructive Surgery, Sher-i-Kashmir Institute of Medical Sciences

Ashraf Darzi, MBBS, MS, MCh

Department of Plastic and Reconstructive Surgery, Sher-i-Kashmir Institute of Medical Sciences

Haroon Rasheed Zargar, MBBS, MS

Department of Plastic and Reconstructive Surgery, Sher-i-Kashmir Institute of Medical Sciences

Tariq Javeed, MBBS, MS

Department of Plastic and Reconstructive Surgery, Sher-i-Kashmir Institute of Medical Sciences