

A very rare case report of late presentation of Moya moya syndrome in a child with history of tubercular meningitis'

K Umesh, K Shilpa

Citation

K Umesh, K Shilpa. *A very rare case report of late presentation of Moya moya syndrome in a child with history of tubercular meningitis'*. The Internet Journal of Pediatrics and Neonatology. 2009 Volume 12 Number 1.

Abstract

Moya Moya is a rare idiopathic progressive vaso-occlusive disease characterized by irreversible occlusion of main blood vessels to the brain as they enter into the skull. The occlusive process stimulates the development of an extensive network of enlarged basal, transcortical and transdural collateral vessels. The blockage tends to cause strokes or seizures^{1,2}. The process of narrowing of cerebral vessels seems to be a reaction of brain blood vessels to a wide variety of external stimuli, injuries or genetic defects. We present a case of progressive vasculopathy in a 10 year old girl with history of tubercular meningitis in the infancy and which is being rarely described in pediatric population in which tubercular meningitis is still very much common in this part of world.

CASE REPORT

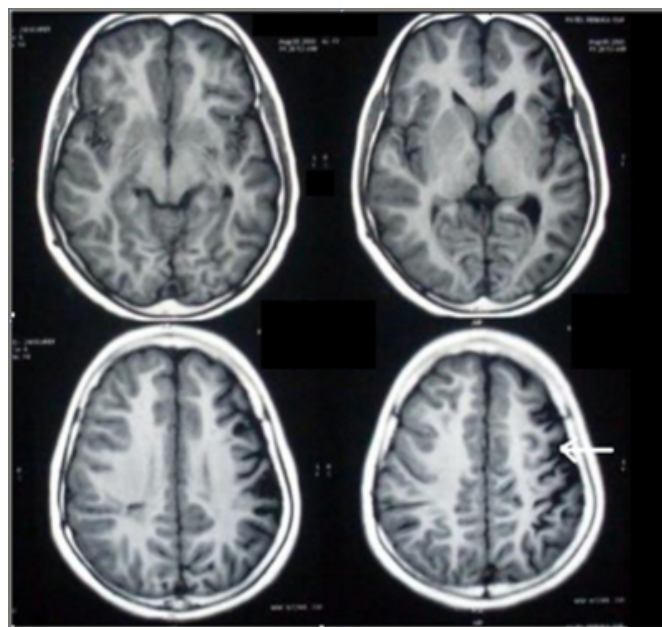
A ten year old girl, 1st by birth order with nonconsanguineous union, presented with an event of left sided focal seizure with secondary generalization lasting for 10 minutes. She had no neurological deficit and was fully conscious and without any deficits after that seizure episode.

She had h/o tubercular meningitis with hydrocephalous at the age of one year for which she was treated with antitubercular drugs for one year and required right sided VP shunt for hydrocephalous. She improved and was following with us till 5 years of age and then didn't come for follow up and had no seizure or other deficits during this period and was growing well.

She was admitted and investigated for the cause of seizure. MRI with angiography was done. It showed gliosis in left frontoparietal and insular area suggesting chronic infarcts. It also showed multiple tiny chronic infarcts in bilateral frontal areas, left centrum semiovale, basal ganglia and right thalamus. (figure 1)

Figure 1

Fig 1 MRI revealed gliosis in left frontoparietal and insular area suggesting chronic infarcts (white arrow). It also showed multiple tiny chronic infarcts in bilateral frontal areas, left centrum semiovale, basal ganglia and right thalamus.



MR angiography study revealed obliteration of distal cavernous and the supraclinoid portion of bilateral ICA, bilateral M1 segments, portion of bilateral PCAs as well with prominent collateral vessels in the circle of Willis suggesting Moya Moya syndrome secondary to tubercular meningitis which is being described rarely as a cause in

adults but very rarely in pediatric population (figure 2,3).

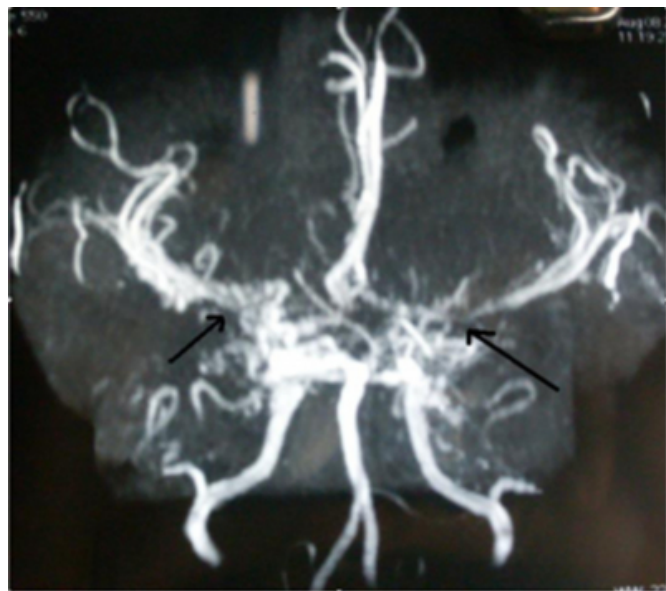
Figure 2

Fig 2;MR angiography study revealed obliteration of distal cavernous and the supraclinoid portion of bilateral ICA, bilateral M1 segments, portion of bilateral PCAs as well with prominent collateral vessels in the circle of willis suggesting Moya Moya syndrome(white arrow)

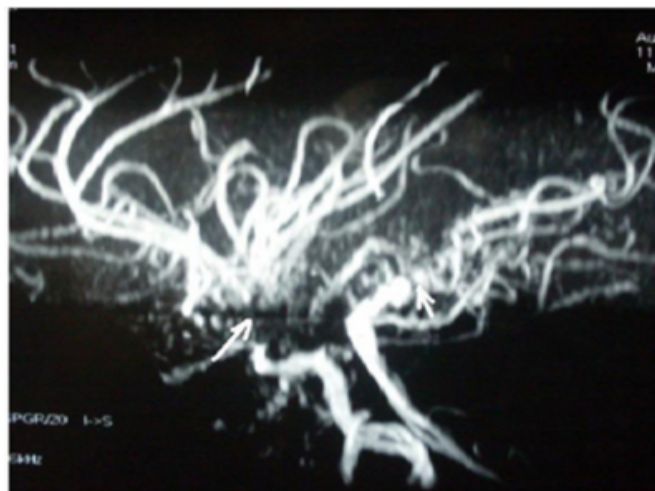

Figure 3

Fig 3 MR angiography study revealed obliteration of distal cavernous and the supraclinoid portion of bilateral ICA, bilateral M1 segments, portion of bilateral PCAs.(black arrow)



DISCUSSION

Moya Moya disease refers to a specific disease described primarily in the Asian population and characterized by progressive idiopathic stenosis and eventual occlusion of the

large cerebral arteries involving the circle of Willis^{1,2,3}. In response to stenosis, an abnormal network of small collateral vessels develops creating the “puff of smoke “ appearance on angiogram^{1,2,3}. The disease derives its peculiar name from the angiographic appearance of cerebral vessels in the disease that resembles “puff of smoke”. Kudo first reported this pattern of collateral flow in 1960². The blockage tends to cause strokes or seizures^{1,2}. There is bimodal age presentation with first peak occurring in the first decade of life, associated with cerebral infarction as progressive carotid occlusion develops. Adult patient most often present in the fourth decade with intracranial hemorrhage arising from rupture of the delicate network of collateral vessels which is mostly intraparenchymal and may be intraventricular or occasionally subarachnoid bleed². Moya Moya syndrome include the angiographic pattern typical of moyamoya disease but occurs secondary to variety of slowly progressive and occlusive cerebral vasculopathies, such as sickle cell disease and post radiation vasculopathy¹. Other conditions associated are Down syndrome,n neurofibromatosis and Williams syndrome¹. Rarely it is being described as parainfectious vascular events as complication of meningitis either bacterial or tubercular typically occurring within two weeks of disease onset and delayed vascular complications are rare^{4,5,6}. In our case report, she had tubercular meningitis at the age of 1 year and she was treated for the same. She had seizure at the age of 10 years and then diagnosed as Moya Moya syndrome, almost a decade later the tubercular meningitis which is very very rarely described in the literature.

MRI with angiography is the investigation of choice for moya moya syndrome⁷ which not only reveals areas of infarctions but also allows direct visualization of these collateral vessels as multiple small flow voids at the base of brain and basal ganglia (figure 2,3). MR angiography is used to confirm the diagnosis and to see the anatomy of the vessels involved. It typically reveals the narrowing and occlusion of proximal cerebral vessels and extensive collateral flow through the perforating vessels demonstrating the classic puff of smoke appearance.

Often nuclear medicine studies such as SPECT are used to demonstrate the decrease in blood and oxygen supply to the areas of brain involved with the disease⁸. Many operations have been described^{8,9} and the most favoured are ---- EDAS (encephaloduroarteriosynangiosis), EMS (encephalomyosynangiosis), STA-MCA(superficial

temporal to middle cerebral artery) anastomosis, Multiple burr holes⁸. These procedures can be divided into 2 groups depending on whether they involve direct or indirect anastomosis. Which of these is most effective remains controversial. Sufficient evidence suggests that surgical revascularization procedures result in some symptomatic benefits along with demonstration of improved blood flow. Direct and/or combined procedures provide improved vascularization. The concept is to develop new and more efficient means of bring blood to the starved brain bypassing the areas of blockage^{8,9}.

Conclusions: The inflammation and subsequent postinfectious autoimmune response associated with tubercular meningitis can lead to a progressive vasculopathy like moyamoya syndrome and which can rarely present many years after the infection contrary to normal belief.

References

1. Gosalakal JA. Moyamoya disease: a review. Neurol India. 2002;50(1):6-10.
2. Kitahara T, Ariga N, Yamaura A, et al. Familial occurrence of moya-moya disease: report of three Japanese families. J Neurol Neurosurg Psychiatry. 1979; 42 (3) :208-14.
3. Uchino K, Johnson A, Claiborne S, Tirschwell DL. Moyamoya disease in Washington State and California. Neurology. 2005;65:956-958.
4. T Czartoski¹, D Hallam², J M Lacy³, M R Chun⁴, K Becker¹. Postinfectious vasculopathy with evolution to moyamoya syndrome Journal of Neurology and Psychiatry 2005;76:256-259
5. Stoeter P, Voigt K. Moyamoya syndrome of tuberculous cerebral arteritis Rofo. 1976;124(6):516-9.
6. Mathew NT, Abraham J, Chandy J. Cerebral angiographic features in tuberculous meningitis. Neurology. 1970;20(10):1015-23.
7. Scott W. Atlas, MR angiography: Techniques and Clinical Applications MRI of the Brain and Spine 3rd edition, Lippincott Williams and Wilkins, Philadelphia, 2002; 1021-1023.
8. Moyamoya syndrome .Boston Neurological Foundation .http: // www. boston neurosurg.org/amphitheatre/online.html.Feb 15,1999
9. Scott RM, Smith JL, Robertson RL, et al. Long-term outcome in children with moyamoya syndrome after cranial revascularization by pial synangiosis. J Neurosurg. 2004;100(2 Suppl Pediatrics):142-9.

Author Information

Kalane Umesh, DCH, DNB

Pediatric Neurofellow, Department of Pediatric Neurology, BJWH for Children

Kulkarni Shilpa

Associate professor in Pediatric neurology, Department of Pediatric Neurology, BJWH for Children