

Cystic prostatic ductal adenocarcinoma – report of a rare case

R Kudva, V Monappa, S Sharma

Citation

R Kudva, V Monappa, S Sharma. *Cystic prostatic ductal adenocarcinoma – report of a rare case*. The Internet Journal of Urology. 2008 Volume 6 Number 1.

Abstract

Cystic prostate cancer is a rare entity with very few cases reported in the literature. Ductal adenocarcinoma, formerly known as “endometrioid adenocarcinoma”, is a clinical and histological variant of prostatic carcinoma, accounting for 0.2-1.3 % of all prostatic carcinomas. We report a case of purely cystic prostatic ductal adenocarcinoma (PDA) in an elderly male who presented with obstructive gastro-intestinal and urinary symptoms. Clinically it was mistaken for a benign prostatic cyst as serum Prostatic specific antigen (PSA) was only mildly elevated. Histopathological examination of the de-roofed cyst wall revealed a tumor with a papillary configuration. In this case report we discuss a rare tumor, the reasons for clinical misdiagnosis and the histopathological differential diagnoses.

INTRODUCTION

Malicow and Pachter first described a case of PDA in 1967 and were of the opinion that the tumor had “endometrial features” suggesting its origin from the prostatic utricle (Uterus masculinus) ¹. However numerous studies over the next few decades using light microscopic, immunohistochemical and ultra-structural methods support a prostatic origin of this tumor ². PDA is thought to arise from primary ducts of the prostate. The patients usually have obstructive urinary symptoms, but may also have hematuria.

Cystic prostatic carcinoma is a rare entity with very few cases reported in the literature ³. Review of Indian literature revealed no documented cases.

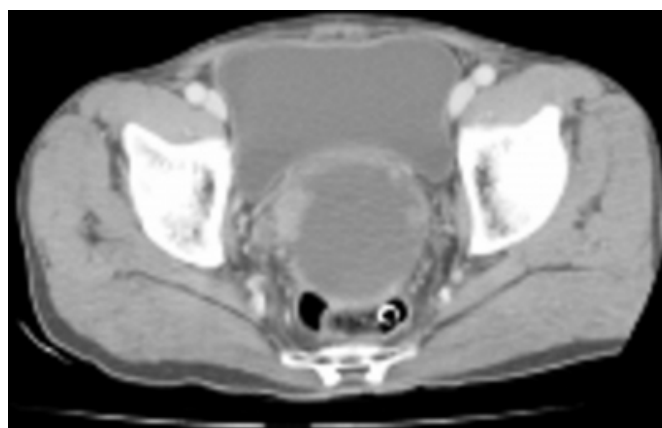
CASE HISTORY

A 73yrs old male patient presented with complaints of constipation and painful defecation of one month duration. Urine flow was decreased. Digital rectal examination revealed a large cystic, non-tender swelling. Routine investigations were within normal limits. Serum PSA level was mildly raised (8ng/ml). Clinically it was diagnosed as a benign prostatic cyst.

CECT revealed a well defined encapsulated rounded cystic lesion at posterior aspect of prostate in the midline measuring 7.5x7.4cm with multiple nodules in wall (Figure 1).

Figure 1

Figure 1: CECT showing an intraprostatic cystic lesion.



Transurethral resection of prostate (TURP) and cystoscopy guided de-roofing of the cyst was done.

Histopathologic sections from cyst roof showed a tumor composed of branching papillae with central fibrovascular cores lined by pseudostratified columnar cells showing anisonucleosis with basally located round enlarged nuclei, single prominent nucleolus and moderate amphophilic cytoplasm. Increased mitotic activity (~8-10/10hpf) was noted (Figures 2&3).

Figure 2

Figure 2: Section shows tumor with a papillary configuration (H&E, 100X).

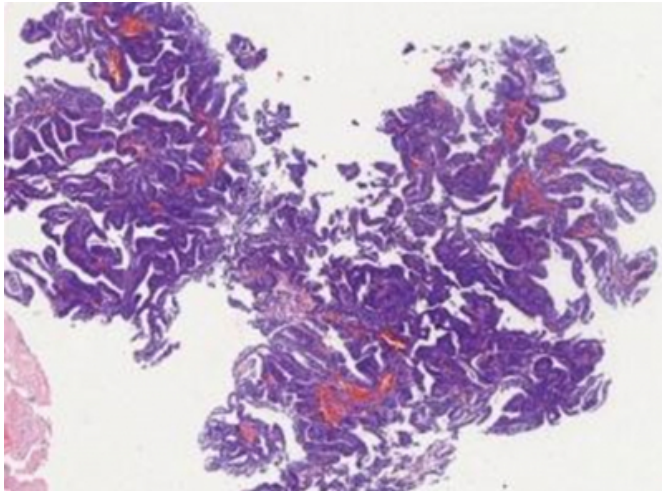
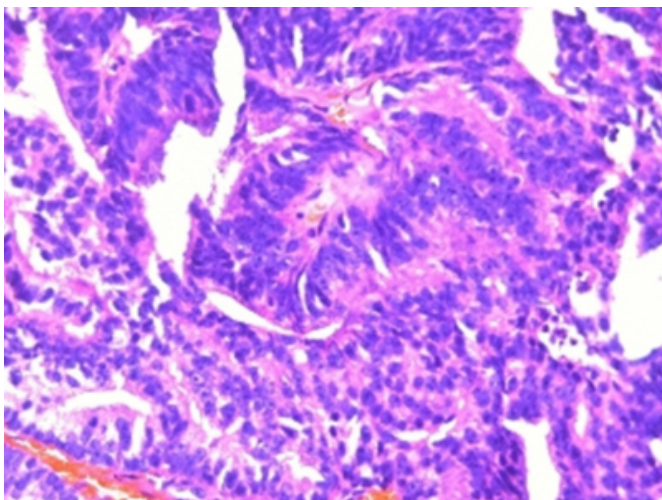


Figure 3

Figure 3: Section shows papillary tumor with nuclear stratification, prominent nucleoli and increased mitotic activity (H&E, 400X).



TURP chips showed no evidence of invasion by the tumor. A diagnosis of Prostatic ductal adenocarcinoma - cystic variant was made.

Bone scan was normal. Patient underwent bilateral orchidectomy, but was not willing for radiotherapy. His PSA levels were within normal limits at time of discharge. Patient has been on regular follow up since.

DISCUSSION

Carcinoma of the prostate is a common form of cancer in men. It is one of the leading causes of cancer related deaths in India. Conventional (acinar) adenocarcinoma represents

the large majority (~ 95%) of the prostatic cancers ⁴.

Uncommon carcinomas of prostate include squamous cell carcinoma, adenosquamous carcinoma, transitional cell carcinoma, mucinous (colloid) carcinoma, cribriform carcinoma, adenocarcinoma with signet ring differentiation, adenoid cystic-like carcinoma, small cell carcinoma, sarcomatoid carcinoma, carcinosarcoma, and PDA .

Pure ductal adenocarcinoma's occur exclusively in elderly men, with a reported incidence of 0.2-0.8% of all prostatic carcinomas ⁵. They can also be found coexisting with conventional acinar carcinoma's ²⁵⁶.

Certain features described in the past as specific for PDA include : 1) Low or Normal serum PSA levels except in metastatic disease. This can be attributed to growth within pre-existing ducts or urethra providing a route of egress of cellular secretions. This may be the reason for misdiagnosis, as observed in our case. 2) Clinical behaviour: usually detected earlier due to the obstructive symptoms. Various studies have however revealed conflicting results. In our case patient also had obstructive gastro-intestinal symptoms (constipation). 3) Unique location within large ducts or urethra. PDA has been also observed to arise in peripheral ducts ².

Grossly the tumor is seen as friable, exophytic, urethral lesion with polypoid or papillary configuration. Our case presented as a cystic mass.

Cystic prostatic cancer is a rare entity with very few cases reported in the literature. The cystic appearance of the peripheral prostatic zone appears to be a distinct clinical and morphological entity of PDA's ³, as was observed in the present case.

Masood et al observed that cytology sample of PDA showed clusters of malignant cells with overlapping of nuclei and having a pseudopapillary pattern along with flat sheets of cells ⁷. In our case cytology was negative.

Histologically PDA has a distinctive papillary architecture with papillary fronds supported by true fibrovascular cores and lined by tall columnar cells showing nuclear pseudo-stratification mimicking endometrial carcinoma. Other variants include cribriform pattern, individual gland pattern, solid pattern and carcinomatous component in carcinosarcomas ⁸⁹. Although not usually graded they are usually equivalent to Gleason's pattern 4/5 depending on the absence/ presence of comedo necrosis ⁹.

Immunohistochemically (IHC), PDA's are positive for Prostatic specific antigen (PSA) and Prostatic acid phosphatase (PAP), Androgen receptor (AR) and have higher Ki67 values than conventional acinar carcinomas⁵. AMACR (Alfa methyl-acyl CoA Racemase) staining is comparable with conventional acinar adenocarcinoma⁸.

The histologic differential diagnosis include prostatic intraepithelial neoplasia (PIN) and intraductal carcinoma (a well circumscribed, malignant lumen spanning lesion of prostatic epithelial origin, with intact basal cell layer and found in close proximity to invasive cancer).

Table 1: Differential diagnosis of PDA having a ductal morphology⁸⁹.

Direct extension from rectal adenocarcinoma and Transitional cell carcinoma of prostatic duct are negative for PSA and PAP⁹. Prostatic type urothelial polyp, unlike PDA has bland appearing cells and two layered epithelium.

The natural history of PDA is conflicting with initial reports suggesting an indolent tumor. Subsequent reports imply an aggressive tumor with poor five year survival rate of 15-43%⁶⁹. The initial hypothesis of endometrial origin led clinicians not to use androgen deprivation. Case reports of patients responding to anti-androgen therapy were later described. Because the extent of disease is often underappreciated due to low/normal PSA levels, caution should be exercised in the staging of this tumor.

Thomas et al¹⁰ observed that post surgical external beam radiotherapy was a useful adjunct to radical prostatectomy and androgen deprivation, with better survival rates.

To conclude, purely cystic PDA is a rare entity. This case was clinically mistaken as a benign prostatic cyst. Serum PSA levels need not be elevated, unlike conventional acinar adenocarcinoma. Histologically it shows presence of true papillae with central fibrovascular cores and absent basal layer. The conflicting behaviour of this tumor with observed poor outcomes necessitates aggressive management with surgery, hormone deprivation and external beam

radiotherapy. Knowledge of this tumor is thus important as proper diagnosis and timely intervention can improve patient survival rates.

ACKNOWLEDGEMENT

We would like to acknowledge Prof. Joseph Thomas and Dr Arun Chawla, Associate professor, Department of Urology, Kasturba Hospital, Manipal for providing us with all the necessary clinical data.

CORRESPONDENCE TO

Dr. Vidya Monappa Assistant Professor Department of Pathology Kasturba Medical College Manipal – 576104 Karnataka, India E-mail : vidsdr@yahoo.co.in Telephone No.: Office : (0820)9222492 Residence : (0820)9222584 Fax NO. : (0820)2570061

References

1. Melicow MM and Patcher M R. Endometrial carcinoma of the prostatic utricle (uterus masculinus). *Cancer* 1976;20:1715–21.
2. Bock B J, Bostwick G. Does prostatic ductal adenocarcinoma exist? *Am J Surg Pathol* 1999;23:781–89.
3. Zini L, Villers A, Leroy X, Ballereau C, Lemaitre L, Biserte J. Cystic prostatic carcinoma: a clinical entity of ductal carcinoma. *Prog Urol*.2004;14(3):411-3
4. Randolph TL. et al. Histologic variants of adenocarcinoma and other carcinomas of prostate: pathologic criteria and clinical significance. *Modern Pathology*.1997;10(6):612-629.
5. Oxley JD, Abbott CD, Gillatt DA, Maciver AG. Ductal carcinomas of the prostate: a clinicopathological and immunohistochemical study. *British Journal of Urology*.1998;81:109-115
6. Dube et al. Prostate adenocarcinoma of duct origin. *Cancer*.1973; 32:402-409.
7. Masood S. et al. Fine needle aspiration cytology of papillary endometrioid carcinoma of the prostate. The grooved nucleus as a cytologic marker. *Acta Cytologica* .1991;35(4):451-455
8. M Pickup, T H Van der Kwast. My approach to intraductal lesions of the prostate gland. *Journal of Clinical Pathology*. 2007;60:856-865
9. Saks WA et al. Prostatic intraepithelial neoplasia. In: Eble JN, Sauter G, Epstein JI, Sesterheim IA, editors. *World Health Organisation classification of tumors- Tumors of urinary system and male genital organs*. Lyon :IARC press; 2004 . p.193-198
10. Eade TN, Al-Saleem T, Horwitz EM, Buyyounouski MK, Chen DYT and Pollack A. Role of Radiotherapy in Ductal (Endometrioid) Carcinoma of the Prostate. *Cancer*. 2007; 109(10): 2011–2015.

Author Information

Ranjini Kudva, MD

Professor

Vidya Monappa, MD, DNB

Assistant Prof.

Swathi Sharma, MBBS

Post-graduate student