

Localized Amyloidosis Of The Upper Respiratory System: Our Experience Of Three Cases And Review Of Article

E Tas, E Sahin, S Vural, Y Eren, H Kemal Turkoz, A Okan Gursel

Citation

E Tas, E Sahin, S Vural, Y Eren, H Kemal Turkoz, A Okan Gursel. *Localized Amyloidosis Of The Upper Respiratory System: Our Experience Of Three Cases And Review Of Article*. The Internet Journal of Head and Neck Surgery. 2006 Volume 1 Number 1.

Abstract

Objective: To discuss the presentation, evaluation and the treatment options of localized amyloidosis affecting the upper respiratory system.

Patients and Method: We conducted a retrospective study with analysis of amyloidosis by histopathologic investigations. We present three cases of localized amyloidosis; nasopharyngeal, oropharyngeal and laryngeal, with the review of literature.

Results: Localized amyloidosis of the upper respiratory tract is a rare condition. The cases presented were diagnosed by histopathologic investigations. All of them were found to be free of systemic disease. They treated by surgical excision. The follow-up period ranged from two to five years. They are still being observed periodically.

Conclusion: Histopathologic investigation is the gold standard for diagnosis. Simple surgical excision is the treatment for localized amyloidosis. Long term monitoring for local recurrences or subsequent development of systemic disease is mandatory.

The work was done in Bakirkoy Dr. Sadi Konuk Education and Research Hospital.

INTRODUCTION

Amyloidosis is an entity defined by the presence of extracellular deposits of abnormal protein fibrils (1). These deposits have a characteristic apple-green birefringence with polarized light after staining with Congo red (2).

The precise etiology and pathogenesis of amyloidosis is unknown (3). It may be localized or systemic, with primary or secondary forms (4).

Amyloidosis in the head and neck is a rare and benign condition that usually takes the form of localized amyloidosis. Localized amyloidosis in the head and neck can involve the orbit, sinuses, nasopharynx, oral cavity, salivary glands, and mostly larynx and thyroid.

The patients with systemic forms of amyloidosis have short survival, whereas those with the localized form have an excellent prognosis (5, 6). Once the diagnosis has been made, an extensive workup for systemic amyloidosis should be

undertaken. The absence of systemic amyloidosis offers a much more favorable prognosis, and may be treated with simple surgical excision.

In this article 3 cases of amyloid accumulation which were localized in the nasopharynx, oropharynx and larynx without systemic involvement, were presented, and related literature was reviewed.

PATIENTS AND METHOD

We conducted a retrospective study with analysis of amyloidosis by histopathologic investigations. We present three cases of localized amyloidosis; nasopharyngeal, oropharyngeal and laryngeal, that came to our ORL Department between the years 2001-2004, with the review of literature. An initial diagnosis of amyloidosis, made based on clinical suspicion, was confirmed by histopathological evaluation. After extensive investigations were carried out for all patients to exclude primary or secondary systemic amyloidosis, the diagnosis of localized amyloidosis was rendered.

CASE 1

A 68-year-old male presented with 1 year history of moderate hearing loss in his left ear, nasal obstruction and progressive snoring. Physical examination revealed serous effusion in the left ear. Nasal endoscopy and oral examination demonstrated a broad-based polypoidal mass which was originating from the left lateral wall of the nasopharynx, and extending to the oropharynx behind the posterior plica of the left tonsil. Pure-tone audiometry showed a moderate conductive hearing loss in the left ear, and the tympanometric impedance curve was flat in the same ear. He had no other complaints, and his review of systems was normal. A biopsy was performed under local anesthesia. Histological examination of the lesion showed eosinophilic amorphous extracellular nodular deposits in the subepithelial region on hematoxylin and eosin stain. Then congo red stain revealed salmon pink coloration with regular light microscopy and apple-green birefringence with polarization, which was characteristic for amyloidosis. We referred the patient to the department of internal medicine for an extensive testing to confirm that there was no systemic involvement. Then the diagnosis of localized amyloidosis was rendered. A 4x2 cm, firm, rubbery mass was removed through transoral and endoscopic transnasal approaches together, and a tympanostomy tube was placed on the left ear. No further treatment was given, and the patient continues to be observed closely at 6-month intervals. In his fifth year he is still free of illness, and has no complaints.

CASE 2

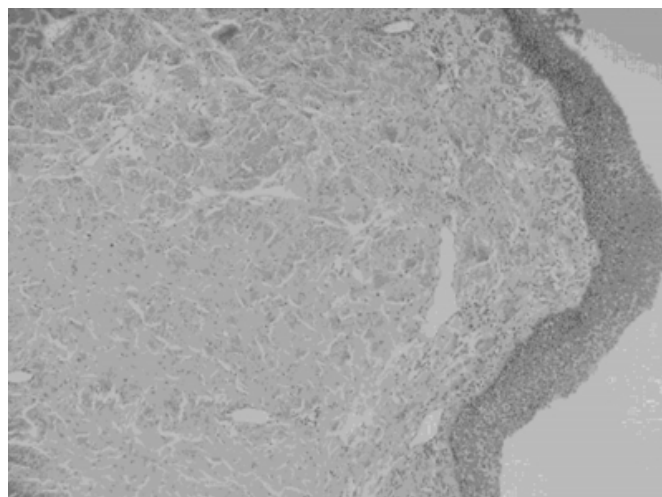
A 26-year-old woman came to us with 5-month history of odynophagia, dysphagia and a foreign body sensation in her throat. On her oropharyngeal examination a yellowish, ragged looking mass with 4x5cm in size was seen in her posterior pharyngeal wall. The endoscopic examinations of nasopharynx and larynx were normal. A biopsy from the mass was taken under local anesthesia. The hematoxylin and eosin stain showed eosinophilic amorphous material which was not definite for amyloidosis. After the histopathology revealed characteristic staining on Congo red, and an extensive workup, made by a physician in the internal medicine department, for systemic involvement was negative, the diagnosis of localized amyloidosis was rendered. A simple surgical excision of the mass over the buccopharyngeal fascia through a transoral approach was performed. There was no evidence of recurrence as we followed up to the present in her third year. She is still being observed periodically.

CASE 3

A non-smoker 38 year-old woman complained of gradually progressive hoarseness for 4 months. She had no other complaints. Direct laryngoscopy showed yellowish, non-ulcerous irregular mass arising from the right aryepiglottic fold with extension to the epiglottis. Both true vocal cords were normal and mobile. Direct microlaryngoscopy, with biopsy for diagnosis, was performed. A hematoxylin and eosin stain showed eosinophilic amorphous material which made us suspicious of amyloidosis (figure).

Figure 1

Figure: Histopathological examination of the slides stained with hematoxylin and eosin. Nonkeratinising squamous larynx epithelium on the surface and eosinophilic staining amorphous and diffuse material underneath the epithelium. There is a slight, nonspecific lymphocytic infiltration around the subepithelial capillaries.



Therefore we used congo red staining. The biopsy specimen revealed an amorphous, eosinophilic hyaline material that exhibited apple-green birefringence when stained with congo red, consistent with amyloidosis. She underwent extensive testing for the presence of systemic amyloidosis in the department of internal medicine. No signs of systemic amyloidosis were found. Then we decided to excise the lesion totally. The deposits were superficially excised as completely as possible and the normal structure of the larynx was preserved. Since this surgery was performed, the patient has remained asymptomatic for 2 years.

In the department of internal medicine the following investigations were carried out for all patients to exclude primary or secondary systemic amyloidosis: full blood count, ESR, urea and electrolytes, liver function tests, serum calcium, serum and urine protein electrophoresis, chest x-

rays, bone marrow, abdominal fat aspiration and rectal biopsies.

DISCUSSION

Amyloidosis in the head and neck is a rare and benign condition that usually takes the form of localized amyloidosis (3). Amyloid tumors are usually encapsulated and firm and appear as a homogeneous, pale yellow, waxlike mass lying beneath intact mucosa. The diagnosis is made histologically. The protein stains pink with hematoxylin and eosin and metachromatically with methylviolet or crystal violet stains; thioflavin T produces an intense yellow-green fluorescence, although false-positive staining is common. The gold standard for diagnosis is congo red stain. When stained with Congo red, eosinophilic extracellular deposits of protein fibrils exhibits apple-green birefringence on polarized light microscopy (1a, 1b, 2, 4). After the suspicion of amyloidosis on hematoxylin and eosin stain, we used congo red stain for the definite diagnosis in all patients.

Careful examination is necessary to distinguish localized amyloidosis from systemic amyloidosis. To exclude systemic amyloidosis some invasive procedures like aspiration of abdominal fat, bone marrow biopsy and rectal biopsy, have been suggested (3, 7, 8). The absence of Congo red staining of specimens from either of abdominal fat and rectal biopsies establishes that the amyloidosis is not systemic (8). However, as the diagnostic yield is very low, some authors believe that invasive investigations are not indicated (9). In all our cases bone marrow, abdominal fat aspiration and rectal biopsies were performed to exclude systemic involvement, and all of them were found to be negative. Specific organ involvement may also be excluded by laboratory or radiologic studies (3). Serum or urine "Bence Jones proteins" will be found in up to 88% of patients with primary systemic amyloidosis and 100% of patients with multiple myeloma-associated systemic amyloidosis (10). An echocardiogram can be obtained to evaluate the myocardium for signs of amyloidosis. Dynamic magnetic resonance imaging, Tc-99m phosphate radionuclide imaging, and 123I serum amyloid P scintigraphy may be useful in evaluating amyloidosis (11, 12).

The importance of a complete systemic workup for amyloid is stressed because this can markedly change the expected morbidity and mortality (5, 6). Involvement of vital organs, like heart, kidney, brain, vascular walls and gastrointestinal tract, lead to serious organ dysfunction in both primary and

secondary systemic forms, that shortens the expectancy of survival, and cardiac or renal failure is the most frequent causes of death (3, 6, 10).

Treatment for localized amyloidosis is primarily surgical. Repeated operation may be indicated for residual or multifocal disease (5, 13, 14). Simpson et al have suggested less recurrence following laser excision of localized amyloidosis (8). Because localized amyloidosis is a disease of great rarity and slow progression for which spontaneous regression is known to occur, it is difficult to predict the outcome (15). Furthermore, bleeding may be a major complication in treating patients with localized amyloidosis by excision. The loss of vascular integrity, which is due to the amyloid infiltration of the blood vessels, causes bleeding (3). In none of our patient's surgery bleeding had occurred. We treated all of our patients by surgical excision. All of them are symptom free up to date and they are following-up periodically.

There has been no report of local amyloidosis progressing to systemic amyloidosis (3). In a review of 236 cases of amyloidosis, Kyle and Bayrd (6) found that only 22 cases (9%) were localized, and none of these patients developed systemic disease in a 10-year follow-up. Similarly Kerner et al showed that localized amyloidosis did not evolve to primary or secondary systemic amyloidosis or multiple myeloma (5). Nevertheless, all patients with localized disease should be followed up for any evidence of systemic amyloidosis or recurrence (15).

Amyloidosis affecting the head and neck, as benign localized form, mostly involves larynx (3, 16, 17). In descending order of frequency within the larynx, amyloidosis affects the false vocal cords, aryepiglottic folds, and subglottis. The deposits are usually multifocal, and the trachea and base of tongue are the most common extralaryngeal locations (7, 16). Therefore it's recommended to do a complete endoscopic examination of the entire respiratory tract given the propensity for multifocal laryngeal amyloidosis (17).

Localized amyloidosis may cause various complaints according to its location and size. In laryngeal amyloidosis hoarseness is the most common presenting symptom (7). Dyspnea is occasionally reported. Hemoptysis, dysphagia, throat fullness, and choking sensation are less seen. Laryngeal amyloidosis is a slowly progressive disease, and therefore symptoms are often chronic in nature.

Laryngoscopy typically reveals a non-ulcerous, waxy, translucent, yellow or yellow-gray mass (7). Urine and serum electrophoresis and immunoelectrophoretic studies can be done as initial workup in localized laryngeal amyloidosis (16).

Treatment of laryngeal amyloidosis is surgical resection. This can be done endoscopically or by open techniques such as thyrotomy with excision, supraglottic laryngectomy, or, rarely, tracheal resection for extensive diseases (7). Michaels and Hyams reported a case in which over 80% of the airway was obstructed by amyloidosis, therefore a laryngectomy was required (9). Neither radiotherapy nor medical management is effective (7). Long-term monitoring is important because recurrence rates as high as 50% have been reported (16). O'Halloran and Lusk recently reported a relatively rapid recurrence of laryngeal amyloidosis after laryngofissure (17).

Localized amyloid tumors of the nasopharynx are exceedingly rare, and only a few cases have been reported to date (15, 18). Presenting complaints include nasal obstruction, recurrent epistaxis, postnasal discharge, and ear problems. Nasopharyngeal amyloidosis is generally a slow-growing, benign tumor, but it may be locally aggressive and produce osteolysis, like in Hegarty and Rao's patient. They reported a nasopharyngeal amyloidosis case whose skull base was involved (19).

Amyloid tumors in the nasopharynx are difficult to treat and commonly recur despite surgical excision, which usually consists of a transpalatal approach (18). In Dominguez's article a young patient's treatment was surgical and successful during 9 months of follow-up (18).

CONCLUSION

Localized amyloidosis of the upper respiratory tract is a rare condition that must be differentiated from systemic amyloidosis. A thorough evaluation, including abdominal fat or rectal biopsy, is essential in every patient to identify any systemic involvement. Amyloid tumors are difficult to treat and can reoccur, thus requiring a long follow-up period. There has been no report of malignant change or progression to systemic form in amyloid tumor. Finally, the absence of systemic amyloidosis offers a much more favorable prognosis and may be treated with simple surgical excision.

Localized amyloidosis of the head and neck is a rare and benign process which must be differentiated from the lethal

form called systemic amyloidosis.

Also long term monitoring for local recurrences or subsequent development of systemic disease is mandatory.

We want to emphasize these two important points.

Simple surgical excision could be enough for treatment in the absence of systemic amyloidosis and in this case the prognosis would be better.

References

1. a) Glenner CG. Amyloid deposits and amyloidosis: The betafibriloses (first part). *New Engl J Med* 1980;302:1283-92.
- b) Glenner CG. Amyloid deposits and amyloidosis: The betafibriloses (second part). *New Engl J Med* 1980;302:1333-43.
2. Cohen AS. Preliminary chemical analysis of partially purified amyloid fibrils. *Lab Invest* 1966;15:66-83.
3. Nandapalan V, Jones TM, Morar P, et al: Localized amyloidosis of the parotid gland: A case report and review of the localized amyloidosis of the head and neck. *Head Neck* 1998;20:73-8.
4. Cohen AS, Calkins E. Electron microscopic observations on a fibrous component in amyloid of diverse origins. *Nature* 1959;183:1202-3.
5. Kerner MM, Wang MB, Angier G, et al. Amyloidosis of the head and neck: A clinicopathologic study of the UCLA experience, 1955-1991. *Arch Otolaryngol Head Neck Surg* 1995;121:778-82.
6. Kyle RA, Bayrd ED. Amyloidosis: Review of 236 cases. *Medicine* 1975;54:271-99.
7. Mitrani M, Biller HF. Laryngeal amyloidosis. *Laryngoscope* 1985;95:1346-7.
8. Simpson GT, Strong MS, Skinner M, et al: Localized amyloidosis of the head and neck and upper aerodigestive and lower respiratory tracts. *Ann Otol Rhinol Laryngol* 1984;93:374-9.
9. Michaels L, Hyams VJ. Amyloid in localized deposits and plasmacytomas of the respiratory tract. *JPathol* 1979;128:29-38.
10. Gertz MA, Kyle RA. Primary systemic amyloidosis: A diagnostic primer. *Mayo Clin Proc* 1989;64:1505-19.
11. Burke TS, Tatum JL, Fratkin MJ. Accumulation of Tc-99m MDP in amyloidosis involving the tongue. *Clin Nucl Med* 1990;15:107-9.
12. Sawkins PN, Lavender JP, Pepys MB. Evaluation of systemic amyloidosis by scintigraphy with 123I-labeled serum amyloid P component. *New Engl J Med* 1990;23:508-13.
13. Heinritz H, Kraus T, Iro H. Localized amyloidosis in the area of the head and neck. A retrospective study. *HNO* 1994;42:744-9.
14. Raymond AK, Sneige N, Gatsakis JG. Amyloidosis in the upper aerodigestive tracts. *Ann Otol Rhinol Laryngol* 1992;101:794-6.
15. Panda NK, Sharma SC, Mann SBS, et al: Localized amyloidosis of the nasopharynx. *Ear Nose Throat J* 1994;73:335-6.
16. Lewis JE, Olsen KD, Kurtin PJ, et al. Laryngeal amyloidosis: a clinicopathologic and immunohistochemical

review. Otolaryngol Head Neck Surg 1992;106:372-7.

17. O'Halloran LR, Lusk RP. Amyloidosis of the larynx in a child. Ann Otol Rhinol Laryngol 1994;108:339-40.

18. Dominguez S, Wienberg P, Claros P, et al: Primary

localized nasopharyngeal amyloidosis. A case report. Int J Pediatr Otorhinolaryngol 1996;36:61-7.

19. Hegarty JL, Rao VM: Amyloidoma of the nasopharynx: CT and MR findings. AJNR 1993;14:215-8.

Author Information

Ebru Tas, M.D.

Rota-KBB ORL Clinic

Ethem Sahin, M.D.

ORL Department, Maltepe University School of Medicine

Sukran Vural, M.D.

ORL Department, Bakirkoy Dr. Sadi Konuk Education and Research Hospital

Yusuf Eren, M.D.

ORL Department, Bakirkoy Dr. Sadi Konuk Education and Research Hospital

H. Kemal Turkoz, M.D.

Pathology Department, Okmeydani Education and Research Hospital

A. Okan Gursel

Assistant Professor, Clinical Director of ORL Department, Fatih Sultan Mehmet Education and Research Hospital