

# Single Surgeon Single Incision Laparoscopic Gynaecological Surgery (Solo SILS): Can This Be The Future Approach In Laparoscopic Surgery?

Y Feng, Y Ng, Z Huang

---

## Citation

Y Feng, Y Ng, Z Huang. *Single Surgeon Single Incision Laparoscopic Gynaecological Surgery (Solo SILS): Can This Be The Future Approach In Laparoscopic Surgery?*. The Internet Journal of Gynecology and Obstetrics. 2016 Volume 20 Number 1.

DOI: [10.5580/IJGO.39869](https://doi.org/10.5580/IJGO.39869)

## Abstract

**Introduction:** Single incision laparoscopic gynaecological surgery (SILS) has been recognized to be a safe and feasible approach in well-selected gynaecological procedures such as adnexal surgeries, myomectomies and hysterectomies. With the advent of new instruments and improvement of surgical techniques, SILS is likely to become one of the mainstream laparoscopic techniques for appropriately selected gynaecological surgeries.

**Objective:** We aim to explore the feasibility of performing a single surgeon SILS (solo SILS) in a 46 year old nulliparous woman with a 6 cm right ovarian endometriotic cyst.

**Methodology:** Coupled with the use of a self-retaining laparoscope holding system and the uterus maintained in fixed uterine anteversion by using a curette and volsellum tied together with a piece of gauze, clamped down with sponge forceps to the operating table, the surgery was completed in 76 minutes with minimal blood loss.

**Results:** Post-operatively the patient recovered well and was discharged on the same day. At three month's postoperative review, she was particularly pleased with the cosmetic outcome and had recovered fully.

**Conclusion:** This case report illustrated the plausibility of performing solo SILS in appropriately selected patients who are likely to obtain maximum benefits through such an approach. Benefits of solo SILS include excellent cosmesis to patients, shorter recovery time and improved ergonomics for the performing surgeon.

## INTRODUCTION

In recent years, we have seen an increase in published reports describing the feasibility and safety of single incision laparoscopic surgery (SILS) in various gynaecological procedures such as adnexal surgeries, myomectomy and hysterectomy [1-3]. Moreover, the use of SILS has also been described and performed safely in gynaecological emergency settings for ectopic pregnancies [4] and ovarian torsion [5]. However, SILS still remains technically demanding, requiring a certain level of visual-spatial orientation and laparoscopic surgical skills, to perform effectively and safely.

Over the years, with improved innovations in instruments, cameras and scopes as well as the refinement of surgical techniques, challenges of performing SILS have been

gradually resolved. With the advent of innovative port designs, pre-bent instruments, retraction devices, the use of intra-abdominal sutures for traction, novel camera holding systems and innovative surgical techniques has increased the feasibility of performing SILS in a routine fashion, as well as enabled solo SILS. Our centre explored the possibility of a single-surgeon single-port laparoscopic gynaecological surgery (solo SILS) as illustrated in this case report. We are presenting this case to determine the feasibility of performing solo SILS in a benign gynaecological case of intermediate complexity. There have been reports of experienced surgeons using sole SILS for appendectomy[6], gastrectomy[7], nephrectomy[8]. But to our knowledge, this is the first report in literature on solo SILS in gynaecology.

## CASE SUMMARY

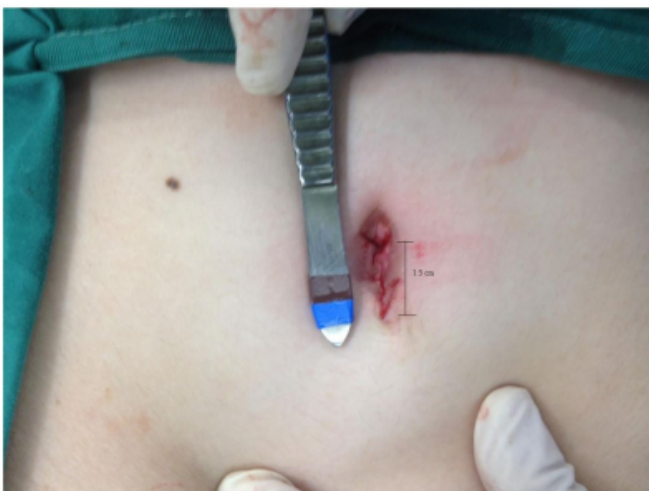The patient, a 46 year old married, nulliparous Chinese lady was referred to our hospital for symptoms of bloatedness and lower abdominal discomfort in November 2011. She had regular monthly menses with normal flow. Her body mass index was 20.5. Pelvic examination was unremarkable however pelvic ultrasound demonstrated a 6cm right ovarian cyst. Her serum CA-125 was mildly elevated at 35.9. Single incision laparoscopic right salphingo-oophorectomy was offered to the patient.

## Operative Details

The patient was placed in a lithotomy position under general anaesthesia. A 1.5cm longitudinal incision was made at the umbilicus (Figure 1). The abdomen was insufflated using a SILS multi-channels port (Covidien, USA), via Hasson's open entry method. To achieve solo surgery, a self-retaining video camera holding system (FISSO endoscope holding system, Switzerland) was used to secure the 5mm 0 degree endoscope (Olympus, Paris, France), thus eliminating the need for an assistant to hold the camera (Figure 2, Figure 3). The mechanical camera holder is made of stainless steel and high quality light alloy, which can be steam-sterilized at 134 degrees Celsius. It comprises of a rail clamping base, height-adjustable columns, articulated arms and a head component for the attachment of the video camera (Figure 4). The various components can be assembled and adjusted according to the needs of the surgery and surgeon's requirements.

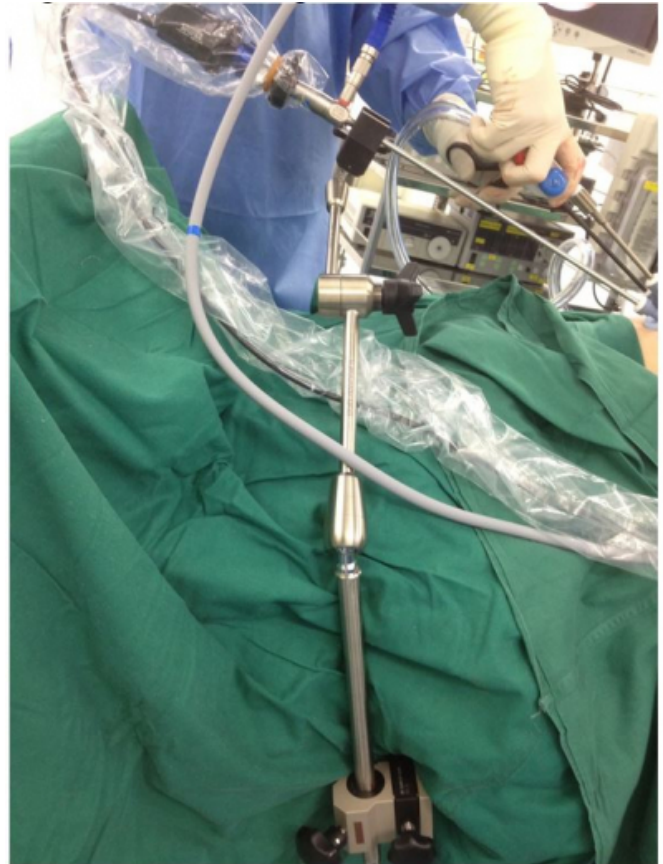### Figure 1

1.5cm longitudinal incision was made at the umbilicus



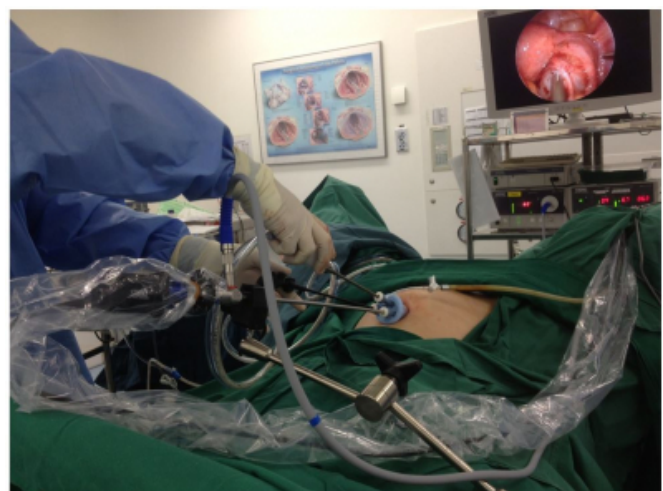### Figure 2

The set-up of the laparoscope holding system which eliminates the need for surgical assistance




### Figure 3

Single surgeon SILS (solo SILS) – note the placement of the laparoscope holding system, which frees the need for surgical assistance and allow the surgeon to use other instruments to perform salpingo-oophorectomy



**Figure 4**

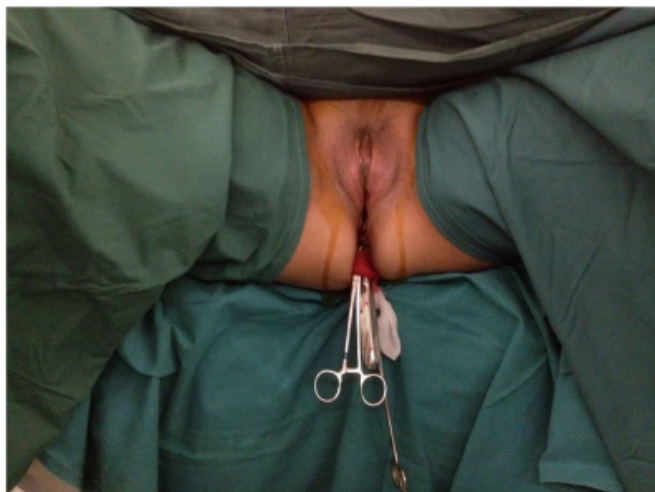Various components of camera/laparoscope holding equipment



The uterus was maintained in fixed anteversion using a curette and volsellum tied together with a piece of gauze, clamped down with sponge forceps to the operating table, hence removing the need for an assistant to manipulate the uterus (Figure 5).

**Figure 5**

Fixed anteversion of uterus obviating the need for surgical assistance



Intra-operative findings upon insertion of the video camera revealed a right ovarian cyst 6cm in diameter. The right ovary was adherent to the ovarian fossa and the posterior right lateral uterine wall. Inadvertent cyst rupture during dissection released thick chocolate fluid, consistent with an endometriotic cyst.

The ovarian cyst and ovary was released from the ovarian

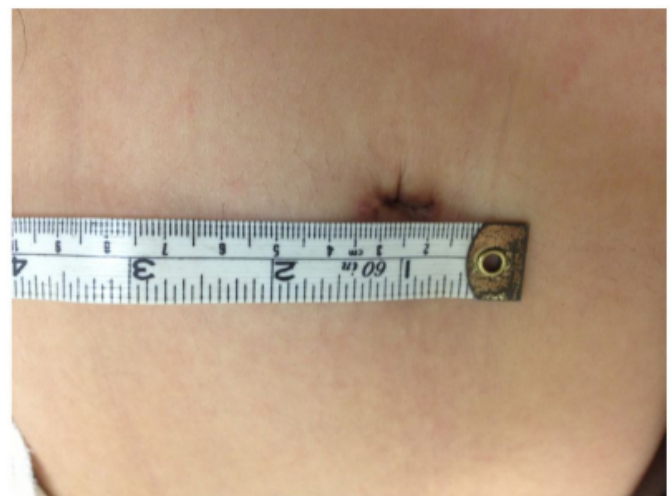
fossa carefully to minimize risk of injury to the ureter. As the uterus was maintained in fixed anteversion, traction of the right adnexa was achieved by a pre-bent alligator. Right salphingo-oophorectomy was completed using Sonosurg (Olympus Surgical & Industrial Inc, USA), a multifunction laparoscopic instrument. Blood supply to the ovarian and infundibulopelvic ligament was obliterated and the ligaments were cut. The specimen was removed directly via the 15 mm incision without the need for endobag. Histology of the specimen confirmed the diagnosis of a right endometriotic cyst.

## RESULTS

The procedure was successfully carried out without intra-operative complication or the need for conversion to multiple ports laparoscopy or open surgery. From incision to umbilical closure, the procedure took 76 minutes and the overall blood loss during the operation was minimal. Postoperatively, the patient was given routine oral analgesia and her pain score was 2 out of 10 based on a verbal numeric rating scale [9]. She was discharged on the same day post procedure. There were no early postoperative complications and the patient reported a high satisfaction score on direct questioning on the appearance of the scar and general well-being three months after the operation. She was particularly pleased with the cosmetic outcome of the surgery. (Figure 6, Figure 7) The surgeon performing the solo surgery also reported improved ergonomics with the use of the camera holding system.

**Figure 6**

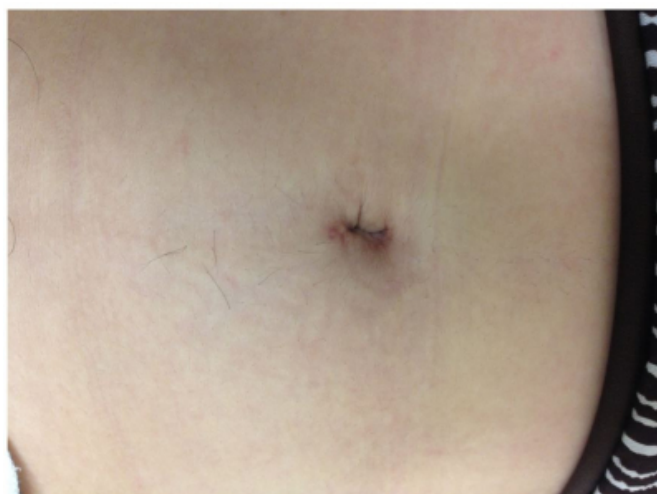Immediate post-op single umbilical incision





**Figure 7**

Final scar appearance after a year



## DISCUSSION

### **Advantages of SILS: improved cosmesis and reduced pain**

One of the main advantages of SILS over conventional laparoscopic surgery is the near scar-less postoperative outcome. Immediate post-operative pain has also been shown to be comparable or even reduced given that there is only one single incision compared to the multiple incisions made in conventional laparoscopic surgery (CLS) [9, 10]. The superior cosmetic outcome of SILS is significant and should be pursued as patients do value improvements in post-operative scarring [9]. In two surveys by Bucher et. al. and Rau et. al., patients were given the options to choose among SILS/SPS (Single Port Surgery), CLS, NOTES (Natural Orifice Transluminal Endoscopic Surgery) and open surgery after being informed adequately about the limitations and benefits of each surgical approach. The results of both surveys showed that given equal surgical risks, majority of patients, in particular younger patients, preferred a virtually scar-less approach to surgery, which is offered by SILS. The umbilical scar is usually well hidden within the umbilicus [11, 12]. It is thus worthwhile to explore this innovative approach in gynaecological surgery.

### **Minor to intermediate adnexal gynaecological surgery are particularly suitable for SILS approach**

Loss of triangulation, in-line viewing and instrument crowding are some of the challenges in SILS [13]. With only one site – the umbilicus – in which the port can be placed to achieve ‘scar-less’ surgery, surgeon and assistant often have

to operate in uncomfortable, non-ergonomical positions. Long operative times and steep-learning curves add further arguments against SILS. Although SILS has been shown to be more technically challenging [14] and more highly associated with poorer performance and increased surgeon workload than CLS [15], it is reasonable to note that the extent of technical difficulties in SILS are not homogenous across all types of gynaecological surgeries. The learning curve for SIL adnexal surgery has been shown to be quite rapid [1]. Adnexal pathologies are particularly ideal targets for SILS because they are readily exposed and examined without interference from other organs with a uterine manipulator. Studies have illustrated that adnexal surgeries have comparable operating time to CLS [16, 17]. There is also less post-operative pain in SIL adnexal surgeries [18]. With the appropriate case selection and experienced hands, operative time, outcome, post-operative pain and complication rates between the two surgical approaches are comparable [19]. In this report, we have demonstrated that single-surgeon single-port approach is feasible and suitable for gynaecological adnexal surgery of intermediate complexity. Ergonomic benefits of solo SILS Camera/scope holding systems are not a new concept in conventional laparoscopic surgery. They have been used primarily in minimally invasive biliary [20, 21], colon surgery [22] and gynaecological surgeries [23]. Some of the holding systems developed for use in CLS include mechanical scope holders, robotic scope holders (EndoAssist) and automated endoscopic system for optimal positioning (AESOP) – a voice-controlled optic holder. Robotic arm-assisted CLS has been reported to have shorter [20] to comparable [23] operating times similar to human-assisted CLS, and is as efficient and safe [21], improves surgeon comfort by improving image stability and providing the surgeon full control over laparoscope handling [24].

Unfortunately, literature is sparse on the concept of solo surgery in SILS. There has only been reported on single-port, single-operator appendectomy [6], gastrectomy [7], nephrectomy [8]. SILS remains a relatively new approach in the field of minimally invasive surgery and surgeons are still in the midst of determining the feasibility and safety of various novel approaches in SILS.

In our experience, camera position is often compromised in SILS surgeries. Poor ergonomic position occurs as the assistant who is holding the camera stands on the opposite side of the surgeon. The situation is worsened as port site

selection is also not possible with SILS as the incision is restricted to the umbilicus. Both the surgeon and the assistant are put into uncomfortable positions to avoid instrument crowding and to increase triangulation. Using a camera holding set up system significantly increases the external working space, offers a stable, consistent view of the entire operative field and gives the surgeon more control during the operation [25]. In addition, with the positioning of the camera between the two laparoscopic instruments, the view of the surgical site is less distorted as opposed to placing it by the side of the instruments, resulting in better hand-eye coordination during the surgery. This is of particular importance in SILS as all instruments pass through the same umbilical incision.

### **Improvement in productivity and cost saving**

Increased productivity and improved utilization of manpower in the operating theatre are other benefits in solo SILS. The conventional set-up for SILS in gynaecological surgery requires a minimum of 3 persons – the main surgeon, an assistant to hold the camera and a second assistant to manipulate the uterus vaginally. Using the solo SILS approach, the assistants are freed up, thus improving surgical productivity and utilization of manpower.

Given that there is a reduction in manpower required in solo surgery, we postulate that cost savings in this aspect will likely offset the initial capital outlay for the instruments, although more detailed cost analysis will have to be done to determine this.

### **Limitations**

Despite these potential benefits, solo SILS has its limitation. We acknowledge that the lack of assisting staff in a solo surgery setting could be problematic, especially when complications arise during surgery, resulting in the conversion to another surgical approach where surgical assistance is needed. There is no definite solution to this apart from appropriate case selection, good road mapping and planning of the actual surgical procedure.

### **CONCLUSION**

Surgery has evolved rapidly over the years and surgical approaches are increasingly being tailored not only to the primary pathology, but also to the patient's expectations of surgical outcomes and surgical efficiency. This case report demonstrated that solo SILS coupled with the utilization of the camera holder is feasible, safe and economical in

carefully selected cases with benign gynaecological pathologies of intermediate complexity. This approach resulted in better ergonomics and improved hand-eye coordination for the surgeon during the SILS surgery, which is likely to translate to better surgical outcomes for the patient. Henceforth, solo SILS is a possibility and likely the future for benign gynecological adnexal surgeries.

### **References**

1. Fagotti, A., et al., Laparoendoscopic single-site surgery for the treatment of benign adnexal diseases: a pilot study. *Surg Endosc*, 2011. 25(4): p. 1215-21.
2. Lee, J.H., et al., Single-port laparoscopic myomectomy using transumbilical GelPort access. *Eur J Obstet Gynecol Reprod Biol*, 2010. 153(1): p. 81-4.
3. Park, H.S., et al., Single-port access (SPA) laparoscopic surgery in gynecology: a surgeon's experience with an initial 200 cases. *Eur J Obstet Gynecol Reprod Biol*, 2011, 154(1): p. 81-4.
4. Yoon, B.S., et al., Single-port versus conventional laparoscopic salpingectomy in tubal pregnancy: a comparison of surgical outcomes. *Eur J Obstet Gynecol Reprod Biol*, 2011, 159(1): p. 190-3.
5. Fagotti, A., et al., Postoperative pain after conventional laparoscopy and laparoendoscopic single site surgery (LESS) for benign adnexal disease: a randomized trial. *Fertil Steril*, 2011. 96(1): p. 255-259 e2.
6. Kim SJ, et al., Novel approach of single-port laparoscopic appendectomy as a solo surgery: A prospective cohort study. *Int J Surg*. 2015 Sep;21:1-7.
7. Ahn SH, et al., Solo Intracorporeal Esophagojejunostomy Reconstruction Using a Laparoscopic Scope Holder in Single-Port Laparoscopic Total Gastrectomy for Early Gastric Cancer. *J Gastric Cancer*. 2015 Jun;15(2):132-8.
8. B Best SL1, et al., Solo surgeon laparo-endoscopic single site nephrectomy facilitated by new generation magnetically anchored and guided systems camera. *J Endourol*. 2012 Mar;26(3):214-8.
9. McCaffery, M et al. (1993). *Pain: Clinical Manual for Nursing Practice*. Baltimore: V.V. Mosby Company.
10. Im, K.S., et al., Laparoendoscopic single-site surgery versus conventional laparoscopic surgery for adnexal tumors: a comparison of surgical outcomes and postoperative pain outcomes. *Kaohsiung J Med Sci*, 2011. 27(3): p. 91-5.
11. Bucher, P., et al., Population perception of surgical safety and body image trauma: a plea for scarless surgery? *Surg Endosc*, 2011. 25(2): p. 408-15.
12. Rao, A., et al., Patient preferences for surgical techniques: should we invest in new approaches? *Surg Endosc*, 2010. 24(12): p. 3016-25.
13. Tsai, A.Y. and D.J. Selzer, Single-port laparoscopic surgery. *Adv Surg*, 2010. 44: p. 1-27.
14. Santos, B.F., et al., Single-incision laparoscopic surgery (SILS) versus standard laparoscopic surgery: a comparison of performance using a surgical simulator. *Surg Endosc*, 2011. 25(2): p. 483-90.
15. Montero, P.N., et al., Single incision laparoscopic surgery (SILS) is associated with poorer performance and increased surgeon workload compared with standard laparoscopy. *Am Surg*, 2011. 77(1): p. 73-7.
16. Mereu, L., et al., Single access laparoscopy for adnexal pathologies using a novel reusable port and curved instruments. *Int J Gynaecol Obstet*, 2010. 109(1): p. 78-80.

17. Jung, Y.W., et al., Single port transumbilical laparoscopic surgery for adnexal lesions: a single center experience in Korea. *Eur J Obstet Gynecol Reprod Biol*, 2011. 155(2): p. 221-4.
18. Ergün O et al, Single center experience in single-incision laparoscopic surgery in children in Turkey. *J Pediatr Surg*. 2011 Apr; 46(4):704-7
19. Lee, Y.Y., et al., Single port access laparoscopic adnexal surgery versus conventional laparoscopic adnexal surgery: a comparison of peri-operative outcomes. *Eur J Obstet Gynecol Reprod Biol*, 2010. 151(2): p. 181-4.
20. Aiono, S., et al., Controlled trial of the introduction of a robotic camera assistant (EndoAssist) for laparoscopic cholecystectomy. *Surg Endosc*, 2002. 16(9): p. 1267-70.
21. Kalteis, M., et al., Laparoscopic cholecystectomy as solo surgery with the aid of a robotic camera holder: a case-control study. *Surg Laparosc Endosc Percutan Tech*, 2007. 17(4): p. 277-82.
22. Proske, J.M., I. Dagher et al, Comparative study of human and robotic camera control in laparoscopic biliary and colon surgery. *J Laparoendosc Adv Surg Tech A*, 2004. 14(6): p. 345-8.
23. Mettler, L. et al, One year of experience working with the aid of a robotic assistant (the voice-controlled optic holder AESOP) in gynaecological endoscopic surgery. *Hum Reprod*, 1998. 13(10): p. 2748-50.
24. Tchatchian, G., et al., Decreasing strain on the surgeon in gynecologic minimally invasive surgery by using semi-active robotics. *Int J Gynaecol Obstet*, 2011. 112(1): p. 72-5.
25. Herman, B., et al., Design and preliminary in vivo validation of a robotic laparoscope holder for minimally invasive surgery. *Int J Med Robot*, 2009. 5(3): p. 319-26.

**Author Information**

**Yang Feng, MD(China)**

Department of Obstetrics and Gynaecology, National University Hospital  
Singapore

**Ying Woo Ng, MBBS(Singapore), MMED(O&G, Singapore), MRCOG(UK)**

Department of Obstetrics and Gynaecology, National University Hospital  
Singapore  
ying\_woo@yahoo.com.sg

**Zhongwei Huang, MBBS(Singapore), PhD(Oxon), AHEA (UK)**

Department of Obstetrics and Gynaecology, National University Hospital  
Singapore