

# Squamous Cell Carcinoma of the Vulva in Turner Syndrome

S Al Inizi, P Keating

## Citation

S Al Inizi, P Keating. *Squamous Cell Carcinoma of the Vulva in Turner Syndrome*. The Internet Journal of Gynecology and Obstetrics. 2006 Volume 7 Number 1.

## Abstract

Turner syndrome (gonadal dysgenesis) is an important cause of short stature in girls and primary amenorrhoea, which is usually caused by loss of part or all the X-chromosome. It is well known that women with Turner syndrome are liable to develop various diseases such as autoimmune diseases like thyroiditis, and cardiovascular, urologic and bone structural diseases in addition to hypertension and diabetes 1 However the risk of cancer, with the exception being in the case of colonic and rectal cancers, does not seem to be elevated in Turner syndrome 1.

Carcinoma of the vulva is a rare gynaecological cancer and in Turner syndrome it is extremely rare. We report a case of squamous cell carcinoma (SCC) of the vulva in a 61 year old Caucasian woman diagnosed with Turner syndrome at the age of 15.

Radical vulvectomy with en-block inguinal femoral lymphadenectomy was carried out. Histopathological examination of the specimen confirmed complete excision of the tumour with absence of metastasis to the lymph nodes.

Conclusion: This seems to be the first reported case of SCC of the vulva in a patient with Turner syndrome.

## CASE REPORT

A 61 year old single nulligravid Caucasian woman was referred to Royal Preston Hospital with the diagnosis of SCC of the vulva. She complained of a vulval ulcer a month earlier which was biopsied and revealed SCC of the vulva .

On examination there was an unhealthy looking ulcerative lesion of 2x2 cm size adjacent to the previous biopsy site at the right side of the vulva. The urethral meatus, anus, vagina and the left labia minus were not involved. There were no palpable groin lymph nodes. Magnetic resonance imaging revealed neither vulval mass lesion, nor overt inguinal or para-aortic nodal disease.

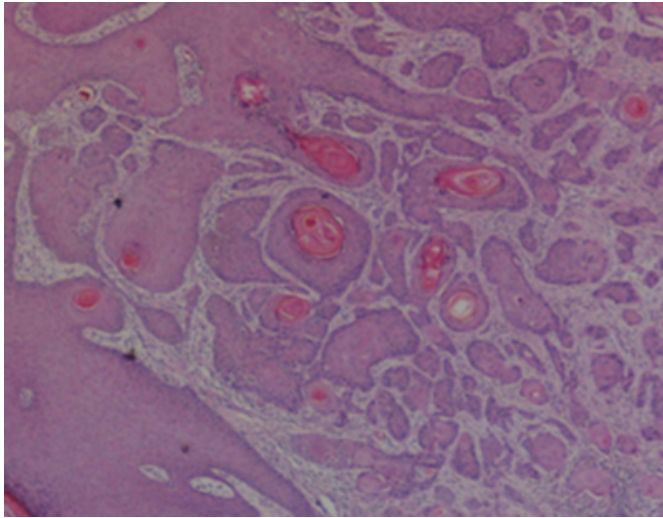
She was diagnosed at the age of 15 to have Turner syndrome when she presented with primary amenorrhoea. She had short stature (140 cm), underdeveloped breasts with no axillary and pubic hair. She did not have any medical problems as she was investigated earlier. She did not receive any estrogen replacement therapy in her life and never had any period.

Radical anterior vulvectomy using triple incision procedure with en-block inguinal femoral lymphadenectomy was performed. Histological examination revealed 18X12X20

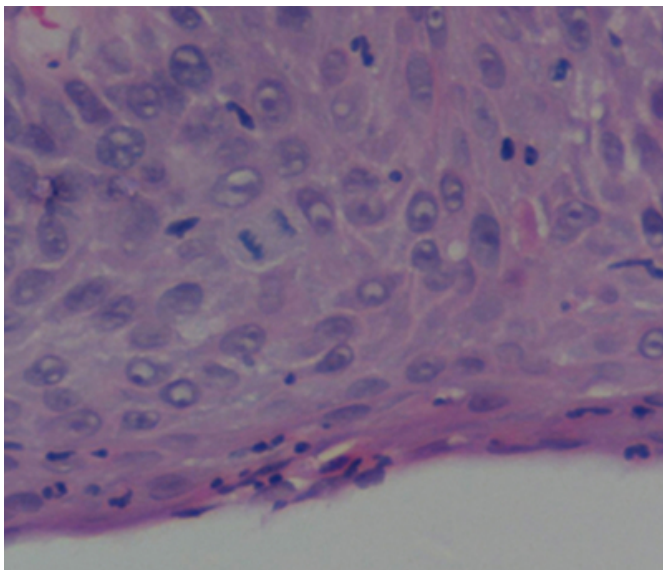
mm polypoid keratinising SCC of the vulva with grade III vulval intra-epithelial neoplasia (VIN III). The tumor was 2.7 cm from vaginal margin and more than 1 cm from skin margins. The tumor and VIN were completely excised with no definite lympho-vascular invasion (figure 1 & 2). The clinical pathologic stage (FIGO) was stage I. The patient had an uneventful post operative recovery and went home on the 7<sup>th</sup> post operative day in good condition. There has been no recurrence to date.

**Figure 1**

Figures 1 & 2: Vulvar SCC with nests of tumour cells and VIN.



**Figure 2**



### DISCUSSION

Women with Turner syndrome have an increased incidence of gonadoblastomas and germ cell neoplasms especially when Y-chromosome or any portion of it is identified<sup>2,3</sup>. Unopposed estrogen replacement therapy has been reported to be associated with endometrial carcinoma in women with Turner syndrome<sup>4</sup>. However, the use of estrogen replacement therapy in women with Turner syndrome was not found to be associated with increased risk of breast cancer above that of the general population<sup>5</sup>. Spontaneous menarche in patients with Turner syndrome might also carry an increased risk of endometrial carcinoma<sup>6</sup>.

Carcinoma of the vulva is a rare gynaecological cancer. It most frequently occurs in women 65-75 years of age<sup>7</sup>. The recognised cause of death in women with Turner syndrome is aortic dissection with rupture often occurring with coarctation of the aorta making life expectancy less than the average population<sup>8</sup>. However the present patient did not have any cardiac, renal or endocrine problems which may explain living longer than expected.

Patients with Turner syndrome have streaks gonads which secrete very little estrogen. These patients often receive estrogen replacement therapy to develop secondary female sex characteristics and to prevent osteoporosis<sup>9</sup>. However, the present patient had not received any oestrogen replacement therapy in her life.

It was suggested before that women with Turner syndrome are liable to develop carcinoma of the vulva at an earlier age due to prolonged exposure to an environment of very low circulating estrogen level, similar to that in postmenopausal women<sup>9</sup>. However, the present patient had SCC of the vulva at the age of 61 years despite the prolonged exposure to low estrogen environment, which may disprove the above suggestion.

In conclusion, this case report illustrates that our clinical experience with SCC of the vulva does not differ between a patient with Turner syndrome and the general population.

### CORRESPONDENCE TO

Dr. Shamma Al Inizi, 10 Bracken close, Sale, Cheshire M33 5EX UK Tel +44 782170874 Email address: shammainizi@hotmail.com

### References

1. Gravholt Ch, Juul S, Naerra RW, Hansen J. Morbidity in Turner syndrome. *J Clin Epidemiol* 1998; 51;147.
2. Mazzanti L, Cicognani A, Baldazzi L et al. Gonadoblastoma in Turner syndrome and Y-chromosome derived material. *Am J Med Genet A*. 2005;1;135(2);150-4.
3. Moom W S, Lee DG. Ovarian sex cord tumour with annular tubules in a patient with Turner syndrome. *J Korean Med Sci*, 1998; 13(1);89-94.
4. Wilkinson EJ, Friedrich EG, Mattingly RF. Turner syndrome with endometrial adenocarcinoma and stilbestrol treatment. *Obstet Gynecol*. 1973; 42:193-200.
5. Hanton L, Axelrod L, Bakalov V, Bondy C. The importance of estrogen replacement in young women with Turner syndrome. *Jour of women`s health*. 2003 (12),10:971-977.
6. Kocava M, Basheska N, Papazovska A et al. Girls with Turner`s syndrome with spontaneous menarche have an increased risk of endometrial carcinoma: a case report and review from the literature. *Gynecol Oncol* 2005, 96(3): 840-5
7. Landis SH, Murray T, Bolden S, Wingo PA. Cancer

statistics. CA cancer J clin. 1998;48:6-29.

8. Lin AE, Lippe B, Rosenfeld RG. Further delineation of aortic dilation, dissection and rupture in patient with Turner

syndrome. Pediatrics. 1998; 102:e12.

9. Iwamota I, Kijima Y, Fujino T, Yoshinaga M, Douchi T. Verrucous carcinoma of the vulva in Turner syndrome. Gynecol Oncol. 2004, 92: 380-383.

**Author Information**

**Shamma Al Inizi, MRCOG**

Department of Obstetrics and Gynecology, Royal Preston Hospital

**Patrick Keating, FRCOG**

Department of Obstetrics and Gynecology, Royal Preston Hospital