

# Pilimiction: A Diagnostic Symptom Of Ovarian Dermoid Cyst

R Godara, R Karwasra, P Garg, N Sharma

## Citation

R Godara, R Karwasra, P Garg, N Sharma. *Pilimiction: A Diagnostic Symptom Of Ovarian Dermoid Cyst*. The Internet Journal of Gynecology and Obstetrics. 2005 Volume 6 Number 1.

## Abstract

Ovarian dermoid cyst is a common problem. Prolonged delay in seeking treatment may result in various complications. An ovarian dermoid cyst adherent to urinary bladder with passage of dermoid contents like hairs in urine (pilimiction)<sup>1</sup> is a rare complication, specially in the context of modern literate and aware society.

## INTRODUCTION

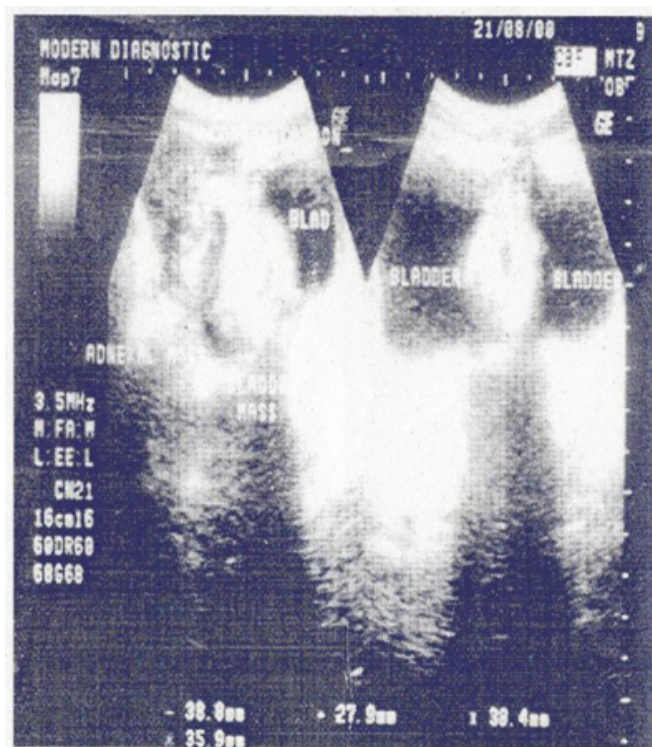
Ovarian dermoid cyst is a common problem. Prolonged delay in seeking treatment may result in various complications. An ovarian dermoid cyst adherent to urinary bladder with passage of dermoid contents like hairs in urine (pilimiction)<sup>1</sup> is a rare complication, specially in the context of modern literate and aware society.

## CASE REPORT

A 29 year-old married female presented with chief complaints of frequency of micturition and dysuria with passage of hairs in dirty coloured urine. She was not having any menstrual disturbances except for mild occasional dysmenorrhoea. Past medical and surgical history was non-contributory. Pelvic examination disclosed left adnexal non-tender mass of size 4cm x 4cm, with restricted mobility. Routine investigations were within normal limits. Ultrasound showed a moderately echogenic 42mm x 32mm mass, related to the postero-superior wall of urinary bladder. This mass was infiltrating through the bladder wall and communicating with hypoechoic mass 42x32mm in left adnexal region. Echogenic deposits were seen over the bladder mass. Uterus and right adnexa were normal (Fig. 1). CT scan of the abdomen could not be done because patient's inability to afford the costs of the CT scan and also cystoscopic biopsy was negative (so patient was not keen to undergo CT scan).

**Figure 1**

Figure 1: Ultrasound showing dermoid cyst contents in urinary bladder cavity and its continuity with adnexa

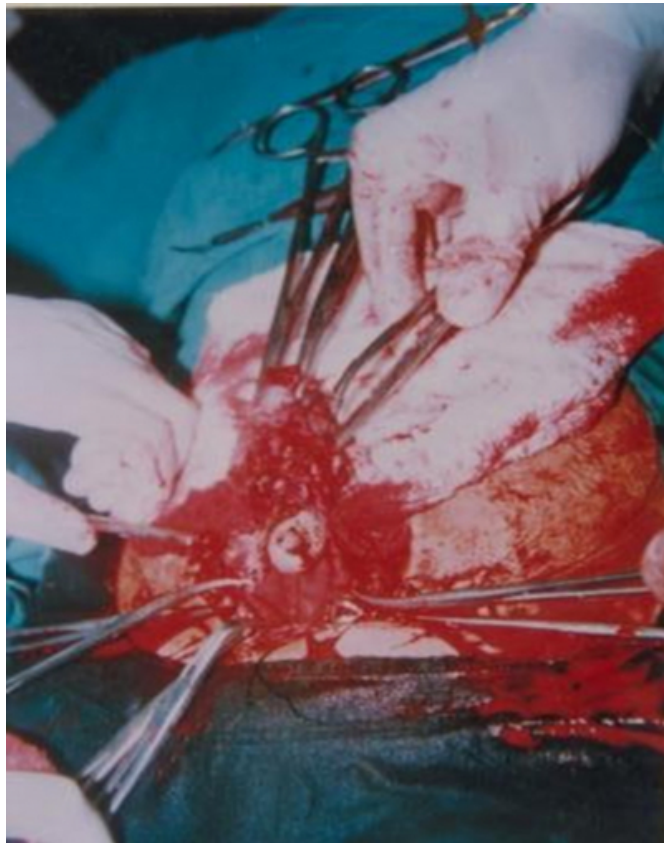


Cystoscopy revealed a proliferative lesion 3 to 4cm size covered with slough and hairs on posterolateral wall. Biopsy was taken from the base of the lesion which revealed reactive hyperplasia. Exploration was done through lower midline incision. On opening the bladder a mass covered with hairs and chalky material was found which was in continuity with left sided adnexal mass (Fig. 2). Left sided oophorectomy along with resection of bladder wall adherent

to dermoid was carried out. Bladder was repaired in two layers. Foley's catheter and retropubic drain were kept. The patient made an uneventful recovery. Histopathology report showed teratoma with ectodermal – skin and adnexal structures; mesodermal- fibrocollagenic osteoid and cartilaginous tissues endodermal – glandular and neuroglial elements.

## Figure 2

Figure 2: Photograph showing fistulous communications and protrusion of adnexal mass in urinary bladder.



## DISCUSSION

Ovarian dermoid cysts are usually benign lesion, occurring mostly during the reproductive years, but reported also at both extremes of life. Dermoid cysts constitute 10 – 15 percent of all the ovarian neoplasms<sup>2</sup>. Dermoid cysts rarely present a diagnostic or therapeutic problem; however its complications can make the patient quite ill and pose

diagnostic dilemma.

Amongst various complications reported, spontaneous rupture into urinary bladder is least common.<sup>3</sup> Such a condition was first reported by Wallace in 1700.<sup>4</sup> Until availability of cystoscopy, the diagnosis depended upon history and physical examination, such as pilimiction (passage of hairs during urination), pyuria, hematuria or any other component of the structures of a dermoid cyst. Other complications like chemical peritonitis, peritoneal melanosis due to intraperitoneal rupture of dermoid cyst<sup>5,6</sup> are well defined but rare. Although there are various reports on laparoscopic tackling of some of these complications cases like this are less likely to be tackled with laparoscopy. If a female patient presents with complain of pilimiction, one can consider it as a pathognomonic symptom of ovarian dermoid.

## CORRESPONDENCE TO

Dr. Rajesh Godara 15/11J, Medical Enclave PGIMS, Rohtak – 124001 Haryan, India email: drrajeshgodara@yahoo.co.uk

## References

1. Pilimiction - Taber's Cyclopedic medical dictionary. 16th edition : Jaypee Brothers medical publishers 1990 [x]g 1401.
2. Clement D, Barranger E, Benchimol Y, Uzan S. Chemical peritonitis: a rare complication of an iatrogenic ovarian dermoid cyst rupture. *Surg Endosc* 2003 Apr; 17(4):658.
3. Tancer ML, Orron A, Baker JD Greenberger ME. Spontaneous rupture of ovarian teratoid tumor into the urinary bladder; review of eleven cases and report of one new case *Obstet Gynecol* 1955; 6(6): 668-70.
4. Townsend MJ. Bladder tumor, arising from an ovarian dermoid cyst. *J Urol* 1939; 42: 101 - 7.
5. Achtari C, Genolet PM, Bouzourene H, De Grandi P. Chemical peritonitis after iatrogenic rupture of a dermoid cyst of the ovary treated by coelioscopy. *Apropos of a case and review of literature. Gynakol Geburtshifliche Rundsch* 1998;38( 3):146-50.
6. Jaworski RC, Boadle R, Greg J, Cocks P. Peritoneal melanosis associated with a ruptured ovarian dermoid cyst : report of a case with electron-probe energy dispersive x-ray analysis. *Int. J Gynecol Pathol* 2001 Oct; 20 (4): 386-9.
7. Roman H, Accoceberry M, Bolandard F, Bourdel N, Lenglet Y, Canis M. Laproscopic management of a ruptured benign dermoid cyst during advanced pregnancy. *J Minim Gynecol* 2005 July-Aug, 12(4): 377-8.

**Author Information**

**Rajesh Godara, MS, FAIS**

Lecturer, Department of Surgery, Pt. B.D. Sharma Postgraduate Institute of Medical Sciences

**R. K. Karwasra, MS, FICS**

Professor, Department of Surgery, Pt. B.D. Sharma Postgraduate Institute of Medical Sciences

**Pradeep Garg, MS, DNB**

Associate Professor, Department of Surgery, Pt. B.D. Sharma Postgraduate Institute of Medical Sciences

**Neeraj Sharma, MD**

Lecturer, Department of Obstetrics & Gynaecology, Pt. B.D. Sharma Postgraduate Institute of Medical Sciences