An abnormal foramen connecting the middle cranial fossa with sphenoidal air sinus: A Case Report

S Nayak

Citation

S Nayak. *An abnormal foramen connecting the middle cranial fossa with sphenoidal air sinus: A Case Report*. The Internet Journal of Biological Anthropology. 2007 Volume 2 Number 1.

Abstract

An abnormal foramen connecting the middle cranial fossa with the sphenoidal air sinus was noted. This foramen was large and circular with a smooth outline. It was located anterolateral to the sella turcica, medial to the superior orbital fissure and behind the optic canal. Since the foramen was noted in a dry skull during osteology demonstration classes, we are unaware about the structures passing though it if any. Knowledge of this foramen may be important for radiologists, endocrinologists and anthropologists.

INTRODUCTION

The middle cranial fossa is one among the three cranial fossae, the others being anterior and middle cranial fossae. The middle cranial fossa contains a median region and two lateral regions. The middle cranial fossa is mainly formed by the body and greater wing of the sphenoid bones. In the median plane it contains the sella turcica which lodges the pituitary gland. On either side of sella turcica, there are carotid sulci which lodge the cavernous sinuses. Middle cranial fossa communicates with the orbit through the optic canal and superior orbital fissure, with the infratemporal fossa through foramen ovale and spinosum and with the pterygopalatine fossa with foramen rotundum. Communication of the middle cranial fossa with the sphenoidal air sinus has not been reported yet. We saw one such communication between middle cranial fossa and sphenoidal air sinus.

CASE REPORT

During osteology demonstration classes for medical undergraduates an abnormal foramen was noted in the middle cranial fossa (Figs. 1 and 2). The foramen was large and circular with a smooth outline. It was located anterolateral to the sella turcica, medial to the superior orbital fissure and behind the optic canal. It communicated the middle cranial fossa with the sphenoidal air sinus. The foramen was on the left side of the midline and was unilateral.

Figure 1

Figure 1: Interior of the skull showing the three cranial fossae and abnormal foramen in the middle cranial fossa.

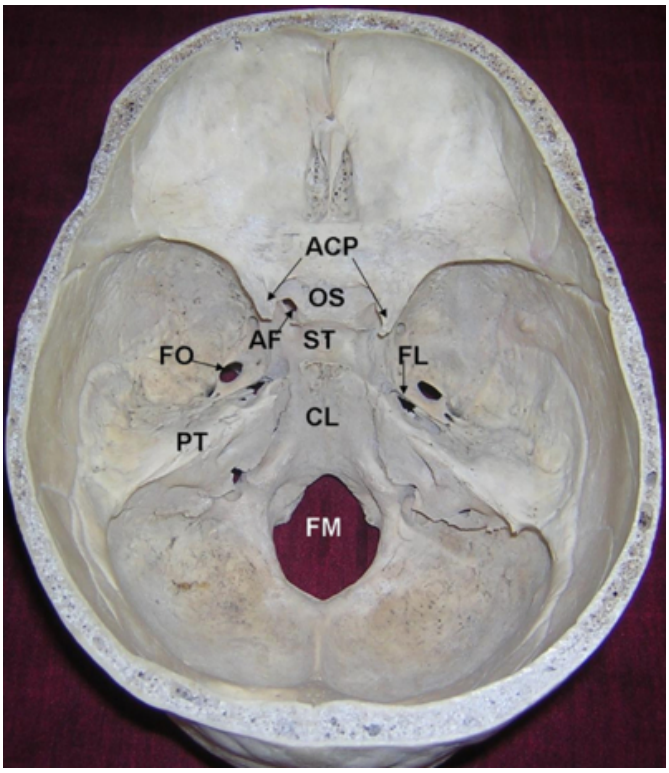

(ACP: anterior clinoid process; OS: optic sulcus; ST: sella turcica; CL: clivus; AF: abnormal foramen; FO: foramen ovale FL: foramen lacerum PT: petrous temporal FM: foramen magnum)

Figure 2

Figure 2: Closer view of the middle cranial fossa showing the abnormal foramen.

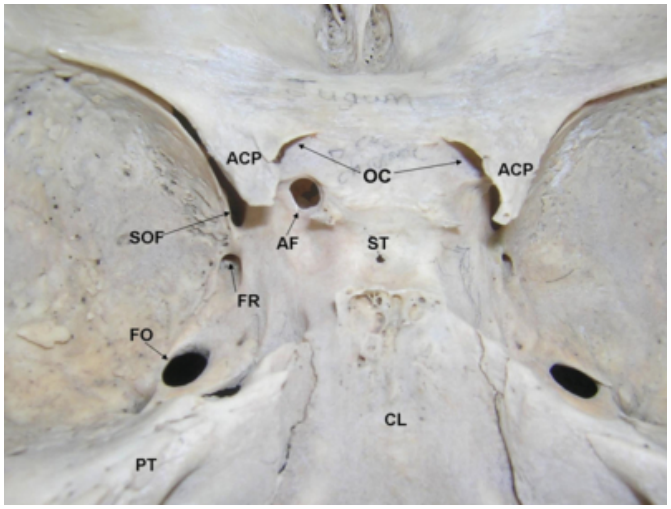

(ACP: anterior clinoid process; OS: optic sulcus; ST: sella turcica; CL: clivus; AF: abnormal foramen; FO: foramen ovale FL: foramen lacerum PT: petrous temporal FM: foramen magnum)

DISCUSSION

The normal foramina of middle cranial fossa are foramen ovale, foramen rotundum and foramen spinosum. The other foramina which are rarely found in relation to the sphenoid bone in the middle cranial fossa are pterygospinous foramen and pterygoalar foramen and emissary sphenoidal foramen. An emissary sphenoidal foramen exists in 13-17% of cases [1]. A case of atypical foramen ovale has been reported by Skrzat et al., [2]. A hypophysial or craniopharyngeal canal may be found connecting the nasopharynx with the pituitary fossa. Two cases of persistent craniopharyngeal canal have been reported by Hughes et al., [3]. The presence of craniopharyngeal canal may lead to sphenoidal meningocele. One such case has been reported by Schick et al., [4] where there was a lateral craniopharyngeal canal (Sternberg's canal). The sphenoid bone represents a complex structure in terms of anatomy and embryology. It is formed by the fusion of different primordia whose embryonic origins are different. The complexity of its development and non fusion of some of its parts may lead to abnormal foramina [5].

The foramen that we are reporting is unique and has not been reported yet. Since this foramen is not in the midline, it cannot be a remnant of craniopharyngeal canal. The foramen only extended into the spenoidal sinus and not into the nasopharynx. This further supports that it is not the remnant of craniopharyngeal canal. The foramen probably occurred due to some developmental defects in the sphenoid. Since it was observed during demonstration of the dry skull, we are unaware of the structures passing through it. The knowledge of this foramen may be useful for the raidiologists, endocrinologists and anthropologists.

CORRESPONDENCE TO

Dr. Satheesha Nayak B. Associate Professor of Anatomy
Melaka Manipal Medical College (Manipal Campus)
International Centre for Health Sciences Madhav Nagar,
Manipal Udupi District Karnataka State, INDIA. 576104
Email: nayaksathish@yahoo.com Phone: 91 820 2922519, 91 9844009059

References

1. Bergman RA, Afifi AK, Miyauchi R. Compendium of human anatomical variations. Baltimore: Urban and Schwarzenberg. 1988. pp 200.
2. An atypical position of the foramen ovale.
Skrzat J, Walocha J, Srodek R, Nizankowska A. Folia Morphol (Warsz). 2006;65(4):396-9.
3. Hughes ML, Carty AT, White FE. Persistent hypophyseal (craniopharyngeal) canal. Br J Radiol. 1999;72(854):204-6.
4. Sternberg's canal--cause of congenital sphenoidal meningocele.
Schick B, Brors D, Prescher A. Eur Arch Otorhinolaryngol. 2000;257(8):430-2.
5. Catala M. Embryology of the sphenoid bone. J Neuroradiol. 2003;30(4):196-200.

Author Information

Satheesha Nayak
Associate Professor of Anatomy, Melaka Manipal Medical College (Manipal Campus), International Centre for Health Sciences