

# A Novel Method for the Objective Assessment of Thenar Atrophy

L Galea, J Agius, C Sciberras

## Citation

L Galea, J Agius, C Sciberras. *A Novel Method for the Objective Assessment of Thenar Atrophy*. The Internet Journal of Plastic Surgery. 2006 Volume 3 Number 1.

## Abstract

**Purpose:** Although thenar atrophy is caused by a variety of clinical conditions, it is commonly associated with carpal tunnel syndrome. Thenar atrophy has been mostly assessed subjectively. The purposes of the study are to test a simple, novel, objective and quantitative test for the assessment of thenar atrophy; and to correlate this test with subjective evaluation of thenar atrophy.

**Methods:** The apparatus consisted of a box with a clear glass sheet on the top uncovered surface, with a digital camera placed in the base of the box. Group 1 included 106 healthy volunteers with a total of 212 hands. Group 2 was formed from 36 patients with a total of 72 hands with carpal tunnel syndrome. Thenar atrophy was classified subjectively as none, mild, moderate and severe. Patients and subjects were asked to press their hands facing down on the glass sheet and digital photos were taken. The technique relies on the fact that the area where pressure is exerted on the palm blanches. Photos were transferred to photo processing software. After enhancement the photos were transferred to an image analysis software. The thenar area (A) and the rest of the palm area (B) were measured. The thenar ratio was calculated as A divided by A plus B multiplied by hundred.

**Results:** Hands with thenar atrophy had a statistically significant lower thenar ratio than healthy hands ( $19.9 \pm 6.7$  vs  $35.6 \pm 8.0$ ; P value  $< 0.0001$ ). Subjective assessment of atrophy correlated with the thenar ratio.

**Conclusions:** This method can be used as a simple objective test for the assessment and follow-up of thenar atrophy.

## INTRODUCTION

The thenar eminence constitutes the intrinsic muscles of the hand that are responsible for complex movements of the thumb. Atrophy of thenar muscles can be caused by a variety of clinical conditions. Although thenar atrophy is commonly associated with carpal tunnel syndrome (CTS)<sub>1</sub>; it is also associated with liver cirrhosis<sub>2</sub>, thoracic outlet syndrome<sub>3</sub> and Weill-Marchesani syndrome<sub>4</sub>.

In CTS, thenar atrophy is usually associated with longstanding or severe cases<sub>5,6,7</sub>. However, the finding of thenar atrophy has been found to have limited or no value in distinguishing patients with CTS from those without it<sub>8</sub>. The main reason for this is the low sensitivity of clinical thenar atrophy as a diagnostic test (0.04 to 0.28)<sub>9,10,11</sub>. On the other hand, thenar atrophy has been reported to have a high specificity for CTS (0.82 to 0.99)<sub>9,10,11</sub>. Subjective evaluation of thenar atrophy has been reported widely in the literature

in order to evaluate the outcome of carpal tunnel release<sub>12,13,14,15,16</sub>. Some authors have graded the subjective evaluation of thenar atrophy as none, mild to moderate or severe based on the bulk and contour of the thenar eminence<sub>13</sub>.

There have been a few attempts to standardize and assess thenar atrophy objectively. Magnetic resonance imaging showed moderate correlation with thenar atrophy<sub>17</sub>. Tuncali D et al<sub>18</sub> developed the thenar index for the objective assessment of thenar atrophy using static hand imprints with high specificity and acceptable sensitivity for thenar atrophy.

The aims of this study are to test a simple, novel, objective and quantitative test for the assessment of thenar atrophy, and correlate this test with subjective evaluation of thenar atrophy.

## **PATIENTS AND METHODS**

### **PATIENTS AND SUBJECTS**

Digital photos of both hands pressed on a glass sheet using the apparatus described below were taken from volunteers (Group 1) and patients with CTS (Group 2). Group 1 included healthy adult subjects who did not suffer from any medical problems, peripheral or central nervous system disorders and did not have a past history of trauma to the upper extremity. Group 2 included patients with bilateral CTS awaiting carpal tunnel release surgery. However, not all patients had clinical evidence of atrophy. Thenar atrophy was assessed by one of the authors (LAG) as none, mild, moderate and severe. The age, gender, hand dominance and occupation of each subject and patient were noted. Informed consent was obtained from each subject and patient and the study was approved by the local research ethics committee.

### **APPARATUS**

The apparatus consisted of a box with the corners made of wood and the four vertical sides covered with black cardboard (Figure 1). A clear glass sheet 10mm thick was placed on the top uncovered surface of the box and fixed with stoppers to the edges. A digital camera (Canon PowerShot G5 ®) was placed on its back in the middle of the base of the box and covered by a black cardboard sheet with a hole in the middle to allow for the camera lens to protrude. Black cardboard was used to prevent reflections on the glass sheet from the camera itself and objects outside the box. A hole on one side of the box near the base allows for signal from wireless controller to reach the remote sensor of the camera for remote photo shooting. The digital camera was set on portrait mode, flash off, high resolution, high quality compression, macro mode, vivid photo effect and remote shooting mode.

**Figure 1**



### **HAND PHOTOS**

The technique relies on the fact that the area where pressure is exerted on the palm of a hand blanches. Patients and subjects were asked to press their hands with full abduction of all the digits, with the wrist joint in neutral position, palms in the centre of the glass sheet with full force on the glass sheet. A photo was taken with remote shooting after pressing the button of the remote controller (Figure 1). Figure 2 shows the photo obtained in gray scale. The pale areas indicate the regions where pressure is exerted on the glass sheet as opposed to the dark areas where pressure is not exerted on the glass sheet. The glass sheet's surface was cleaned with an alcohol swab after each patient and subject and allowed to dry before the next photo.

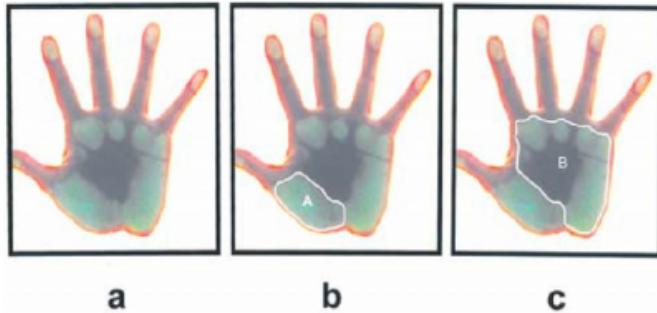
### **PHOTO ANALYSIS**

The photos were transferred to a photo processing software programme (Arcsoft Photo Studio 5 ®). Each photo was enhanced by increasing the colour saturation to 100% by clicking on the enhance function from the menu and then on hue and saturation. This increased the intensity of the image colours.

The enhanced photos were then transferred to an image analysis programme (Able Image Analyzer Version 3.6 ®). The thenar area (A) (Fig.3) and the rest of the palm area (B)

(Fig.4) were measured. The thenar ratio was calculated as A divided by A plus B multiplied by 100. The time for the whole process from the photo shooting to the calculation of the thenar ratio was measured for a sample of the hand photos.

**Figure 2**



Statistical analysis of the data was carried out using SPSS statistical version 12.0. The student t-test was used to compare data within and between groups. Statistical significance was assumed if the P-value was less than 0.05. All analyses were carried out using hands rather than patients as the unit of analysis, because the degree of variation for the thenar ratio was essentially the same for paired and unpaired data.

## RESULTS

Group 1 included 106 healthy volunteers, so a total of 212 hands. 50 were females and 48 were males. The mean age of females and males was  $50 \pm 18.8$  (range 18 to 76) and  $46.7 \pm 16.6$  (range 22 to 79) respectively. 36 patients with bilateral carpal tunnel syndrome were included in Group 2. 28 were females and 9 were males. The mean age females and males was  $54.4 \pm 11.3$  (range 39 to 86) and  $60.2 \pm 11.8$  (range 42 to 74) respectively. All patients had bilateral CTS. Thenar atrophy ranging from mild to severe was present in 49 hands of 29 patients and clinical absence of thenar atrophy was present in 23 hands of 16 patients. Most of the subjects in Group 1 were home makers, paramedics, nurses, doctors and technicians. Most of the patients in Group 2 were home makers, technicians and carers.

The photos of two subjects in Group 1 were out of focus and the photo of one subject had inadequate exposure due to inadequate setting of the camera. One of the patients with bilateral CTS had deformity of fingers and so even pressure could not be applied on the glass sheet. Therefore 103 subjects and 35 patients with bilateral CTS were included for data analysis.

The mean thenar ratio for group 1 was  $35.8 \pm 8.6$  (range 16.7 to 61.1). There was no statistically significant difference between gender and hand dominance between groups (Tables 1 and 2). The mean thenar ratio for group 2 was  $20.0 \pm 6.2$  (range 4.1 to 31.5). Table 3 shows the thenar ratio for Group 2 for the clinical grading of atrophy severity including the hands with carpal tunnel syndrome but with absence of atrophy. The thenar ratio was highly statistically significant different between both groups (P value  $< 0.0001$ ).

**Figure 3**

Table 1: Comparison in thenar ratio between gender in Group 1.

	FEMALE		MALE	
	DOMINANT	NON DOMINANT	DOMINANT	NON DOMINANT
NO OF HANDS	36	36	41	41
AVERAGE	35	34.1	36.9	36
SD	7.5	7.2	8.8	7.9
P VALUE	0.62		0.65	

**Figure 4**

Table 2: Comparison in thenar ratio between hand dominance in Group 1.

	DOMINANT		NON DOMINANT	
	FEMALE	MALE	FEMALE	MALE
NO OF HANDS	36	41	36	41
AVERAGE	35	36.9	34.1	36
SD	7.5	8.8	7.2	7.9
P VALUE	0.32		0.28	

**Figure 5**

Table 3: Thenar ratio according to atrophy severity.

SEVERITY	NUMBER OF HANDS	MEAN (SD)
ABSENCE	23	26.8 (2.6)
MILD	17	20.4 (1.1)
MODERATE	21	16.4 (2.0)
SEVERE	11	8.8 (2.4)

Table 4 shows the sensitivity and specificity of the test for

thenar atrophy for three cutoff values of the thenar ratio.

**Figure 6**

Table 4: Sensitivity and specificity of three cutoff thenar ratios.

THENAR RATIO	30	29	28
SENSITIVITY	95.7	94.3	92.9
SPECIFICITY	74.8	79.6	84

The time for the whole process from the photo shooting to the calculation of the thenar ratio was measured for a sample of thirty hand photos. The mean time taken was  $3.2 \pm 0.8$  minutes (range 1.9 to 5 minutes) for each process.

## DISCUSSION

Thenar atrophy is a common clinical finding in CTS with a higher incidence in severe cases<sup>19,20,21,22</sup>. From the literature it is evident that there have been quite a few attempts to standardize thenar atrophy clinically. However, subjective bias is the main problem with such evaluation. Gelberman RH et al<sup>13</sup> and Brown RA et al<sup>23</sup> graded thenar atrophy according to the bulk and contour of the thenar eminence. Mild to moderate atrophy consisted of flattening of the thenar eminence and severe atrophy consisted of excavation along the proximal radial border of the thenar eminence. Herbert et al<sup>24</sup> assessed thenar atrophy by palpating the thenar eminence of the hands. In the present study it was attempted to develop a simple test for the objective evaluation of thenar atrophy that eliminates this bias.

In Group 1 for both females and males there was no statistically significant difference between dominant and non-dominant hands, although as expected dominant hands had a slightly higher thenar ratio than the non-dominant hands. Also when comparing females and males, although there was no statistically significant difference between the two males had a slightly higher thenar ratio both for the dominant and non-dominant hands.

Patients in Group 2 had a highly statistically significant lower thenar ratio than subjects in group 1. This is a very positive result as for the purposes of the study. A thenar ratio of 30 was taken as the cutoff for thenar atrophy due to its high sensitivity (95.8%) and acceptable specificity (73.4%). A thenar ratio below 30 indicates thenar atrophy and above 30 indicates absence of thenar wasting. This compares well with the study performed by Tuncali D et al<sup>18</sup> who developed

the thenar index using guache paint static hand imprints and image analysis.

The thenar ratio correlated well with the clinical assessment of thenar atrophy. The more severe the atrophy, the lower the thenar ratio. An interesting finding is that of 22 patients with CTS who had clinical absence of thenar atrophy, 19 of them had a thenar ratio below the cutoff value of 30. The reasons may be due to the difficulty of clinically detecting mild atrophy and/or this subgroup may have 'sub-clinical' atrophy. On the other hand, two subjects in Group 1 had a thenar ratio well below 30. the values were 16.7 and 18.7 in the dominant hand and non-dominant hand respectively. This has also been observed by Tuncali D et al<sup>18</sup> who questioned whether such subjects have isolated thenar atrophy.

During the set-up of the apparatus some technical problems were encountered. Reflections from the camera and surrounding objects produced several artefacts on the photos obtained. As described previously the latter were almost completely eliminated by covering the camera with black cardboard, allowing only space for the lens; and the sides of the box were also covered with black cardboard. Covering the sides of the box left only the glass sheet as the only source of light falling on the camera lens. This meant that the photos taken in the preliminary study were underexposed. Exposure was much improved by increasing the intensity of light in the room by opening windows and switching on overhead neon tubes. Focusing problems were eliminated by setting the camera on macro mode. The photos of two subjects in Group 1 were out of focus due to wet hands.

This novel method can be used as a quantitative, objective test for thenar atrophy and not for diagnosing CTS. The apparatus is very simple to set up. It is quick, non-invasive, has no adverse effects on the patients' health and inexpensive. The computer programmes used in the present study are easy to learn and work with.

However, there are certain limitations and sources of error when using this test. Deformities of the hand and/or fingers both congenital and acquired can impede the application of equal pressure of the hand on the glass sheet leading to abnormal results. The test converts the thenar bulk (three-dimensional) into a photo (two-dimensional). This can also lead to errors in interpreting thenar atrophy quantitatively. One can in the future correlate the thenar ratio with three-dimensional measuring techniques like magnetic resonance

imaging that has already been used to assess intrinsic hand muscle atrophy<sup>7</sup>. Moreover, subjects may exert unequal pressure on the glass sheet. We thought of eliminating this error by loading the hands with a standard mass, however, there would have been a problem as hands have different sizes and palms have variable amount of fat and different skin thickness. Therefore we opted for full force pressure on the glass sheet, the hand positioned in a standard fashion with the fingers abducted and the wrist held in neutral position.

In conclusion this test can be used as an objective test for the assessment and follow-up of thenar atrophy.

## ACKNOWLEDGMENTS

We would like to thank Dr Clive Bezzina MD for his assistance with the recruitment of patients for the study.

## CORRESPONDENCE TO

Name: Mr Laurence A Galea Address: 11, Triq il-Fdal Puniku, Mgarr, Malta –MST 10 Telephone No: +356 21582119 Fax: N/A Email address: laurgalea@hotmail.com

## References

1. Phalen GS. The carpal-tunnel syndrome: Seventeen years' experience in diagnosis and treatment of six hundred fifty-four hands. *J. Bone Joint Surg (Am)* 1966,48(2):211-228.
2. Nambu M, Kaneko K, Iijima T. Biochemical and clinical study of muscle atrophy at thenar and hypothenar eminences in patients with cirrhosis. *Liver* 1996,16(1):19-22.
3. Katirji B, Hardy RW Jr. Classic neurogenic thoracic outlet syndrome in a competitive swimmer: a true scalenus anticus syndrome. *Muscle Nerve* 1995,18(2):229-233.
4. Dellon AL, Trojak JE, Rochman GM. Median nerve compression in Weill-Marchesani syndrome. *Plast. Reconstr Surg*. 1984,74:127-130.
5. Lowry WE Jr, Follender AB. Interfascicular neurolysis in severe carpal tunnel syndrome. A prospective, randomized, double-blind, controlled study. *Clin Orthop Relat Res*. 1988,227:251-254.
6. Leit ME, Weiser RW, Tomaino MM. Patient-reported outcome after carpal tunnel release for advanced disease: a prospective and longitudinal assessment in patients older than age 70. *J Hand Surg (Am)* 2004,29(3):379-383.
7. Martin BI, Levenson LM, Hollingworth W, Kliot M, Heagerty PJ, Turner JA, Jarvik JG. Randomized clinical trial of surgery versus conservative therapy for carpal tunnel syndrome. *BMC Musculoskelet Disord*. 2005,6(1):2.
8. D'Arcy CA, McGee S. The rational clinical examination: Does this patient have carpal tunnel syndrome? *JAMA*. 2000,283(23):3110-3117.
9. Katz JN, Larson MG, Sabra A, Krarup C, Stirrat CR, Sethi R et al. The carpal tunnel syndrome: diagnostic utility of the history and physical examination findings. *Ann Intern Med*. 1990,112(5):321-327.
10. Golding DN, Rose DM, Selvarajah K. Clinical tests for carpal tunnel syndrome: an evaluation. *Br J Rheumatol*. 1986,25(4):388-390.
11. Gerr F, Letz R, Harris-Abbot D, Hopkins LC. Sensitivity and specificity of vibrometry for the detection of carpal tunnel syndrome. *J Occup Environ Med*. 1995,37(9):1108-1115.
12. Nolan WB 3rd, Alkatis D, Gilckel SZ, Snow S. Results of treatment of severe carpal tunnel syndrome. *J Hand Surg (Am)*. 1992,17(6): 1020-1023.
13. Gelberman RH, Pfeffer GB, Galbraith RT, Szabo RM, Rydevik B, Dimick M. Results of treatment of severe carpal-tunnel syndrome without internal neurolysis of the median nerve. *J Bone Joint Surg (Am)*. 1987,69(6):896-903.
14. Rhoades CE, Mowery CA, Gelberman RH. Results of internal neurolysis of the median nerve for severe carpal-tunnel syndrome. *J Bone Joint Surg (Am)*. 1985,67(2):253-256.
15. Manktelow RT, Binhammer P, Tomat LR, Bril V, Szalai JP. Carpal tunnel syndrome: cross-sectional and outcome study in Ontario workers. *J Hand Surg (Am)*. 2004,29(2):307-317.
16. Thurston A, Lam N. Results of open carpal tunnel release: a comprehensive, retrospective study of 188 hands. *Aust N Z J Surg*. 1997,67(5):283-288.
17. Andreisek G, Kilgus M, Burg D, Saupe N, Crook DW, Meyer V et al. MRI of the intrinsic muscles of the hand: spectrum of imaging findings and clinical correlation. *AJR Am J Roentgenol*. 2005,185(4):930-939.
18. Tuncali D, Barutcu AY, Terzioglu A, Uludag K, Aslan G. The thenar index: an objective assessment and classification of thenar atrophy based on static hand imprints and clinical implications. *Plast Reconstr Surg*. 2006, 117(6):1916-1926.
19. Arons JA, Collins N, Arons MS. Results of treatment of carpal tunnel syndrome with associated hourglass deformity of the median nerve. *J Hand Surg (Am)*. 1999, 24(6):1192-1195.
20. Richman JA, Gelberman RH, Rydevik BL, Hayek PC, Braun RM, Gyllys-Morin VM, Berthoty D. Carpal tunnel syndrome: morphologic changes after release of the transverse carpal ligament. *J Hand Surg (Am)*. 1989, 14:852-857.
21. Tanzer RC. The carpal tunnel syndrome: a clinical and anatomical study. *J Bone Joint Surg (Am)*. 1959, 41(4):626-634.
22. Mondelli M, Reale F, Padua R, Aprile I, Padua L. Clinical and neurophysiological outcome of surgery in extreme carpal tunnel syndrome. *Clin neurophysiol*. 2001, 112(7):1237-1242.
23. Brown RA, Gelberman RH, Seiler JG 3rd, Abrahamsson SO, Weiland AJ, Urbaniak JR et al. Carpal tunnel release: a prospective, randomised assessment of open and endoscopic methods. *J Bone Joint Surg (Am)*. 1993, 75(9):1265-1275.
24. Herbert R, Gerr F, Dropkin J. Clinical evaluation and management of work-related carpal tunnel syndrome. *Am J Ind Med*. 2000, 37(1):62-74.

**Author Information**

**Laurence A. Galea, MRCS(Ed)**

Department of Surgery and the Department of Orthopaedics, St Luke's Hospital

**John Agius, MRCS(Ed)**

Department of Surgery and the Department of Orthopaedics, St Luke's Hospital

**Charles Sciberras, FRCS(Glas)**

Department of Surgery and the Department of Orthopaedics, St Luke's Hospital