

Bladder Stone Due To Migration Of Permanent Urethral Wall Stent

C Tuygun, N Sertcelik, O Yigitbasi, I Alisir, K Zengin, A Imamoglu

Citation

C Tuygun, N Sertcelik, O Yigitbasi, I Alisir, K Zengin, A Imamoglu. *Bladder Stone Due To Migration Of Permanent Urethral Wall Stent*. The Internet Journal of Urology. 2005 Volume 4 Number 1.

Abstract

Currently, there are many studies about permanent urethral wall stent migration in first year in the literature. We herein present this rare complication with development of a ring shaped bladder stone around the stent and its' treatment.

INTRODUCTION

In this case report, we present a 58 year old male patient who had posterior urethral stricture secondary to posterior urethral injury with multiple unsuccessful surgical repairs.

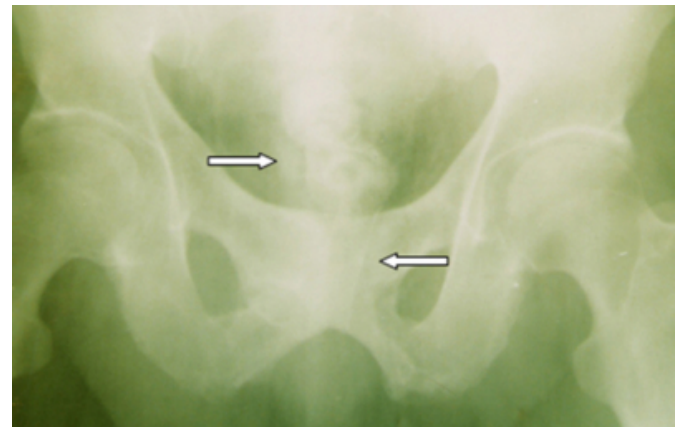
CASE REPORT

A patient had a history of posterior urethral injury after having a motor vehicle accident in 1993. He immediately underwent a urethral re-alignment operation but urinary retention was developed within 2 months due to urethral stricture. He then underwent 5 consecutive internal urethrotomies and performed self dilatation in long-time. After 5 years, two urethral wall stents (Urolume® AMS) were placed in the posterior urethra because he has persistent urethral stricture disease. After this time, he lost the follow-ups for 3 years. He returned with urinary retention to our clinic. He was hospitalized and a suprapubic catheter was inserted.

The migrated wall stent and radioopacity consistent with bladder stone were showed on the pelvic image (figure 1).

Figure 1

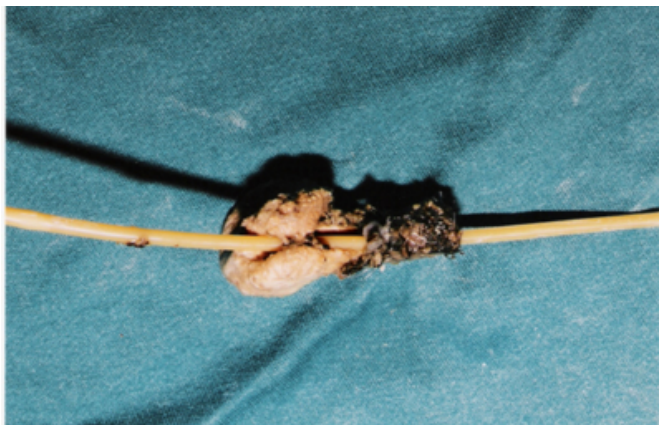Figure 1: Migrated urethral stent with bladder stone.



During endoscopic examination, the lumen of the stents was obstructed by epithelial hyperplasia. After opening of the obstructed lumen by transurethral resection, we noted that that the proximal part of stent migrated into the bladder and incorporated with a yellow colored stone with a central hole (figure 2).

Figure 2

Figure 2: Petrified urethral stent with ring shape.



The migrated urolume with stone were removed by open suprapubic approach.

DISCUSSION

In fact, the treatment of bulbar urethral strictures after repair of traumatic urethral rupture by urethral realignment is very difficult. Implantation of urethral wall stent is not always curable because high risk of hyperplastic tissue growth in the lumen of stent. On the other hand, it has been reported that the complex urethral strictures might treated with urethral stents in some patients (^{1,2}). The epithelisation with hyperplastic reaction causes to recurrent stenosis beyond or front of stent, which further requires internal urethral operations or resection, due to etiology of urethral strictures (^{1,3}).

The other complication of urethral stents is migration and it is seen in about 4% (^{3,4}). In the long-term follow-ups of patients with urethral stent, the ratio of removal of stent due to complications is between 15% and 43% of these removals are in the first year of implantation. In 38% of these cases, causes of removals are migration or inappropriate implantation (⁶). Rarely, patients' self digital rectal application resulted in migration of temporary urethral stent in late period (⁷). In our case, we thought that the cause of migration and petrification of stent after 3 years might be patients' self catheterization. Because a hole developed in the bladder stone for entrance of urethral catheter due to applied self-dilatation. This complication results in urinary obstruction and stone formation around the stent in long

term.

The first choice for the treatment of migrated urethral stent is fragmentation of stent by Holmium-YAG laser (^{8,9}). But, we preferred suprapubic incision instead of YAG laser because the stone had a large size and fixed to the urolume.

CONCLUSIONS

The treatments of urethral strictures with using urethral wall stent are not always curable in some patients. Therefore, the patient selection for this treatment is the most important factor for successful results. Additionally, the follow-ups of patients with urethral stent must kept on with regular intervals for minimize complications.

CORRESPONDENCE TO

Can Tuygun Hosdere cd. Etitek sitesi 115/72. Yukari Ayranci, Ankara-Turkey. Tel: +90 312 418 28 78 Fax: +90 312 424 00 40 E-mail:tuyguncan@yahoo.com

References

1. Sertçelik N, Sagnak L, Imamoglu MA, Temel M, Tuygun C. The use of self-expanding metallic urethral stents in the treatment of recurrent bulbar urethral strictures. *BJU International* 2000; 86: 686-9
2. Scarpa RM, De Lisa A, Porru D, Paulis M, Usai E. Urolume double prosthesis in the treatment of complex urethral strictures: a 5-year follow-up case report. *Urology* 1997; 50(3): 459-61.
3. Badlani GH, Press SM, Defalco A, Oesterling JE, Smith AD. Urolume endourethral prosthesis for the treatment of urethral stricture disease: Long-term results of the North American Multicenter urolume Trial. *Urology* 1995; 45:846-56
4. Oesterling JE. Urologic applications of a permanent, epithelializing urethral endoprosthesis. *J Urol.* 1993; 41: 10-8
5. Schnapp DS, Badlani GH. Treatment of recurrent bulbar urethral strictures using the Urolume endoprosthesis: the North American experience. *J Endourol.* 1993; 7: 113
6. Shah DK, Kapoor R, Badlani GH. North American Study Group. Experience with Urethral stent explantation. *J.Urol.* 2003; 169(4):1398-400
7. Subramanian V, Bakul MS, Tun Oo, Pradipkumar S, Peter LH, Gurpreet S. Long-term results of Memokath Urethral sphincter stent in spinal cord injury patients. *BMC Urology* 2002; 2(12): 37-46
8. Lallas CD, Munver R, Preminger GM. Removal of a urolume prostatic stent using the Holmium laser. *Urology* 2001; 57(1): 166-7
9. Kural AR, Tufek I, Akpınar H, Gurtug A. Removal of urolume endoprosthesis using Holmium: YAG laser. *J Endourol.* 2001; 15(9):947-8

Author Information

Can Tuygun

Department of Urology, S.B. Diskapi Yüldirim Beyazit Training and Research Hospital

Nurettin Sertcelik

Department of Urology, S.B. Diskapi Yüldirim Beyazit Training and Research Hospital

Orhan Yigitbasi

Department of Urology, S.B. Diskapi Yüldirim Beyazit Training and Research Hospital

Inan Alisir

Department of Urology, S.B. Diskapi Yüldirim Beyazit Training and Research Hospital

Kursad Zengin

Department of Urology, S.B. Diskapi Yüldirim Beyazit Training and Research Hospital

Abdurrahim Imamoglu

Department of Urology, S.B. Diskapi Yüldirim Beyazit Training and Research Hospital