

# Traumatic Eagle Syndrome: Does Neck Trauma Result in Complete Ossification in Partially Ossified Stylohyoid Ligament?

A Olusesi

---

## Citation

A Olusesi. *Traumatic Eagle Syndrome: Does Neck Trauma Result in Complete Ossification in Partially Ossified Stylohyoid Ligament?*. The Internet Journal of Otorhinolaryngology. 2005 Volume 4 Number 2.

## Abstract

Eagle syndrome (ES) is a constellation of symptoms and signs resulting from abnormal stylohyoid chain ossification [1]. The styloid chain consists of the styloid process, the stylohyoid ligament, and the lesser cornu of the hyoid bone [2]. ES is a rare entity which is not commonly suspected in clinical practice [3], and only a small percentage of the 4% of population believed to have an elongated styloid process and a calcified stylohyoid ligament manifest the symptoms [4]. The symptoms are a foreign-body sensation in the throat, dysphagia, and intermittent facial pain related to an elongated styloid process and a calcified stylohyoid ligament [5]. Other frequent symptoms include headache, pain on rotation of the neck, pain on extension of the tongue, change in voice, and a sensation of hyper salivation [6]. The diagnosis is often first made radiologically and once made this prompts clinical confirmation by palpation of the tonsillar fossa. We present a case of a 50-year old physician presents with progressive but intermittent voice change of 1 year duration and dysphagia of 2 weeks duration.

## CASE REPORT

A 50-year old physician presents with progressive but intermittent voice change of 1 year duration and dysphagia of 2 weeks duration. Her progressive voice change was noticed by friends. She denied associated odynophonia, voice fatigue or history of vocal abuse. She described her dysphagia as “trying to overcome a constriction on swallowing”. The dysphagia was to both solids and liquids. There was no associated cough, dyspnoea, or orthopnoea or regurgitation of feeds. She had no antecedent history of corrosive ingestion. She gave a long standing history of high pitch tinnitus in the left ear which she attributed to a ‘bad cold’ of 10 years duration. The tinnitus was associated with reduced hearing on the left.

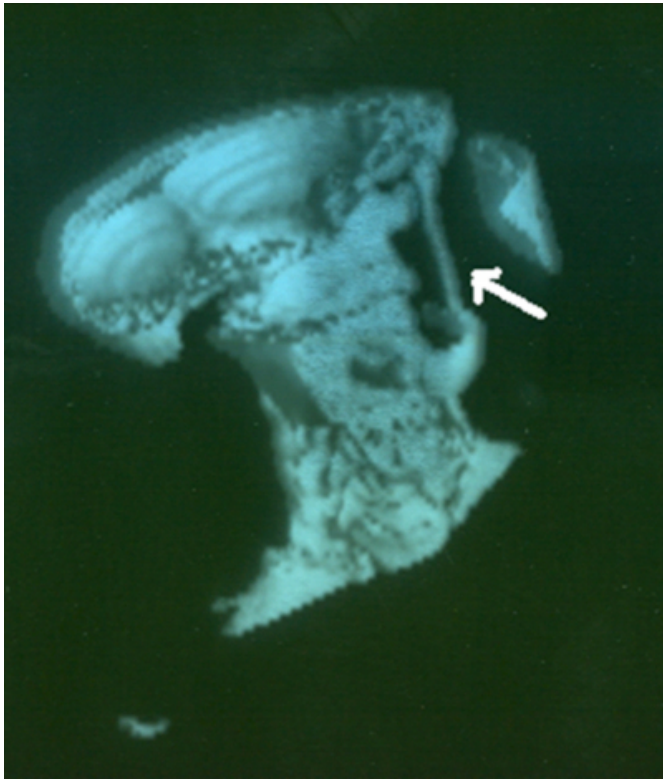
She had a past history of neck injury following road traffic accident 5 years earlier. The neck pain resulted when a car she was traveling in went into a ditch and her head was thrown against the roof of the car. She experienced severe neck pains for months after the accident.

Her general examination was not significant. Neck examination revealed difficulty in palpating the hyoid bone. The thyroid cartilage was normal. There were no palpable neck nodes, and normal laryngeal crepitus was found.

Oropharyngeal examination was normal. No abnormality was found on indirect laryngoscopy. Plain lateral soft tissue x-ray of neck revealed calcification of the stylohyoid ligaments. The only significant finding on axial, coronal [Figures 1a, 1b] and sagittal [Figure 2] reconstruction images and volume rendered reconstruction of CT-Scan of neck was dense ossification of both stylohyoid ligaments in their entire extent. The stylohyoid ligaments measured 47 and 45mm on the right and left respectively. The outline of the ossified ligaments is normal and no focal mass effect is seen.

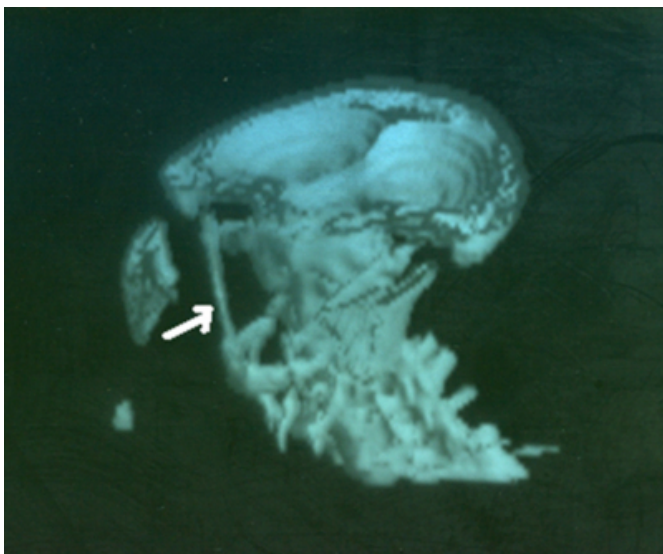
**Figure 1**

Figures 1a: Coronal CT-Scan reconstruction images and volume rendered reconstruction. White arrow indicates calcified right stylohyoid ligament



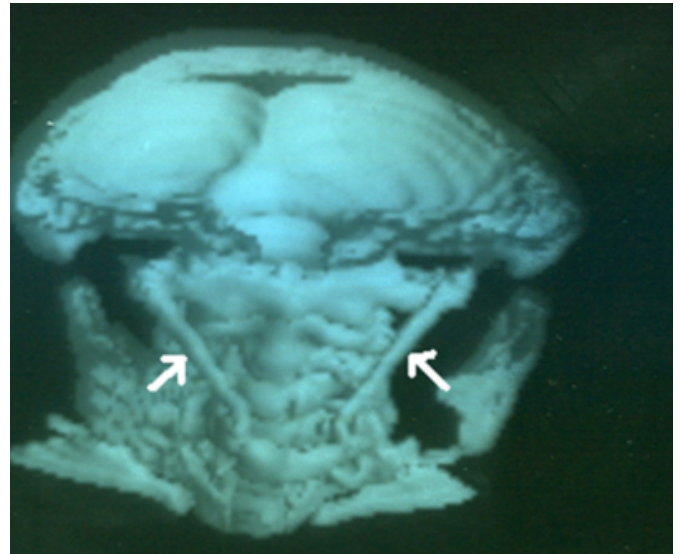
**Figure 2**

Figure1b: Coronal CT-Scan reconstruction images and volume rendered reconstruction. White arrow shows calcified left stylohyoid ligament



**Figure 3**

Figure2: Saggital CT-Scan reconstruction images and volume rendered reconstruction. White arrows show bilateral calcified stylohyoid ligament



## DISCUSSION

Eagle syndrome (ES) is a constellation of symptoms and signs resulting from abnormal stylohyoid chain ossification [1]. The styloid chain consists of the styloid process, the stylohyoid ligament, and the lesser cornu of the hyoid bone [2]. ES is a rare entity which is not commonly suspected in clinical practice [3], and only a small percentage of the 4% of population believed to have an elongated styloid process and a calcified stylohyoid ligament manifest the symptoms [4]. The symptoms are a foreign-body sensation in the throat, dysphagia, and intermittent facial pain related to an elongated styloid process and a calcified stylohyoid ligament [5]. Other frequent symptoms include headache, pain on rotation of the neck, pain on extension of the tongue, change in voice, and a sensation of hyper salivation [6]. The diagnosis is often first made radiologically and once made this prompts clinical confirmation by palpation of the tonsillar fossa.

Though the original classical description of ES was in patients with a history of tonsillectomy, the Pathophysiology of symptoms is not well understood. Factors blamed as possible causes include previous trauma or an inflammatory process that produces a proliferation of granulation tissue and results in calcification or ossification [4].

ES can be unilateral or bilateral. In normal adults, the styloid process is approximately 25mm long, and its tip is located between the external and internal carotid arteries, just lateral

to the tonsillar fossa [7]. Elongation of this styloid process or calcification of persistent stylohyoid ligament can exacerbate the effect of whiplash injuries [8]. The mineralized section of the styloid process or stylohyoid ligament is rigid and more subjected to fracture secondary to traumatic injury [9].

Mangano & Nylander reported a case of ES that occurred after an automobile accident and caused by cervicopharyngeal trauma [10]. Similar cases of traumatic ES have been reported by previous studies [11, 12, 13]. Our patient had vivid recollection of the cervical trauma she sustained 4 years before onset of dysphagia and voice change as soon as diagnosis was made and explained to her, though her only long-standing symptom was unexplained left-sided tinnitus for over 10 years. Subramaniam & Majid reported a 48-year old female with bilateral ES who had bilateral upper neck pain radiating up to the ears and tinnitus [14]. Dinkar & Amonkar however reported a case with bilateral elongation but unilateral symptom [15]. Though none of these 2 reported cases had significant history of trauma, our patient had unilateral (left-sided) tinnitus preceding neck trauma, and dysphagia and voice change 4 years following neck trauma, but no cervical or facial pain. She also has radiological features of bilateral stylohyoid calcification with the left stylohyoid slightly shorter than the right. We do not know whether the shorter length of the left stylohyoid ligament could explain the tinnitus in our patient. We also do not have pre-trauma radiogram of this patient to compare. The CT finding did not include evidence of old or healed fracture involving the stylohyoid complex and this made us to suspect that mineralization of the stylohyoid ligament might have occurred after the trauma.

We also do not know whether the finding of bilateral calcified stylohyoid ligament in our patient could be an anatomical variant. Rizzatti-Barbosa et al reported that in the Brazilian population, 90% of those with anatomical finding of elongated mineralized stylohyoid complex were in the age range 40 – 59 years [16]. We suspect that the initial tinnitus in our patient might have resulted from partial mineralization of left stylohyoid ligament, and that the neck trauma might have stimulated heterotrophic calcification that completed

the process of stylohyoid mineralization. Ilguy et al using panoramic radiographs on 860 subjects to study incidence of elongated styloid process recently reported that partial left sided calcification is commoner than complete right sided calcification. [17].

## References

1. Chouvel P, Rombaux P, Philips C, Hamoir M.: Stylohyoid chain ossification: choice of the surgical approach. *Acta Otorhinolaryngol Belg.* 1996;50(1):57-61.
2. Chi J, Harkness M: Elongated stylohyoid process: a report of three cases. *N Z Dent J.* 1999 Mar;95(419):11-3.
3. Fini G, Gasparini G, Filippini F, Becelli R, Marcotullio D: The long styloid process syndrome or Eagle's syndrome. *J Craniomaxillofac Surg.* 2000 Apr;28(2):123-7
4. Santiago Restrepo, Enrique Palacios, Rafael Rojas: Eagle's syndrome - Imaging Clinic. *Ear, Nose & Throat Journal*, Oct, 2002.
5. Baugh RF, Stocks RM. Eagle's syndrome: A reappraisal. *Ear Nose Throat J* 1993;72:341-4.
6. Baugh RF, Stocks RM. Eagle's syndrome: a reappraisal. *Ear Nose Throat J* 1993;72:341-344
7. Balbuena L Jr, Hayes D, Ramirez SG, Johnson R: Eagle's syndrome (elongated styloid process). *South Med J.* 1997 Mar;90(3):331-4.
8. Miller DB: Eagle's syndrome and the trauma patient. Significance of an elongated styloid process and/or ossified stylohyoid ligament. *Funct Orthod.* 1997 Mar-Apr;14(2):30-5.
9. Babad MS: Eagle's syndrome caused by traumatic fracture of a mineralized stylohyoid ligament--literature review and a case report. *Cranio.* 1995 Jul;13(3):188-92.
10. Manganaro AM, Nylander J: Eagle's syndrome: a clinical report and review of the literature. *Gen Dent.* 1998 May-Jun;46(3):282-4
11. Perez Carro L, Nunez MP: Fracture of the styloid process of the temporal bone. A case report. *Int Orthop.* 1995;19(6):359-60.
12. Schroeder WA Jr.: Traumatic Eagle's syndrome. *Otolaryngol Head Neck Surg.* 1991 Mar; 104(3):371-4.
13. Smith GR, Cherry JE: Traumatic Eagle's syndrome: report of a case and review of the literature. *J Oral Maxillofac Surg.* 1988 Jul;46(7):606-9.
14. Subramaniam S, Majid MD: Eagle's syndrome. *Med J Malaysia.* 2003 Mar; 58(1):139-41.
15. Dinkar, Amonkar SS: Eagle's syndrome: review of literature and case report. *Indian J Dent Res.* 2003 Jul-Sep; 14(3):162-8.
16. Rizzatti-Barbosa CM, Ribeiro MC, Silva-Concilio LR, Di Hippolito O, Ambrosano GM: Is an elongated stylohyoid process prevalent in the elderly? A radiographic study in a Brazilian population. *Gerodontology.* 2005 Jun;22(2):112-5.
17. Ilguy M, Ilguy D, Guler N, Bayirli G: Incidence of the type and calcification patterns in patients with elongated styloid process. *J Int Med Res.* 2005 Jan-Feb;33(1):96-102.

**Author Information**

**A. D. Olusesi, FWACS, FMCORL**

Department of Ear, Nose & Throat, National Hospital