

An IVDU With A Swollen Chest

M Zakkar, J Turner, P Punjabi

Citation

M Zakkar, J Turner, P Punjabi. *An IVDU With A Swollen Chest*. The Internet Journal of Surgery. 2005 Volume 7 Number 2.

Abstract

Osteomyelitis of the sternum is a rare clinical entity and can be difficult to diagnose. Treatment requires antibiotics and complete debridement of all infected tissue, with reconstruction later. We present a case of osteomyelitis post blunt trauma in an iv drug addict and management method.

CASE REPORT

A 43 year old heavily tattooed intravenous drug addict presented to the A&E department with two days history of anterior chest wall pain following blunt trauma, No past medical history of note, except a previous partial gastrectomy following stabbing two years earlier.

On examination he was haemodynamically stable, afebrile, with an area of erythema and tenderness over the anterior chest wall extending horizontally from the left nipple to the right axilla. On auscultation breath sounds were unremarkable. He had a mid-line abdominal surgical scar and soft abdomen with no organomegaly.

Laboratory tests showed white cell count of (10.5) and CRP of (35).

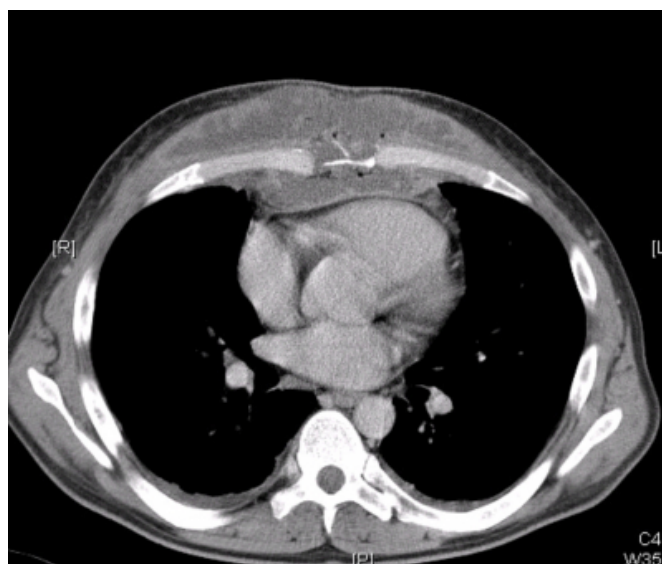
Chest x-ray was unremarkable so an initial diagnosis of cellulitis was made and admission to hospital was advised however the patient refused and was discharged against medical advice on a course of oral antibiotics.

Five weeks later he re-attended the A&E department feeling unwell. He was pyrexial with a fluctuant mass extending over the anterior chest wall where the erythema had been previously documented.

Laboratory investigations revealed leucocytosis (19.4) and raised CRP (244) chest x-ray showed soft tissue swelling with normal lung fields. The urgently arranged CT scan showed a huge collection into both pectoral muscle groups and extensive destruction of the lower sternum and a large anterior mediastinal collection containing gas bubbles (fig 1).

Figure 1

Figure 1



An urgent echo confirmed the presence of a large collection in the pre-pericardium but the heart was not compromised with no evidence of vegetation.

He was started initially on a large dose of broad spectrum antibiotics that were later adjusted after *S. Aureus* was found in the blood culture. An urgent surgical exploration with evacuation of abscess and extensive debridement of the sternum was carried out initially. A second look was performed 48 hours later with the application of vacuum pump dressing.

Regular monitoring of the inflammatory markers showed good response to treatment as white cell count came down to (11.1) and CRP to (9). A week later after a subclavian angiography confirmed the patency of the right internal thoracic artery a reconstruction operation using a transsectus

abdominis myocutaneous flap was carried out with uneventful recovery.

DISCUSSION

Osteomyelitis of the sternum is a rare condition that can affect any age group although less frequent in children^(1,2,4,6) It can be divided into primary when no contiguous focus of infection can be found, and secondary which is usually a complication of sternotomy. Risk factors include recent trauma, diabetes, immuno-suppression, and IV drug abuse^(1,3).

Staphylococcus aureus is the most common pathogen except in IV drugs abusers, organisms are predominantly *Pseudomonas* species, although other rarer pathogens include Tuberculosis, and *Aspergillus* species may be found^(1,6)

It can present as chest wall pain, tenderness, redness, and swelling, but most of the times the symptoms can be non specific which makes it difficult to recognize in the early stages^(1,2) which in turn can lead to increase mortality and other serious sequelae. the diagnosis should be considered in patients presenting with acute inflammatory swelling over the sternum. Although laboratory investigations such as white cell count and inflammatory markers can help none is specific and confirming the diagnosis requires radiographic imaging like plain x-ray or CT.scan, which can demonstrate the bony lesion.

Optimum treatment involves broad –spectrum antimicrobial therapy and debridement of all the involved bone and cartilage with delayed reconstruction as early recurrence is most likely due inadequate removal of involved cartilages.

Reconstruction in later stages is important to restore anatomical defect and to compensate for the physiological deficit. This can be carried out using prosthetic materials, or myoplasties which are more suitable post infection because they resist infection better in previously contaminated field⁽⁵⁾

Although few cases of sternal osteomyelitis have been reported in IV drug abusers, the bacteria involved was always *Pseudomonas aeruginosa*. This case highlights the importance of keeping an open mind and considering different causes when dealing with such a difficult problem and emphasize the impact of early intervention on both mortality and morbidity.

CORRESPONDENCE TO

Mr. Mustafa Zakkar BHF Clinical research fellow Imperial College School of Medicine Hammersmith Hospital Campus Du Cane Road London W12 0NN UK Tel: 020 8383 1615 E-Mail: m.zakkar@imperial.ac.uk

References

1. Kaw, Dinkar MD; Yoon, Youngsook MD Southern Medical Journal. 97(7):705-706, July 2004. *Pseudomonas Sternoclavicular Pyarthrosis*.
2. D Allen, S Ng, K Beaton and D Taussig, j-clin.pathol.2002;55:616, sternal osteomyelitis caused by *Aspergillus fumigatus* in a patient with previously treated Hodgkin's disease
3. Mofredj A, Guerin JM, Leibinger F, Masmoudi R : Primary sternal osteomyelitis and septicemia due to *Staphylococcus aureus*. Scand J Infect Dis. 1999;31(1):98-100.
4. Lin JC, Miller SR, Gazzaniga AB. Primary sternal osteomyelitis. Ann Thor Surg 1996; 61: 225-7
5. 22-Arnold PG, Pairolero PC. Chest wall reconstruction: an account of 500 consecutive patients. Plast Reconstr Surg 1996; 98: 804-10
6. Kelly CA, Chetty MN. Primary sternal osteomyelitis. Thorax 1985;40:872-3 (staph is the most common)

Author Information

M. Zakkar, MRCS

Department of Surgical Oncology and Technology, Faculty of Medicine, Imperial College

J. Turner, MBBS

Department of Surgical Oncology and Technology, Faculty of Medicine, Imperial College

P. Punjabi, FRCS

Department of Surgical Oncology and Technology, Faculty of Medicine, Imperial College