

Cirrhosis Of Liver Presenting As Acute Right Sided Pleural Effusion

S Bhatram, M Pulluru, S Bachala, K Chand

Citation

S Bhatram, M Pulluru, S Bachala, K Chand. *Cirrhosis Of Liver Presenting As Acute Right Sided Pleural Effusion*. The Internet Journal of Gastroenterology. 2006 Volume 5 Number 2.

Abstract

An elderly lady came to the casualty department with abdominal pain and vomiting of 1 day duration. She responded to symptomatic treatment. Hence she requested a discharge. The next day she was readmitted with severe breathlessness. Evaluation this time revealed a large right sided pleural effusion. The effusion was drained through an intercostal tube. The fluid was a transudate. Large amount of fluid was drained out of the intercostal tube daily. Detailed evaluation to decipher the cause of transudative effusion pointed to underlying cirrhosis of liver. Presence of a transudative pleural effusion in the absence of a significant ascitis suggested the existence of a pleuro-peritoneal communication. Tc 99m Sulphur colloid isotope scan was done. The scan showed clearance of colloid particles from peritoneal to pleural cavity. The patient was managed with albumin infusion, diuretics; and salt and fluid restriction. Pleural fluid drainage decreased with this intensive treatment.

INSTITUTE WHERE THE WORK WAS DONE

Sri Venkateswara Institute of Medical Sciences, Tirupathi, Andhra Pradesh, India. PIN 517 507

CASE REPORT

A 66-year old lady, a diabetic for the past 20 years, was brought to the casualty department for abdominal pain and vomiting. She was given symptomatic treatment. As she was relieved of her symptoms she requested for a discharge, the same day. The cause for the abdominal pain at that stage was not established. She came back to the casualty the next morning with severe breathlessness. Evaluation this time showed a large pleural effusion on the right side. In view of severe breathlessness, an intercostal tube was passed to drain the fluid. The pleural fluid was a transudate.

The cause for this transudative pleural effusion was investigated into. Her cardiac and renal functions were normal. Serum albumin was on the lower side (2.9g) with serum globulin (3.3g) on the elevated side. Ultrasound of abdomen depicted an increased echo-texture of liver with minimal ascitis. Portal and Hepatic veins were normal. There was no splenomegaly. Multiple gall stones were seen. Pelvic organs were normal. As the ascitic fluid was not detectable clinically, an ultrasound guided aspiration of the fluid was done and sent for analysis. Ascitic fluid was a transudate; with serum ascitic fluid albumin gradient more than 1.1gm%. Upper gastrointestinal endoscopy showed the

presence of oesophageal varices. When questioned retrospectively, she disclosed a history of jaundice 6 months prior to the present admission. Concluding upon these findings, the cause for ascitis was presumed to be a chronic liver disease (cirrhosis). Her blood was negative for HBSAg, anti-HCV and ANA. What remained unclear was the cause of a sudden right-sided pleural effusion. To explain this, it was postulated that the right pleural effusion developed because of a spontaneous communication that formed across the right dome of diaphragm during the initial vomiting. In order to demonstrate the communication, scintigraphy using Tc 99m sulphur colloid was done. The scintigraphy demonstrated the entry of the radiocolloid into the right pleural cavity and then into the chest tube in about half an hours hour time.

Figure 1

Figure 1: Chest X-ray PA view showing large right sided pleural effusion.

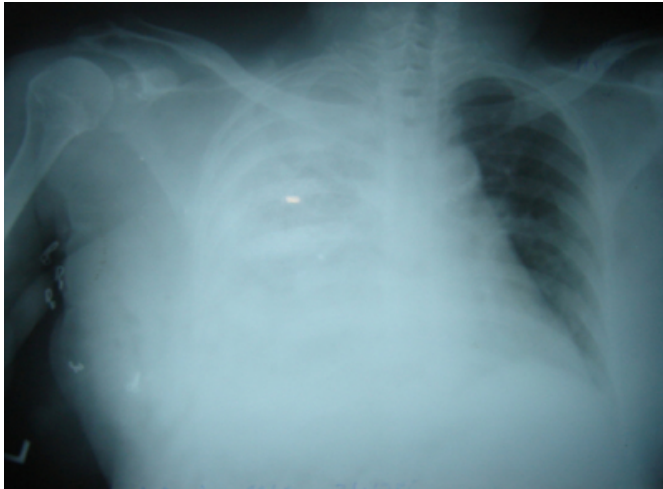

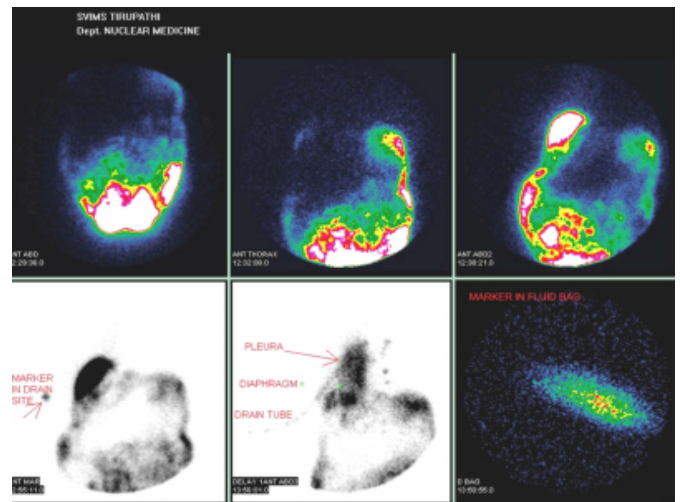
Figure 2

Figure 2: Chest X-ray PA view showing intercostal tube in place with expanded right lung.

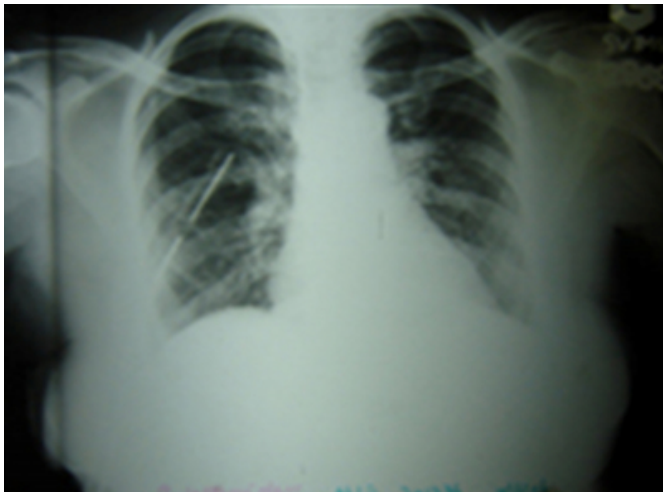

Figure 3

Figure 3: Tc 99m Sulfur colloid instilled into peritoneal cavity is seen migrating into right pleural cavity and from there into the drainage bag via the intercostal tube.



She was put on strict salt and fluid restriction, Human albumin infusions and spirinolactone tablets. With these measures the quantum of pleural fluid that was draining out, decreased. The inter-costal tube was removed once the daily drained fluid was less than 50ml. She was stable at the time of discharge.

Two weeks after discharge, on her return for a review in the Out-patient department, she had no pleural effusion.

DISCUSSION

Cirrhosis of liver can be associated with a right sided pleural effusion in about 5% of cases. In the absence of cardiac or lung disease, the presence of a pleural effusion in a cirrhotic patient is known as hepatic hydrothorax [1]. This can at times occur in the absence of clinically obvious ascitis. Three causes of hepatic hydrothorax have been proposed, namely leakage from the thoracic duct, leakage through lymphatic channels in the diaphragm and leakage through defects in the diaphragm. In majority of cases the cause is a rent in the diaphragm. Spontaneous rents in the diaphragm are known to occur following vomiting. In the elderly, the initial episode may go unrecognized because of their poor ability to perceive symptoms.

The best test to demonstrate the defect in diaphragm is to instill sulphur colloid radioisotope into the peritoneal cavity and demonstrate its migration into the pleural cavity after a short interval. [2]

Placing an intercostal tube for a transudative pleural effusion is not a safe procedure. It is said to be associated with

considerable increase in mortality in these cases. [3]
However in this case, considering the acuteness of breathlessness, passing the tube was perhaps justified. Draining the pleural fluid together with diuretics and albumin infusion is the best way of managing these cases. Various other methods like use of octreotide, TIPS and pleurodesis have been tried with success in some of the studies [4,5,6]:

CORRESPONDENCE TO

Dr.B.Siddhartha Kumar, Associate Professor of Medicine,
Sri Venkateswara Institute of Medical Sciences Tirupathi
517507 AP, India Email: siddhartha1759@yahoo.co.in
Phone No. 91-877-2249844

References

1. Strauss RM, Boyer TD. Seminars in liver diseases 1997;

17(3): 227-32.

2. Promila punkaj, Vivek Pathak, Ishta B.sen, Ritu verma, A.K.Bhalla, A.Marwahe et. al. use of Radionucleotide peritoneography in the diagnosis of pleuroperitoneal communication as a complication of continuous ambulatory peritoneal dialysis. Indian journal of Nuclear Medicine. 20(1):4-8, 2005.

3. Lawrence U. Liu, MD; Hassan A. Haddadin, MD; Carol A. Bodian, DrPH; Samuel H. Sigal, MD; Jessica D. Korman, BA; Henry C. Bodenheimer, Jr, MD and Thomas D. Schiano,MD. Outcome Analysis of Cirrhotic Patients Undergoing Chest Tube Placement.Chest.2004; 126:142-148.

4. Mouroux J, Perrin C, Venissac N, Blaive B, Richelme H. Management of pleural effusion of cirrhotic origin. Chest. 1996 Apr; 109(4):1093-6.

5. Rubinstein D, McInnes IE, Dudley FJ. Hepatic hydrothorax in the absence of clinical ascites: diagnosis and management.Gastroenterology. 1985 Jan; 88(1 Pt 1):188-91.

6. Andrade RJ, Martin-Palanca A, Fraile JM, et al. (1996). Transjugular intrahepatic portosystemic shunt for the management of hepatic hydrothorax in the absence of ascites. J Clin Gastroenterol 22:305-7.

Author Information

Siddhartha Kumar Bhatram, M.D.

Associate Professor of Medicine, Sri Venkateswara Institute of Medical Sciences

Mohan Babu Pulluru, MBBS

Resident in Medicine, Sri Venkateswara Institute of Medical Sciences

Subramanyam Bachala, MD

Professor of Medicine, Sri Venkateswara Institute of Medical Sciences

Kalawat Tek Chand, DNB

Associate Prof of Nuclear Medicine, Sri Venkateswara Institute of Medical Sciences