

Metatypical Basal Cell Carcinoma of the Nose

E Santos, D Sarma, M Chen, B Wang

Citation

E Santos, D Sarma, M Chen, B Wang. *Metatypical Basal Cell Carcinoma of the Nose*. The Internet Journal of Dermatology. 2006 Volume 5 Number 2.

Abstract

We report a case of metatypical basal cell carcinoma on the nose of a 79-year-old woman with a brief review of the literature.

REPORT OF A CASE

A 79-year-old woman presented with a painless lesion on her nose. The lesion was roughly oval with focal gray discoloration and a slightly raised central portion. She reported no other associated symptoms and denied having other similar skin lesions. Her past medical history was otherwise unremarkable.

On microscopic examination of the submitted shave biopsy, the lesion showed skin with a loosely circumscribed dermal proliferation of lobules of epithelioid cells. Nuclear enlargement with chromatin clumping with or without macronucleoli, and a moderate amount of eosinophilic cytoplasm was present. Most prominent were few numbers of haphazardly placed giant cells with no associated foreign bodies or granulomas. The overlying epithelium was atrophic with focal parakeratosis. There was no direct connection between the epidermis and the atypical dermal proliferation, and no clefting was identified. The mitotic activity was approximately 1-2 mitoses per high power field (40x). Multiple immunohistochemical stains were performed which demonstrated positive staining for pancytokeratin (AE1:3), bcl-2, and BerEp4.

Figure 1

Figure 1: Dermal proliferation of epithelia cells with enlarged nuclei, eosinophilic cytoplasm and lack of clefting and palisading.

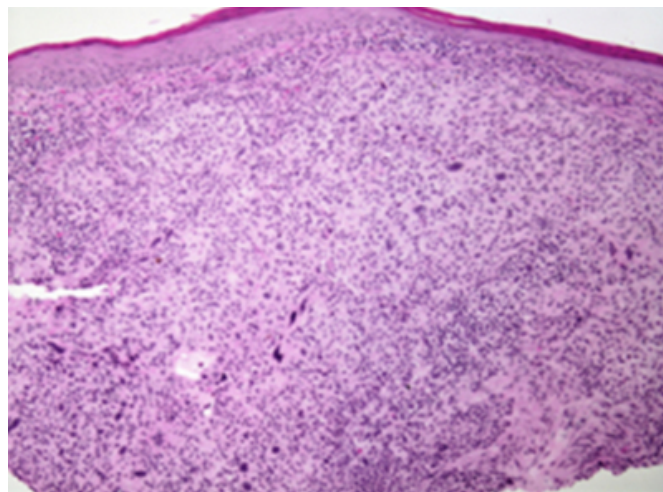


Figure 2

Figure 2: High power view of tumor and giant cells.

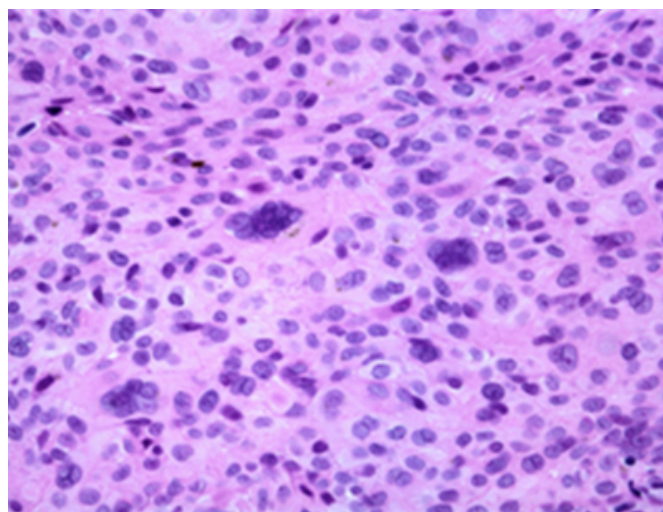


Figure 3

Figure 3: Positive immunostaining of tumor cells for bcl-2.


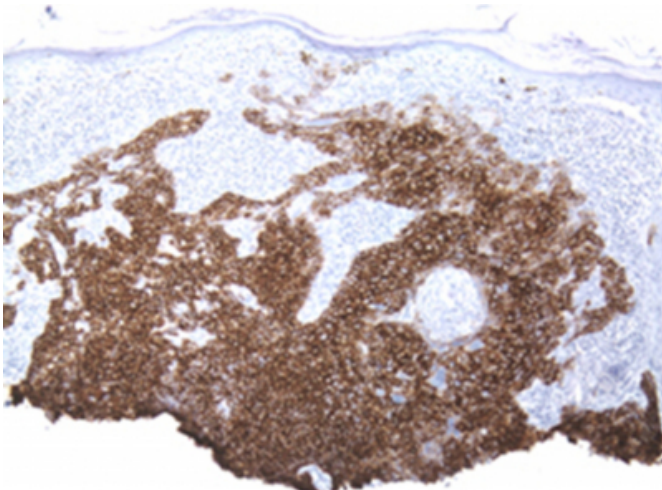


Figure 4

Figure 4: Positive immunostaining of tumor cells for Ber-Ep4.



COMMENT

Metatypical basal cell carcinoma is a rare variant of basal cell carcinoma (BCC), first described in 1922 [1]. Although its occurrence is rare, the clinical history may be the same as

that seen in “routine” basal cell carcinomas, mainly occurring in older males, localized to the head and neck or any other sun-exposed portion of skin. Histologically, these lesions are different from their conventional counterpart in that the tumor cells are more enlarged and allomorphic, lack peripheral palliating, have abundant eosinophilic cytoplasm, and a loss of retraction artifact [2]. Surrounding fibrous stroma may or may not be present. Some authors consider this variant as an intermediate between nodular cystic BCC and squamous cell carcinoma [3].

To help differentiate between these squamoid appearing basal cell carcinomas and true squamous cell carcinomas, multiple immunohistochemical stains have been applied. In one study, Ber-Ep4 and bcl-2 were applied to formalin-fixed skin tissues to help differentiate BCC from squamous cell carcinoma [4]. Similar to their findings, our specimen showed positive reactivity for Ber-Ep4 and bcl-2, which are two markers found to be positive in basal cell carcinomas and not in squamous carcinomas. Combined with the histological features as described above, the case was diagnosed as a metatypical basal cell carcinoma. Due to the limited number of reported cases, the exact prognostic significance of this variant is unknown.

CORRESPONDENCE TO

Bo Wang, M.D. Department of Pathology Creighton
University Medical Center Omaha, Nebraska 68131 Tel:
402-449-4951 bowang@creighton.edu

References

1. Darier J, Ferrand M. L'epitheliome pavimenteux mixte et intermediaire. Ann
2. James, Patterson W., and Wick R. Wick. Nonmelanocytic Tumors of the Skin. AFIP Atlas of Tumor Pathology. 4th ed. Vol. 4. Washington DC: American Registry of Pathology, 2006. 52-53.
3. Weedon, David. Skin Pathology. 2nd ed. New York: Churchill Livingstone, 2002. 769-770.
4. Swanson, P E., M M. Fitzpatrick, J H. Ritter, E J. Glusac, and M R. Wick. "Immunohistologic Differential Diagnosis of Basal Cell Carcinoma, Squamous Cell Carcinoma, and Trichoepithelioma in Small Cutaneous Biopsy Specimens." Journal of Cutaneous Pathology 25 (1998): 153-159.

Author Information

Eric E. Santos, M.D.

Department of Pathology, Creighton University Medical Center

Deba P. Sarma, M.D.

Department of Pathology, Creighton University Medical Center

Mingkui Chen, M.D., Ph.D.

Department of Pathology, Creighton University Medical Center

Bo Wang, M.D.

Department of Pathology, Creighton University Medical Center