

Thyroid microcarcinoma - a diagnostic dilemma in benign thyroid disease

M Hasan, F Siddiqui, M Al-Ajmi

Citation

M Hasan, F Siddiqui, M Al-Ajmi. *Thyroid microcarcinoma - a diagnostic dilemma in benign thyroid disease*. The Internet Journal of Head and Neck Surgery. 2009 Volume 4 Number 1.

Abstract

Aims and Objectives: To know the prevalence rate of incidental thyroid microcarcinoma in presumably benign thyroid diseases. **Materials and Methods:** The study was conducted on 327 patients in Kuwait over a span of 3 ½ years from December 2003 to June 2007. The patients were thoroughly evaluated by clinical history and examination, thyroid imaging by ultrasonography and laboratory investigations followed by FNAC and histopathology. Special stains were performed wherever required. **Results:** The study showed prevalence rate of incidental thyroid microcarcinoma in presumably benign thyroid diseases to be 2.14%. **Conclusion:** The incidence of incidental thyroid microcarcinoma in presumably benign thyroid diseases is not very low and therefore the possibility of thyroid microcarcinoma should always be kept in mind while diagnosing a benign thyroid disease.

INTRODUCTION

Thyroid microcarcinomas (TMC) are defined by the World Health Organisation (WHO) as thyroid cancer measuring less than 10 mm in its greatest dimension.¹ Incidental diagnosis of TMC on histology of the resected thyroid following surgery for a presumably benign thyroid disease is a common clinical scenario. It frequently remains clinically occult and is usually diagnosed as an incidental finding on histopathological examination, in autopsy or surgical material.² Those presenting with clinical features are often treated by an endocrinologist for many years before undergoing thyroid surgery for a supposedly benign thyroid disease. Papillary thyroid microcarcinoma (PTMC) and medullary thyroid microcarcinomas (MTMC) have been reported. We report the prevalence of PTMC and MTMC, incidentally diagnosed following surgery, for a presumably benign thyroid disease.

MATERIALS AND METHODS

The present study was conducted on 327 patients in Kuwait who presented with neck swelling. The study was conducted over a period of 42 months from December 2003 to June 2007. The evaluation of these patients included a complete clinical examination, thyroid imaging with ultrasonography and laboratory investigation (TSH, thyroxine and triiodothyronine levels, antithyroid

peroxidase/antithyroglobulin antibody levels and serum thyroglobulin level). Serum calcitonin measurement was also carried out in all patients for medullary carcinoma.

To exclude thyroid malignancy, fine-needle aspiration cytology (FNAC) under ultrasonography guidance was done, especially in patients with solitary thyroid nodules or when risk factors for the presence of underlying malignancy were present. Such risk factors included hoarseness of voice, progressive dysphagia, shortness of breath, rapid growth of the thyroid nodule, especially if observed under thyroid hormone suppressive therapy, cervical lymphadenopathy and suspicious findings on preoperative imaging evaluation.

Patients with cytologically diagnosed thyroid malignancy were excluded from this study. Patients diagnosed with benign thyroid diseases like multinodular goiter, solitary nodule, Hashimoto's thyroiditis and diffuse hyperplasia of the thyroid were included in the study. The resected specimens were serially sectioned at 1mm intervals and then processed by histokinete, followed by paraffin embedding. The cut sections were stained with hematoxylin and eosin (H & E) stain and eventually histologically examined for microcarcinoma. Special stains were used wherever required.

RESULTS

Out of the 327 patients included in the study, 7 (2.14%) patients were diagnosed with incidental TMC on histopathological examination, 6 (1.83%) cases were of PTMC and 1 (0.30%) cases were of MTMC. Out of the 7 cases of TMC, 4 (57.14%) patients were males while 3 (42.85%) patients were females. Majority of the patients under this study belonged to the 5th decade of life. Mean age for females was 46 years while for males was 42 years. The minimum age of the patients under study was 29 years while maximum age was 61 years. These patients were treated surgically for presumably benign thyroid disease; multinodular goiter (4 patients), Hashimoto's thyroiditis (2 patients) and diffuse hyperplasia of the thyroid (1 patient).

Some of the TMC were tiny gray-white lesions but most were undetectable on gross examination. Mean diameter was measured by ocular micrometer. Mean diameter of PTMC was 6.6 mm while of MTMC was 4.2 mm. The tumor was multifocal in 3 (42.85%) cases.

On histopathological examination PTMC showed numerous true papillae with a fibrovascular stalk (Fig.1). The tumor cells had pale eosinophilic cytoplasm with the characteristic vesicular to ground glass appearing nuclei, nuclear grooves and nuclear pseudoinclusions (Fig.2). MTMC showed solid proliferation of round to polygonal cells of granular amphophilic cytoplasm and round eccentric nucleus (Fig.3). The tumor cells were positive for calcitonin (Fig.4) and negative for thyroglobulin (Fig.5).

Figure 1

Fig.1: Section showing papillary microcarcinoma comprising of papillaroid structures with fibrovascular stalk (H & E x 125).

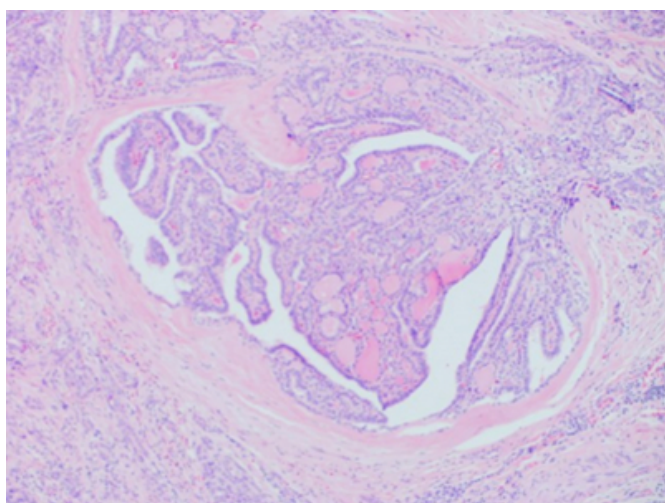


Figure 2

Fig.2: Section showing tumor cells having vesicular to ground glass nuclei with pale eosinophilic cytoplasm and nuclear grooves (H & E x 500)

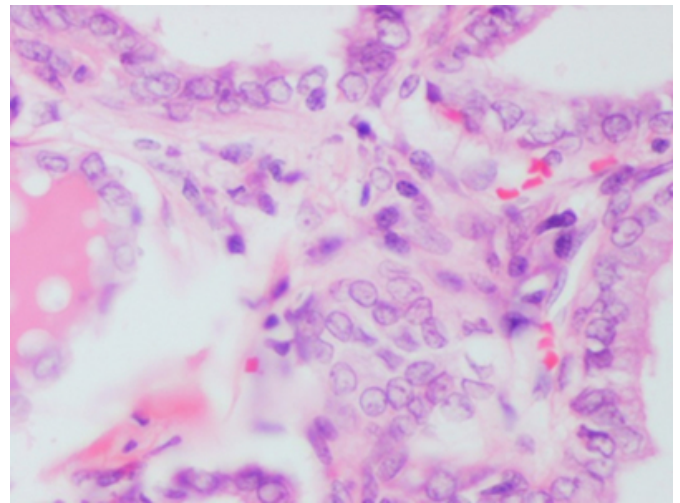


Figure 3

Fig.3: Section showing solid proliferation of round to polygonal cells of granular amphophilic cytoplasm and eccentric nucleus (H & E x 500)

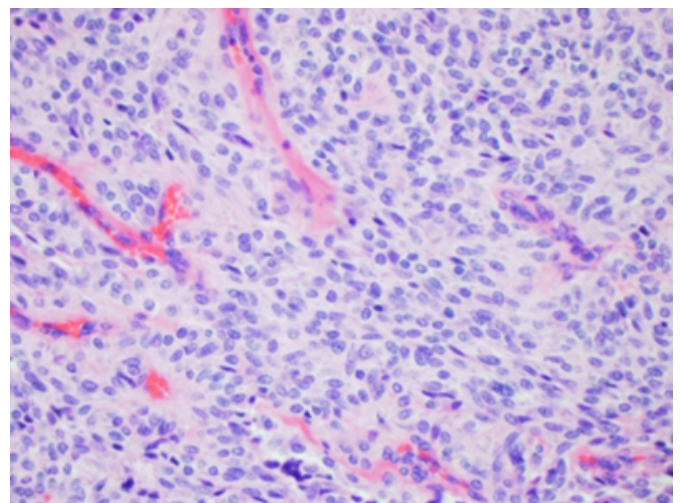


Figure 4

Fig.4: Section showing tumor cells positive for calcitonin (x 50).

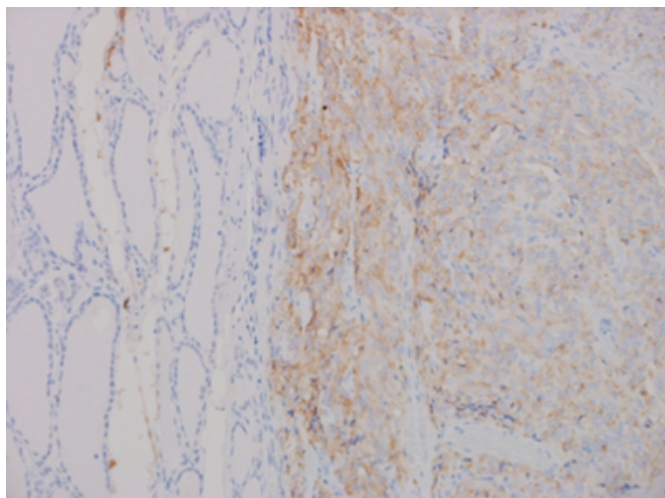
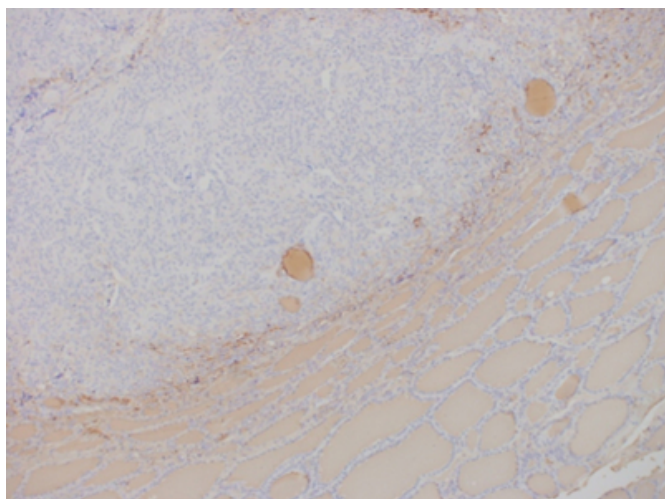


Figure 5

Fig.5: Section showing tumor cells negative for thyroglobulin (x 50)



Total or near-total (leaving no more than 3 g of thyroid tissue) thyroidectomy was the most commonly performed surgical procedure. In 321 patients, total/near-total thyroidectomy was performed and 6 patients underwent lobectomy with or without isthmusectomy. Mortality was zero and there was no significant morbidity, except transient hypocalcemia in four patients. Following surgery, adjuvant radioiodine therapy was given in 3 patients with multifocal PTMC and infiltration of the thyroid capsule.

6 patients were on regular follow-up and are presently disease-free while the remaining 1 patient was lost on follow up.

DISCUSSION

Microcarcinomas of the thyroid are not an uncommon entity. In this study, TMC was diagnosed in 2.14% (7 of 327) of patients with presumably benign thyroid disease. In autopsy studies, the incidence of PTMC has been found to range from 3-36%.^{3,4} In many surgical studies conducted on patients with a presumably benign thyroid diseases, incidental foci of PTMC, ranged from 2-24%.^{5,6} In our study, PTMC was diagnosed in 1.83% (6 of 327) and MTMC was diagnosed in 0.30% (1 of 327) of patients who were treated surgically for presumably benign thyroid disease. In contrast to the clinically evident papillary carcinomas PTMC are more common in males, as was observed in our study.⁵ Multifocality is more commonly seen in PTMC and in many studies has been observed to be present in 20-46% of cases.^{3,6,7} In our study multifocality was seen in 42.85% (3 of 7) cases. In a significant percentage of patients with PTMC, metastases in lymph node may be seen and, in few cases, these metastases may appear before the clinical evidence of the primary tumor.⁸ However, none of our cases, who were on follow-up, showed any evidence of lymph node metastases. The possibility of lymph node metastases in patients who was lost on follow up could not be ruled out.

The incidence of PTMC in autopsy studies varies from 3-36%. Most of them have a relatively benign biological behavior. Studies have suggested that most of the thyroid microcarcinomas behave in a benign fashion, as a significant percentage of patients who died of diseases other than thyroid cancer had PTMC that remained asymptomatic throughout their lives.^{4,9} The prevalence of PTMC and death from cancer do not coincide and this further supports that PTMC is an indolent disease.^{10,11}

The diagnosis of TMC is usually based on a combination of clinical examination, laboratory investigations and radiological techniques. However, as mentioned above, these are often clinically undetectable because of their small size and are usually detected as an incidental finding at autopsy or in specimens of thyroid removed for other reasons. However, in the recent years, more cases of TMC are being diagnosed because of the more frequent use and improvement of ultrasonography and image-guided FNAC. The diagnosis can now often be made preoperatively. On Ultrasonography, irregularity, vascularity and calcification are important features for suspicious nodules.¹² Nowadays, with the help of high resolution transducers, tumors measuring even 1 and 2 mm in diameter can be detected.¹³

Most authors recommend ultrasound-guided FNAC for thyroid nodules larger than 10 mm.¹⁴

Patients with TMC have favorable long term prognosis. Earlier conservative treatment in the form of unilateral lobectomy was advocated for patients with these tumors.¹⁵ However, cases of locoregional recurrence have been reported in 0-11%.¹⁶ Few cases of distant metastases have also been reported and finally deaths related to TMC have been reported in very few cases.^{17, 18} Therefore, many authors consider total/ subtotal thyroidectomy to be the treatment of choice for TMC. On the contrary, many authors agree that thyroid microcarcinoma should not be over treated, especially in cases of unifocal TMC, which have a very low recurrence rate as compared to multifocal TMC. With the help of multivariate analysis, it was found that persistent or recurrent disease was associated with non incidental cancer, lymph node metastasis at presentation and bilateral tumor. Development of distant metastasis was associated more with the sclerosing variant and the presence of lymph node metastasis at presentation.¹⁹

Ito et al are of the opinion that as PTMC is generally associated with good prognosis. Further surgery, such as completion total thyroidectomy or lymph node dissection immediately after the diagnosis of PTMC is not necessary.²⁰ This is in contrast to the study of Chow et al, who showed that in spite of the overall excellent prognosis for patients with PTMC, PTMC was associated with 1.0% disease-related mortality rate, 5.0% lymph node recurrence rate, and 2.5% distant metastasis rate.²¹ Therefore, the treatment of patients with PTMC should be no different from the treatment of patients with conventional papillary thyroid carcinoma: i.e., completion surgery with consideration for radioactive iodine and/or external radiation therapy if poor prognostic factors are present.²¹

CONCLUSION

We conclude that TMC are carcinomas measuring not more than 10 mm in greatest dimension. These usually present asymptotically or in association with benign or malignant thyroid lesions. Many are discovered on autopsy. The study showed the prevalence rate of incidental thyroid microcarcinoma in presumably benign thyroid diseases was 2.14%. Although the prevalence rate of TMC in our study is lower than that seen in other studies, it still carries an important statistics for the implementation of proper investigations and treatment. In recent years, with the use of thyroid ultrasonography and other neck imaging modalities

along with image guided FNAC, nodules too small to be palpated and diagnosed as TMC, have been increasingly reported. These usually behave in a benign fashion and have a favorable long term prognosis. Although, TMC have a good prognosis and long term survival is excellent, recurrences have been reported and fatal outcome is possible especially in multifocal cases. Therefore, the possibility of thyroid microcarcinoma should always be kept in mind while diagnosing a benign thyroid disease.

ABBREVIATIONS

TMC: Thyroid microcarcinoma

PTMC: Papillary thyroid microcarcinoma

MTMC: Medullary thyroid microcarcinoma

References

1. Hedinger C, Williams ED, Sobin LH, (editors). Histological typing of thyroid tumors. In: WHO International Histological Classification of Tumours, Vol 11, 2nd ed. Berlin: Springer; 1988. 9 - 10.
2. Sakorafas GH, Stafyla V, Kolettis T, Tolumis G, Kassaras G, Peros G. Microscopic papillary thyroid cancer as an incidental finding in patients treated surgically for presumably benign thyroid diseases. J Postgrad Med 2007; 53: 23-26.
3. Sakorafas GH, Giotakis J, Stafyla V. Papillary thyroid microcarcinoma: A surgical perspective. Cancer Treat Rev 2005; 31: 423-438.
4. Harach HR, Franssila KO, Wasenius VM. Occult papillary carcinoma of the thyroid; A "normal" finding in Finland. A systemic autopsy study. Cancer 1985; 56: 531-538.
5. McConahey WM, Hay ID, Woolner LB, van Heerden JA, Taylor WF. Papillary thyroid cancer treated at the Mayo Clinic, 1946 through 1970: Initial manifestation, pathologic findings, therapy and outcome. Mayo Clin Proc 1986; 61: 978-996.
6. Fink A, Tomlinson G, Freeman JL, Rosen IB, Asa SL. Occult micropapillary carcinoma associated with benign follicular thyroid disease and unrelated thyroid neoplasms. Mod Pathol 1996; 9: 816-820.
7. Hubert JP Jr, Kiernan PD, Beahrs OH, McConahey WM, Woolner LB. Occult papillary carcinoma of the thyroid. Arch Surg 1980; 115: 394-398.
8. Appetecchia M, Scarcello G, Pucci E, Procaccini A. Outcome after treatment of papillary thyroid microcarcinoma. J Exp Clin Cancer Res 2002; 21: 159-164.
9. Bondeson L and Ljungberg O. Occult thyroid carcinoma at autopsy in Malmo, Sweden. Cancer 1981; 47: 319-323.
10. Sampson RJ, Key CR, Buncher CR, Iijima S. Thyroid carcinoma in Hiroshima and Nagasaki. I. Prevalence of thyroid carcinoma at autopsy. JAMA 1969; 209: 65-70.
11. Sampson RJ, Wootner LB, Bahn RC, Kurland LT. Occult thyroid carcinoma in Olmsted County, Minnesota: Prevalence at autopsy compared with that in Hiroshima and Nagasaki, Japan. Cancer 1974; 34: 2072-2076.
12. Duh QY. Thyroid cancer in Graves disease: Incidental cancer versus clinical cancer. Ann Surg Oncol 2004; 11: 356-357.
13. Senchenkov A, Staren ED. Ultrasound in head and neck

surgery: Thyroid, parathyroid and cervical lymph nodes. Surg Clin North Am 2004; 84: 973-1000.

14. Pearce EN and Braverman LE. Papillary thyroid microcarcinoma outcomes and implications for treatment. J Clin Endocrinol Metab 2004; 89: 3710-3712.

15. Vickery AL, Wang CA, Walker AM. Treatment of intrathyroidal papillary carcinoma of the thyroid. Cancer 1987; 60: 2587-2595.

16. Mazzaferri EL, Jhiang SM. Long term impact of initial surgical and medical therapy on papillary and follicular thyroid cancer. Am J Med 1994; 97: 418-428.

17. Strate SM, Lee EL, Childers JH. Occult papillary carcinoma of the thyroid with distant metastases. Cancer 1984; 54: 1093-1100.

18. Hay ID, Grant CS, van Heerden JA, Goellner JR, Ebersold JR, Bergstralh EJ. Papillary thyroid

microcarcinoma: a study of 535 cases observed in a 50 year period. Surgery 1992; 112: 1139-1147.

19. Pellegriti G, Scollo C, Lumera G, Regalbuto C, Vigneri R, Belfiore A. Clinical Behavior and Outcome of Papillary Thyroid Cancers Smaller than 1.5 cm in Diameter: Study of 299 Cases. J Clin Endocrinol Metab 2004; 89: 3713-3720.

20. Ito Y, Higashiyama T, Takamura Y, Miya A, Kobayashi K, Matsuzuka F, Kuma K, Miyauchi A. Prognosis of patients with benign thyroid diseases accompanied by incidental papillary carcinoma undetectable on preoperative imaging test. World J Surg 2007; 31: 1672-1676.

21. Chow SM, Law SCK, Chan JKC, Au SK, Yau S, Lau WH. Papillary microcarcinoma of the thyroid-Prognostic significance of lymph node metastasis and multifocality. Cancer 2003; 98: 31-40.

Author Information

Mahboob Hasan, MD

Lecturer, Department of Pathology, Jawaharlal Nehru Medical College, Aligarh Muslim University

Farhan Asif Siddiqui, MD

Lecturer, Department of Pathology, Jawaharlal Nehru Medical College, Aligarh Muslim University

Mohammed Al-Ajmi

Consultant and Head, Department of Pathology, Jawaharlal Nehru Medical College, Aligarh Muslim University