

Phrenic Nerve Paralysis After Subclavian Revascularization Surgery: A Case Report

A El-Dawlatly

Citation

A El-Dawlatly. *Phrenic Nerve Paralysis After Subclavian Revascularization Surgery: A Case Report*. The Internet Journal of Anesthesiology. 2003 Volume 8 Number 1.

Abstract

Phrenic nerve paralysis (PNP) has been reported following neck dissection and after instillation of local anesthetics in the interpleural space. We report a case of PNP which to our knowledge is the first case report following subclavian revascularization surgery.

A 50-year-old female patient, ASA class 2 with normal preoperative chest-x-ray and laboratory investigations, was operated for unilateral subclavian to subclavian artery bypass graft under general anesthesia. At the end of surgery atropine and neostigmine were given in the usual dosages guided by a peripheral nerve stimulator. The trachea was extubated and immediately thereafter the patient developed shortness of breath and became cyanotic. The trachea was then reintubated. In the ICU and on the 10th postoperative day a phrenic nerve study with recording the diaphragmatic compound muscle action potential (DCMAPs) revealed unilateral PNP, where delayed conduction was determined for the right phrenic nerve with a mean latency of 9.23msec and decreased amplitude 0.085mv. The patient was sedated and under controlled ventilation. On the 18th postoperative day, the test was repeated and showed shorter latency of 6.63msec (72% recovery) and high amplitude 0.45mv (5 fold improved). The weaning process was started and finally the trachea was extubated and the patient was breathing spontaneously and adequately with satisfactory arterial blood gases. We concluded that phrenic nerve conduction studies could be valuable in the diagnosis and follow up of these patients with PNP for better outcome.

INTRODUCTION

Phrenic nerve paralysis (PNP) has been reported following neck dissection (^{1,2,3}). Temporary PNP has been reported after instillation of local anesthetics in the interpleural space (⁴). Moreover, scattered cases of PNP were also reported following subclavian vein catheterization (^{5,6}) and following coronary artery bypass surgery (⁷). We report a case of transient PNP which to our knowledge is the first case report following subclavian revascularization surgery.

CASE REPORT

A 50-year-old female patient who was admitted to the hospital complaining of claudical pain in the right arm. The pain was cramping in nature and aggravated with rising the arm above the head, during dressing and with combing the hair. Angiography was done and revealed a stenotic right subclavian artery. The patient was scheduled for unilateral subclavian to subclavian artery bypass graft surgery. The patient was diabetic and hypertensive with ischemic heart disease. On the preoperative visit her blood pressure was

150/90 mmHg and heart rate 80/min. Her ECG showed left ventricular hypertrophy and echocardiography revealed normal left ventricular function. She was receiving diltiazem 40mg, glyceryl trinitrate 5mg three times daily and aspirin 100mg once daily. Her blood sugar was 14mmol/l where she was kept on insulin guided by the sliding scale. The other hematological and biochemical investigations were within normal limits. A nerve conduction study of the right arm was done and showed a picture of peripheral neuropathy (motor and sensory) due to diabetes. Chest-x-ray was normal.

The patient was kept fasting overnight and prepared for surgery. She was premedicated with lorazepam 2mg at bed time and 2mg orally two hours before surgery. Upon arrival to the operating theatre the right antecubital vein and radial artery were cannulated under local anaesthesia. Anesthesia was induced with sufentanil 10ug and thiopentone 250mg followed by atracurium 40mg. The trachea was intubated and the lungs were ventilated with a mixture of 60% nitrous oxide in oxygen and isoflurane 0.4-0.8 vol%.

Incremental doses of sufentanil and atracurium were given when required. Intra-arterial blood pressure, heart rate, ECG and urine output were monitored continuously. Tissue oxygen saturation SaO₂ (Pulse Oximetry, Ohmeda 2700) end-tidal carbon dioxide concentration (Capnomac, Datex) and peripheral nerve stimulator (Datex,Finland) were also monitored. The surgical procedure involved bilateral supraclavicular dissection of both subclavian arteries. A tunnel was made between the two arteries crossing anterior to the trachea and a Gortex synthetic graft was anastomosed end to side between both arteries.

The total duration of anaesthesia was 180 min. At the end of surgery atropine and neostigmine were given in the usual doses guided by a peripheral nerve stimulator. When the patient became fully awake and responded to verbal commands the trachea was extubated. Following extubation the patient was not able to maintain spontaneous breathing and desaturated with SaO₂<80%. Immediately thereafter the trachea was reintubated facilitated with i.v suxamethonium. The patient was then transferred to the surgical intensive care unit (ICU) for further assessment. The patient was sedated using midazolam 1-2 mg i.v hourly with controlled ventilation. The next day, another unsuccessful trial of weaning was attempted where paradoxical pattern of breathing was noticed. It was clinically evident that the patient was using the intercostal and abdominal muscles for breathing. Phrenic nerve palsy was thought of. The patient was sedated and controlled ventilation resumed. Chest x-ray revealed a high right cupola of the diaphragm and a right phrenic nerve palsy was suspected. This was further confirmed during fluoroscopic examination by the demonstration of paradoxical motion of the elevated right hemidiaphragm.

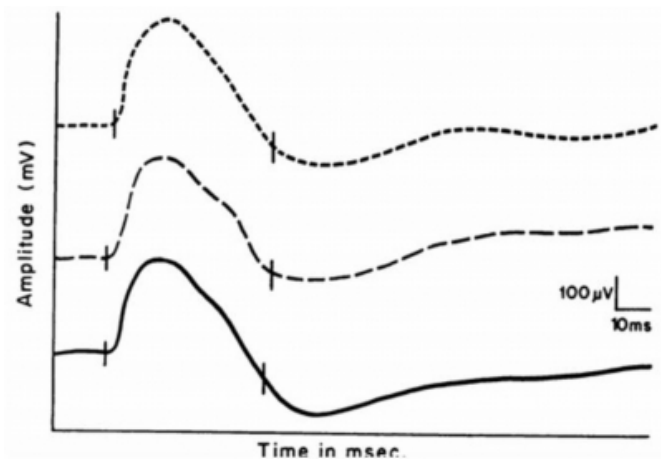
During the first week of her stay in the ICU the patient developed septicemia and the blood culture grew pseudomonas organism. During that period, she was critically ill and she received antibiotics, inotropic support, and total parenteral nutrition. Thereafter the patient's general condition improved which warranted further investigation of the breathing problem. On the 10th postoperative day, a phrenic nerve conduction study was performed where the phrenic nerve was stimulated percutaneously at the posterior border of the sternomastoid muscle in the supraclavicular fossa just above the clavicle using bipolar surface electrodes. A constant current stimulator delivered square-wave pulses of 0.1 ms duration. The diaphragmatic compound muscle action potentials (DCMAPs) was recorded with self-

adhesive surface electrodes applied 5cm superior to the tip of the xiphoid process (_{8,9}).

Measurements of the DCMAPs were made during 3 trials. Latency was determined from the onset of the negative peak and amplitude from the baseline to the negative peak. Delayed conduction was determined where the mean latency was 9.23 millisecond (msec)(control 6.19±0.69 msec) and decreased mean amplitude 0.085 millivolt (mv)(control, mean of peak to peak 1.34±0.28mv) was recorded (Fig1).

Figure 1

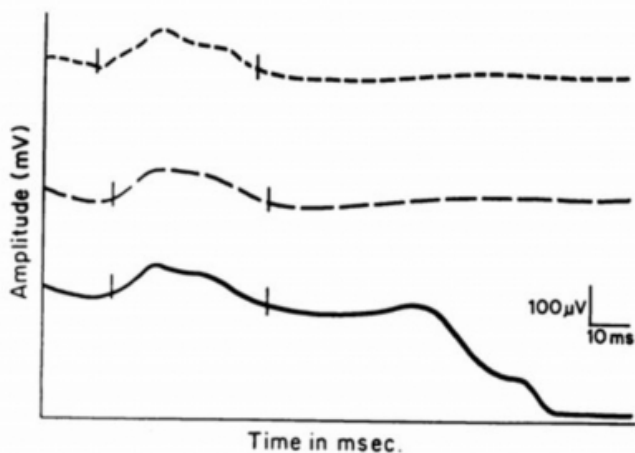
Figure 1: Right phrenic nerve conduction and DCMAPs study. Latency 9.23 msec and amplitude 0.085 mv. The peak to peak amplitude (P-P) is given on the vertical axis (10th postoperative day).



The latency and the peak to peak amplitude for the left DCMAPs were within the suggested normal range (control values) (₉).The patient continued on controlled ventilation with daily assessment for weaning by cessation of midazolam and testing her ability to trigger the ventilator in addition to her response to verbal commands with unsuccessful results. On the 18th postoperative day, the phrenic nerve study was repeated and a shorter latency of 6.63 msec (72% recovery) and larger amplitude of 0.45 mv(5 fold improved) (Fig 2) was found.

Figure 2

Figure 2: Right phrenic nerve conduction and DCMAPs study. Latency 6.63 msec and amplitude 0.45 mv (18th postoperative day).



The top curve: 1st trial The middle curve: 2nd trial The bottom curve: 3rd trial

At this time we gradually started the weaning process. After stabilization of the physiological parameters and cessation of midazolam, ventilation was switched into synchronized intermittent mandatory ventilation (SIMV) where normal breathing pattern was noticed at a rate of 4. Thereafter, a T-piece with FiO₂ of 0.4 was started and eventually the patient made a full recovery with acceptable arterial blood gases. The trachea was extubated. The patient made an uneventful recovery and eventually she was discharged to the surgical floor.

DISCUSSION

Phrenic nerve paralysis after anaesthesia and surgery is difficult to explain. Obviously, the diagnosis is difficult to establish in the immediate postoperative period for many reasons like the residual effects of anaesthesia and inadequate reversal of neuromuscular blocking drugs. Clinically the diagnosis could be achieved by observing the paradoxical pattern of breathing. Typically, pulmonary function tests in bilateral diaphragmatic paralysis are technically difficult and cumbersome. However, when performed they will show reduction in vital capacity, functional residual capacity and total lung capacity by 55-65% of the predicted values due to reduced lung volumes.

Moreover, maximal expiratory and inspiratory flows will be reduced below 50% of the predicted values due to reduced muscle function (10).

In order to achieve proper diagnosis of PNP, direct measurement of the diaphragmatic function is required. Many methods have been suggested as confirmative. Fluoroscopy or real time sonoscopy of the diaphragm with or without diaphragmatic stimulation was reported conclusive for diagnosis of PNP (11). In the present case, we used a technique of phrenic nerve conduction study with diaphragmatic compound muscle action potentials (DCMAPs) recording which has been used successfully in diagnosing PNP (8). Moreover, that method was also useful in the follow up of the present case with uneventful recovery. In the present case, we believe that the etiology of PNP was due to neurapraxis, indirect trauma, and edema of the phrenic nerve secondary to the manipulations and not due to complete transection of the phrenic nerve as indicated by the 5 fold recovery of the DCMAPs amplitude and the 72% improvement of its latency.

CONCLUSION

In conclusion, PNP following subclavian revascularization surgery is rare. Phrenic nerve conduction study by applying DCMAPs has helped in the management of this case. We think that in PNP the use of phrenic nerve conduction studies could help in the diagnosis and follow up of these patients and result in a better outcome.

CORRESPONDENCE TO

Abdelazeem Ali El-Dawlatly Associate Professor
Department of Anesthesia College of Medicine King Saud University P.O.Box 2925 Riyadh 11461 Tel: +966 1 4682238 Fax: +966 1 4684075 e-mail: dawlatly@ksu.edu.sa

References

1. de Jong A.A and Manni J.J. Phrenic paralysis following neck resection(1991). *Eur Arch Otorhinol* 248: 132-4.
2. Goffart Y, Moreau P, Biquet J.F and Melon J(1988). Phrenic nerve paralysis complicating cervicofacial surgery. *Acta Otorhinolaryngol Belg* 42(4): 564-70.
3. Martin E.P, Ignacio G.J.M, Penas H.J.M, Martinez C.R and Juretschke M.M.A(1989) . 2 cases of bilateral diaphragmatic paralysis. *Rev Clin Esp* 184(2):80-3.
4. Launder GR. Interpleural analgesia and phrenic nerve paralysis(1993). *Anaesthesia* 48(4):315-6.
5. Eerola R, Kaukinen L and Kaukinen S(1985). Analysis of 13 800 subclavian catheterization. *Acta Anaesthesiol Scand* 29(2):193-7.
6. Akata T, Noda Y, Nagata T, Noda E and Kanadabashi T(1997). Hemidiaphragmatic paralysis following subclavian vein catheterization. *Acta Anaesthesiol Scand* 41(9):1223-5.
7. Hino H, Asano K, Akasaka N, Yamanka I and Aoki T(1999). Right phrenic nerve palsy in a patient with ventricular septal perforation after acute myocardial infarction. *Masui* 48(12):1337-9.
8. Chen R, Collins S, Retulla H, Parker A and Bolton

C.F(1995). Phrenic nerve conduction study in normal subjects. Muscle&Nerve 18:330-335.

9. M.M.Kabiraj(1999).The diaphragmatic compound muscle action potentials(DCMAPs)at different lung volumes-A prospective electrophysiological study of the respiratory system. Middle East J of Anesthesiology 15(3): 259-271.

10. Burgess R.W, Boyd A.F , Moore P.G and Oldfield G.S(1989). Postoperative respiratory failure due to bilateral phrenic nerve palsy. Postgraduate Medical Journal 65: 39-41.

11. McCauley R.G and Labib K.B(1984). Diaphragmatic paralysis evaluated by phrenic nerve stimulation during fluoroscopy or real-time ultrasound.Radiology153(1):33-6.

Author Information

Abdelazeem Ali El-Dawlatly

Department of Anesthesia, College of Medicine, King Saud University