

Penile Metastases In The Presence Of Normal Psa Levels And Negative Bone Scan: A Case Report

N Ragavan, P Irwin

Citation

N Ragavan, P Irwin. *Penile Metastases In The Presence Of Normal Psa Levels And Negative Bone Scan: A Case Report*. The Internet Journal of Urology. 2004 Volume 3 Number 1.

Abstract

Advanced carcinoma of prostate is usually associated with high PSA levels and bony metastases and there are case reports of cavernosal thrombosis in such patients. Here, we report a case of advanced carcinoma of prostate with diffuse pelvic and pulmonary metastasis and cavernosal thrombosis, however with normal PSA and negative bone scan.

CASE REPORT

A 65 year old man presented with significant lower urinary tract symptoms, a PSA of 506ng/ml and a T3 prostate tumour on DRE. Following TURP (which confirmed Gleason grade 4+5 adenocarcinoma of prostate) and bilateral orchiectomy, his PSA fell to 1.6 (at 6 months). He remained well and asymptomatic following surgery with PSA levels no higher than 1.8.

Sixteen months after surgery, he presented with a constant perineal pain and was found to have an indurated penis with nodules on the corona of the glans.

MR scanning showed extensive pelvic secondary deposits, a large solid mass arising from prostate and cavernosal thrombosis. There were also widespread lung metastases on his chest x ray. Biopsy of one of the penile nodules revealed poorly differentiated adenocarcinoma of prostatic origin. His isotope bone scan was negative (it was not a superscan). He was commenced on dexamethasone, analgesia and mitazantrone, but he died a month after his admission, approximately 18 months following his original diagnosis

Figure 1

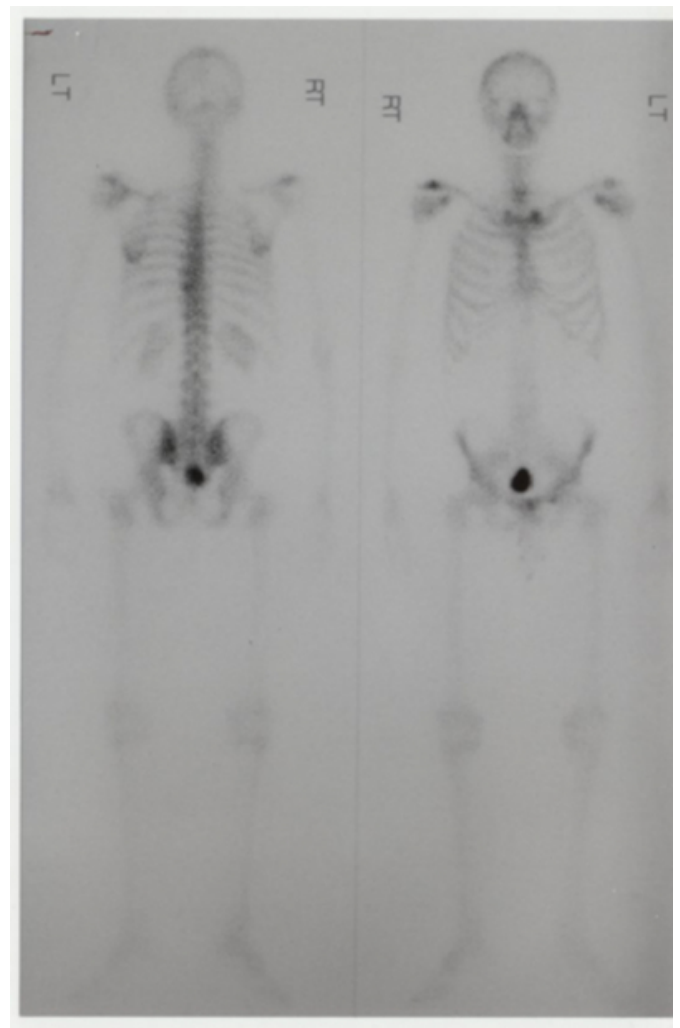
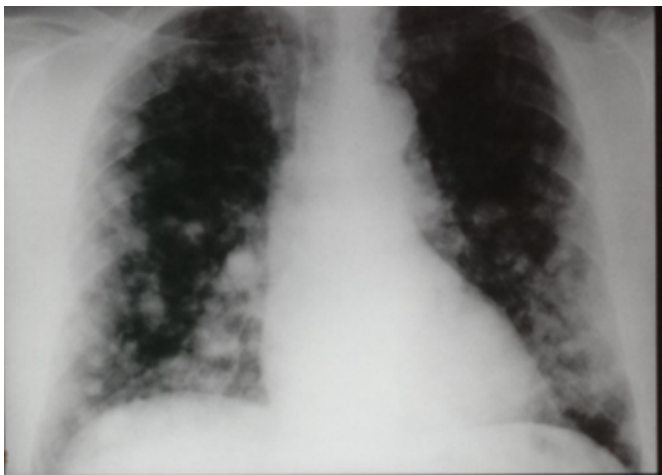


Figure 2

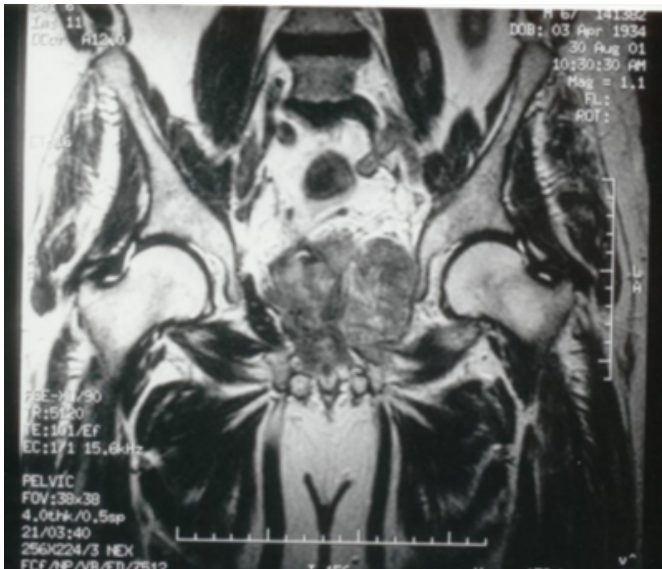

Figure 3



DISCUSSION

Approximately 200 cases of penile metastasis have been documented in the world literature (1), 25% of which arise from primary prostatic cancer (2). Penile metastases occur in approximately 20% of cases of metastatic prostatic cancer (3). Possible mechanisms of tumor metastases include direct spread, retrograde venous spread, retrograde lymphatic spread, direct spread via arteries, spread by means of implantation and by employment of instruments. Penile metastases are usually a presentation of disseminated cancer

(4). In our patient systemic metastases (lung and penile) were found in the absence of skeletal secondaries.

Return of PSA levels to 4 ng/ml or reduction of > 90% of the pre-treatment levels after appropriate treatment is generally associated with improved survival rates (5,6). In our patient, despite a demonstrated fall in PSA after orchiectomy, survival was only 18 months.

Anecdotal reports suggest invariably high PSA levels associated with penile metastases (4,7). In a review of penile metastases 4 out of 20 patients had isolated metastases to penis (3). Normal PSA in the presence of metastatic disease may possibly be explained by diminished tumour antigen expression by the poorly differentiated carcinoma and modulation due to prior androgen therapy (6,8).

CORRESPONDENCE TO

Mr N Ragavan 30 B Stafford road, Eccles, Manchester. UK
M30 9ED Ph 0044 161 6616489 Fax 0044 1772 522946 E
Mail: n.ragavan@lancaster.ac.uk

References

1. Osther PJ, Lontoft E. Metastasis to the penis. Case reports and review of the literature. *Int Urol Nephrol* 1991;23(2):161-167
2. Kotake Y, Gohji K, Suzuki T, et al. Metastases to the penis from carcinoma of the prostate. *Int J Urol* 2001 Feb;8(2):83-86
3. Chan PT, Begin LR, Arnold D, Jacobson SA, Corcos J, Brock GB. Priapism secondary to penile metastasis: a report of two cases and a review of the literature. *J Surg Oncol* 1998 May;68(1):51-59
4. Paquin AJ, Roland SL. Secondary carcinoma to penis. *Cancer* 1956;9:626.
5. Matzkin H, Perito PE, Soloway MS. Prognostic factors in metastatic prostatic cancer. *Cancer* 1993;15.72(12) suppl 3788-3792.
6. Ruckle HC, Klee GG, Osterlinge JE. Prostate specific antigen .concepts of staging prostate cancer and monitoring therapy. *Mayo Clin Proc.* 1994. :69(1). 69-79
7. Sciarra A, D'Eramo G, Casale P, Di Nicola S, Di Chiro C, De Santis C, Loreto A, Di Silverio F. Penile metastasis from carcinoma of the prostate in a patient with high serum prostate specific antigen levels. *Minerva Urol Nefrol* 1999 Sep;51(3):157-158
8. Beardo P Fernandez Pc, Corral JM, Filelle X, Alcover J. Undetectable prostate specific antigen in disseminated prostate cancer. *J Urol* 2001;166:993

Author Information

N. Ragavan, MS FRCS(Ed)

Research Fellow Urology, Michael Heal Department of Urology, Leighton Hospital

P. Irwin, MCh FRCSI (Urol)

Consultant Urologist, Michael Heal Department of Urology, Leighton Hospital