

Osteopetrorickets- Osteopetrosis with rickets, a rare paradoxical association

K Umesh, J Rajesh

Citation

K Umesh, J Rajesh. *Osteopetrorickets- Osteopetrosis with rickets, a rare paradoxical association*. The Internet Journal of Pediatrics and Neonatology. 2008 Volume 10 Number 1.

Abstract

Osteopetrosis is an extremely rare inherited bone disorder, in which defective bone resorption by osteoclasts leads to excessive bone deposition. Though, there is usually calcium excess in osteopetrosis, rickets has been described rarely as a paradoxical complication of infantile osteopetrosis and it results from the inability of the osteoclasts to maintain a normal calcium-phosphorus balance in the extracellular fluid. It is rare paradoxical association. We report two cases of infantile osteopetrosis complicated by rickets and subsequent management issues.

CASE REPORT

Two children, the first case, a four month old and the other, a seven month old presented to us with severe pallor and abdominal distention. Both were born out of consanguineous union and were exclusively breastfed. On examination, they had features of florid rickets such as frontal bossing, malar prominence, depressed nasal bridge, wide-open anterior fontanels, widening of wrists and prominence of the costochondral junction. Abdomen was distended with organo-megaly (both liver and spleen were palpable more than 6 cm below costal margin). Rest of the systemic examination was normal.

Figure 1

Table 1: Blood Investigations

	Hb gm%	Platelets lac/mm ³	Calcium mg/dL	Phosphorus mg/dL	Alk.Phos U/L
Case 1	4.3	70000	4.6	3.5	1350
Case 2	3.8	45000	5.7	4.0	1706

On investigations, both had anemia with Hemoglobin less than 5 gm% and thrombocytopenia. Radiological skeletal survey revealed diffuse bony sclerosis and bone in bone appearance in long bones (Fig. 1). There was notching of the anterior thoracic lumbar spine, thickening and sclerosis of the bones at the base of the skull along with hypoplasia of the mandible (Fig. 2, 3). X-rays of wrist joint revealed metaphyseal fraying and cupping. X rays thus confirmed the diagnosis of osteopetrosis with rickets.

Figure 2

Figure 1(case 1) -- diffuse bony sclerosis and bone in bone appearance of long bones with features of rickets

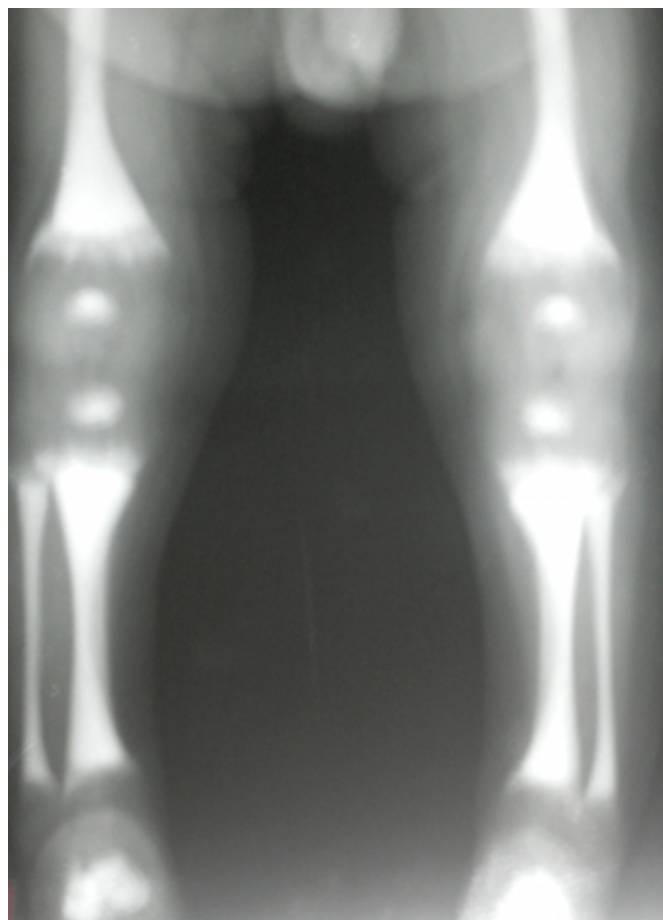


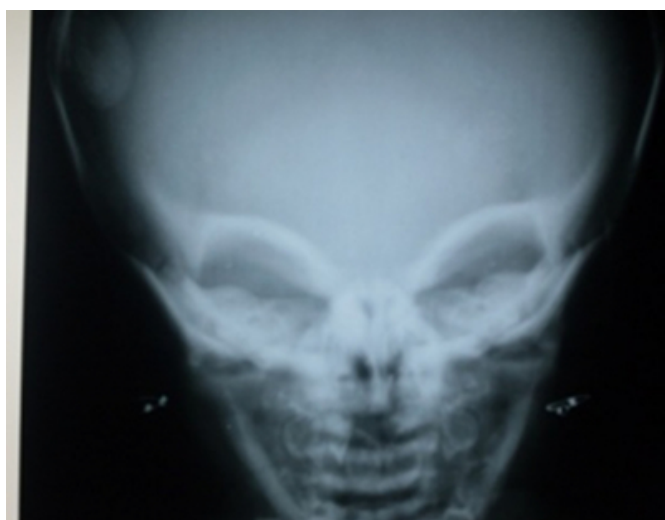
Figure 3

Figure 2(case 2)-notching of the anterior thoracic and lumbar spine with sclerosis.

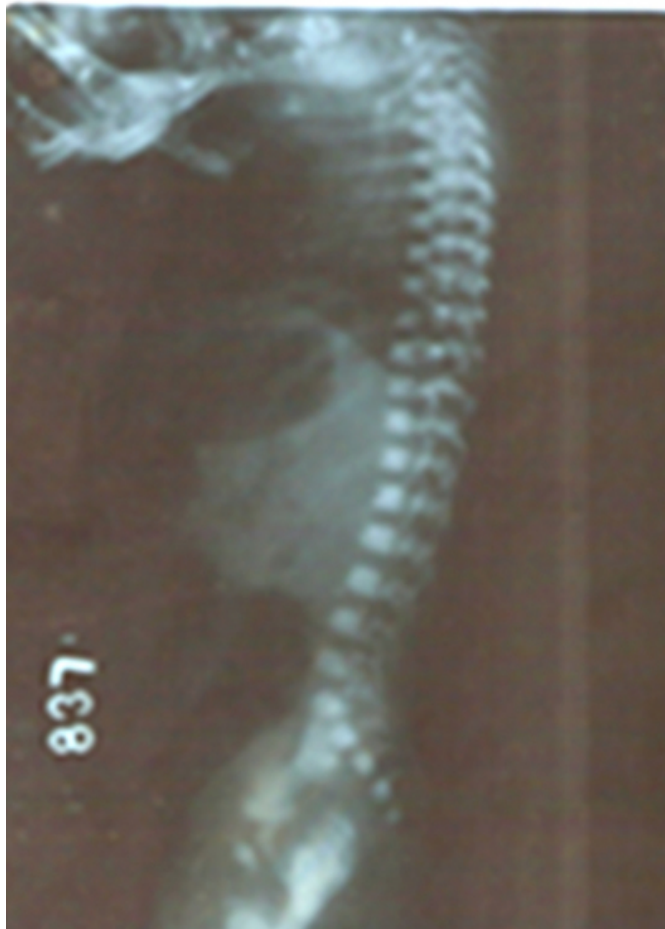

Figure 4

Figure 3(case 2) -sclerosis of bones at the base of skull



Biochemical investigations as in above table showed hypocalcaemia, hypophosphatemia and high serum alkaline

phosphatase. The serum calcium x phosphorus products were below thirty. Renal functions and electrolytes were within normal limits. Acid phosphatase levels were high. The serum 25 hydroxy vitamin D levels were low in both infants confirming rickets. So based on the above radiological and biochemical reports, a diagnosis of osteopetrosis with super-imposed rickets was made

DISCUSSION

A German radiologist, Albers-Schonberg, first described osteopetrosis in 1904^[1]. It is an extremely rare disease with no sex predominance. Overall incidence of the disease is estimated to be one case in 100,000-500,000 population ^[2]. It is a clinical syndrome characterized by the failure of osteoclasts to resorb bone leading to impairment of both, bone modeling and remodeling. The defect in bone turnover characteristically results in skeletal fragility despite increased bone mass. It may cause hematopoietic insufficiency, disturbed tooth eruption, nerve entrapment syndromes and growth impairment ^[2].

Rickets is paradoxical feature of infantile malignant osteopetrosis and called as osteopetrorickets, which is a very rare association ^[3]. It is postulated that, despite markedly positive total body calcium, the serum calcium and phosphorus product is insufficient to mineralize the newly formed chondroid and osteoid may cause paradoxically rickets in cases of osteopetrosis^[3]. The dysfunctional osteoclasts are unable to maintain a normal calcium phosphorus balance in extracellular fluid despite a positive total body calcium balance. More than 99% of total body calcium is sequestered by the skeleton leading to a paradoxical decrease in the serum calcium and this decrease is often exacerbated by inadequate dietary intake of calcium ^[45]. The excessive accumulation of osseous tissue increases bone density, which constricts the marrow and neural foramen, and thus, making the patient susceptible to anemia, leucopenia, thrombocytopenia, extramedullary hematopoiesis and multiple cranial nerve palsies.

In these children, during the radiological survey for rickets findings of osteopetrosis were co-incidentally noticed, which were later on confirmed on detailed skeletal survey. The association of rickets in patients with osteopetrosis should be clearly identified at the onset for two reasons: (a) treatment of rickets leads to improvement in activity, decreases irritability, improves appetite and protects from recurrent respiratory tract infections^[45]; and (b) If facilities of bone marrow transplantation (BMT) are available, then for best

results treatment of rickets is essential[4]. Rickets with osteopetrosis is treated with Vitamin D₃ and high dose calcium and it improves the general well being of the child [4].

Bone marrow transplantation is the only effective treatment for osteopetrosis; it provides hematopoietic stimulus that can differentiate into normal osteoclasts[5]. Prognosis is uniformly poor in absence of bone marrow trans-plantation; most of the children succumb to the disease by mild childhood due to anemia, bleeding and infections. Current opinion regarding the clinical treatment of patients with osteopetrorickets involves first, the resolution of the rickets, followed by bone marrow transplantation to resolve the osteopetrosis. Though, there are case reports of successful bone marrow transplantation in osteopetrosis [5], at present no case of osteopetrorickets successfully treated with bone marrow transplantation has been described in literature.

CORRESPONDENCE TO

Dr Kalane Umesh Dinkar Flat no.16, Hamy Plaza-A Katraz-S.N.87 Pune-46.Maharashtra umeshkalane@yahoo.com
mobile no.9869571694.

References

1. Albers-Schonberg H (1904) Roentgen bilder einer seltenen Kochennerkrankung Munch Med Wochenschr 51:365 (cross reference)
2. Beighton P, Hamersma H, Cremin BJ .Osteopetrosis in South Africa. The benign lethal and intermediate forms.S Afr Med J 1979;55(17):659-65.
3. Kulakarni ML,Matadh PS.Rickets in osteopetrosis –A Paradoxical Association.Indian Pediatrics 2003; 40:561-565.
4. Kaplan FS, August CS, Fallon MD et al. Osteopetrorickets: The paradox of plenty. Pathophysiology and treatment. Clin Orthop 1993;294: 64- 78.
5. Fasth A, Porras O. Human malignant osteopetrosis: pathophysiology, management and the role of bone marrow transplantation. Pediatr Transplant 1999; 3 Suppl 1:102-7.

Author Information

Kalane Umesh, DCH, DNB

Pediatric Neurology fellow, BJWH for Children

Joshi Rajesh, M.D.

Associate professor & Head of Unit, BJWH for Children