
Transepiphyseal Elbow Injuries: An Approach To Diagnosis And Literature Review

A Karigiri, A Manoj-Thomas, D Thomas

Citation

A Karigiri, A Manoj-Thomas, D Thomas. *Transepiphyseal Elbow Injuries: An Approach To Diagnosis And Literature Review*. The Internet Journal of Orthopedic Surgery. 2007 Volume 8 Number 1.

Abstract

An eight year old boy was admitted following direct trauma to the elbow sustained following a fall. The elbow was oedematous, deformed and tender with decreased range of movement. The initial impression, clinically and on X-rays was that of elbow dislocation. Intraoperatively, he was found to have a transepiphyseal injury which was treated with K-wiring. Radiological appearances can be deceptive in the diagnosis of transepiphyseal injuries. We looked at previous literature on similar cases and aim to define the features suggestive of a transepiphyseal injury. We further suggest pre-operative and intra-operative methods to differentiate common elbow pathologies which present similarly.

INTRODUCTION

Fractures around the elbow in children are often difficult to diagnose. Transepiphyseal elbow injuries are rare injuries and can be easily misinterpreted on radiographs. Various traumatic pathologies around the elbow present similarly and encompass a wide spectrum including the pulled elbow to

difficult Transepiphyseal dislocations. We present the case of an eight year-old boy, who sustained an epiphyseal injury to the left elbow following a fall and look at the ways to diagnose this injury with the aid of Schematic diagrams to illustrate the anatomical relationships in a normal elbow (Fig 1).

Figure 1

Figure 1: Normal elbow



CASE REPORT

An eight year old boy fell onto his left elbow and presented

in casualty with a painful deformed elbow without any distal neuro-vascular deficits. Radiographs on admission were interpreted and reported as a dislocation of the elbow (fig 2a & b).

Figure 2

Figure 2a: Lateral pre-op

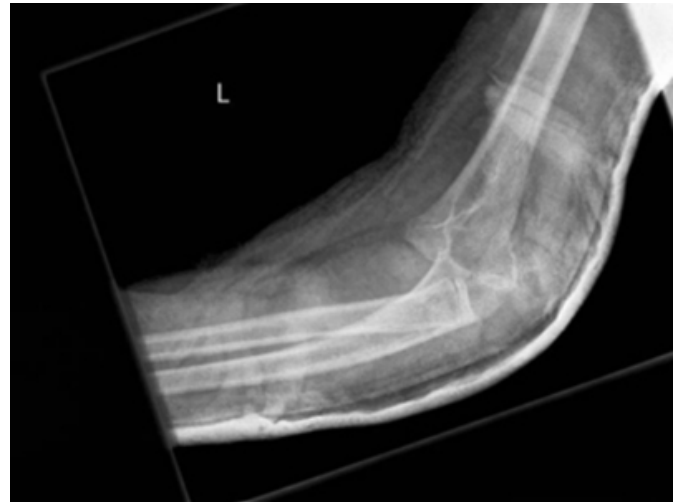
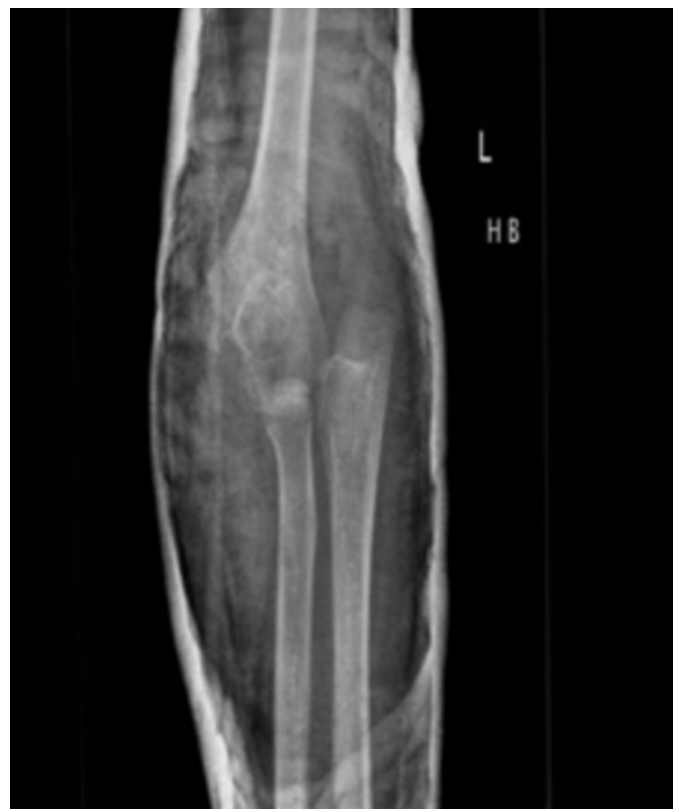
Figure 3

Figure 2b: AP pre-op



Intraoperative radiographic screening revealed a transepiphyseal fracture without a dislocation of the elbow,

as shown in the schematic diagram (fig 2c).

Figure 4

Figure 2c: Schematic diagram



The fracture was treated by open reduction and internal fixation with Kirschner wires (figs 3a & b). The fracture united and the wires were removed at six weeks.

Figure 5

Figure 3a: AP after fixation

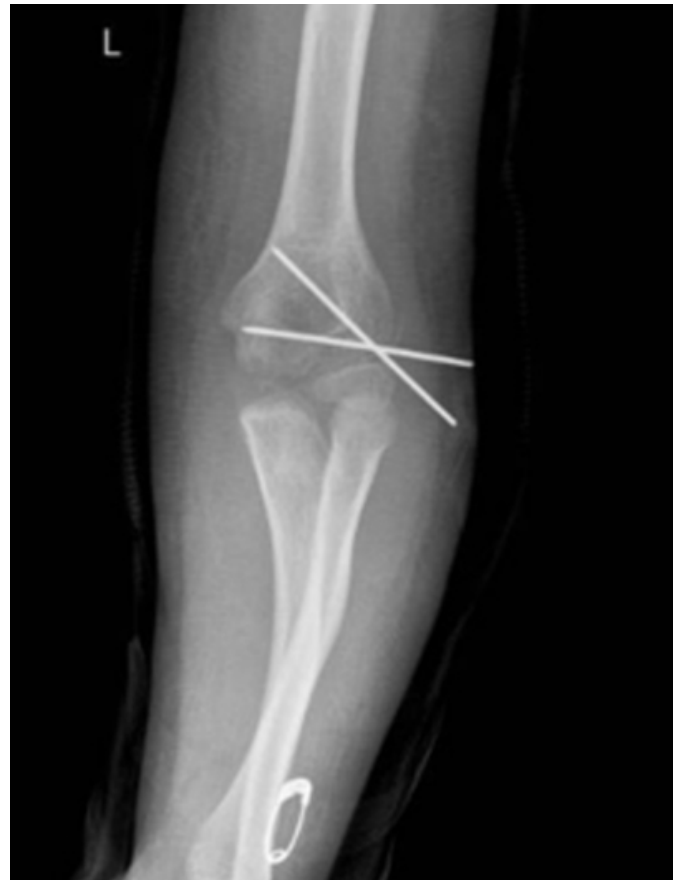

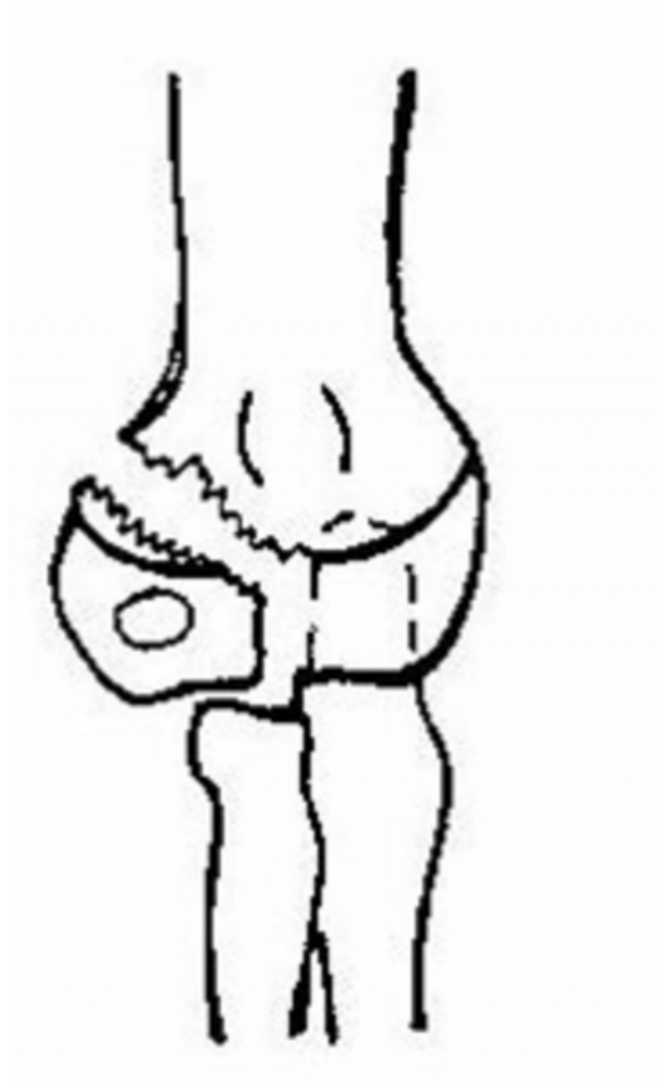
Figure 6

Figure 3b: Lat post fixation

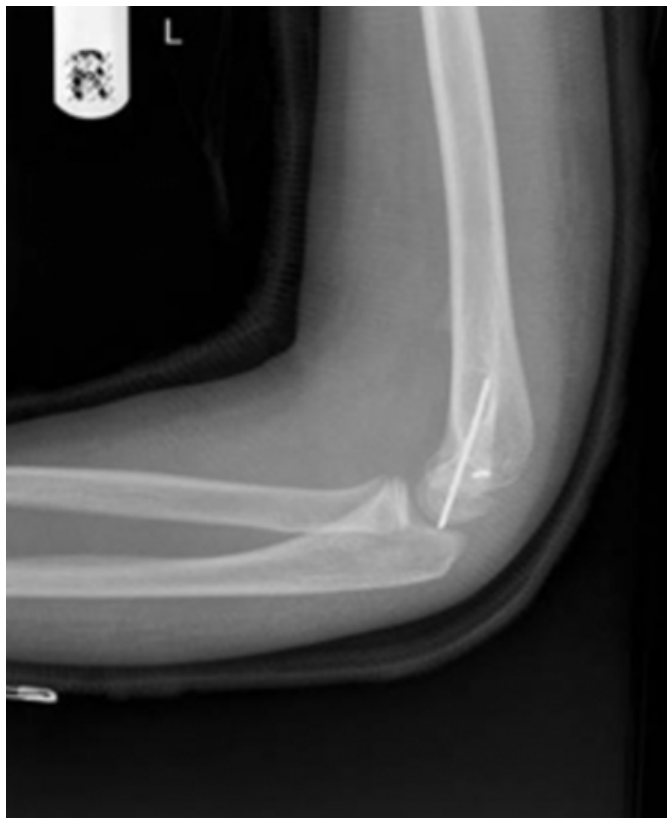

Figure 7

Figure 4: Lateral condyle fracture



DISCUSSION

In 1850 RW Smith first described this injury and differentiated it from supracondylar fracture and elbow dislocation. Clinical examination is often not possible due to the pain and the swelling associated with the injury. On a plain radiograph it is important to distinguish transepiphyseal injury from lateral condyle fracture (fig 4) and dislocation of the elbow.

The difficulty lies in being unable to visualize the cartilaginous distal humeral epiphysis on plain radiograph. Mizuno et al₂ used the relationship of the capitellum to the axis of the head of the radius and to the humerus. In transepiphyseal injury the capitellum maintains its relationship to the head of the radius but not with the humerus, whereas in the fracture of the lateral condyle the axes of the humerus to the forearm is maintained and the relationship of the condylar fragment to the radial head may be altered depending on the displacement of the fracture. In elbow dislocation the relationship of the capitellum to the radius is changed while its relationship to the humerus is maintained. Another difference seen is that the displacement in transepiphyseal injury is commonly postero-medial₁ whereas it is most often postero-lateral in dislocation of the elbow. The diagnosis can further be confirmed with an

arthrogram intraoperatively₂. The principle in the management of such fractures lies in early reduction (closed₁ or open₂) and internal fixation.

CONCLUSION

As in our case transepiphyseal injuries are often misinterpreted on plain radiographs. A mental impression of the distal humerus including its cartilaginous portion and knowledge of the anatomical relationship of the various ossific nuclei is helpful in the diagnosis of the injury.

References

1. Fracture-separation of the distal humeral epiphysis
JC De Lee, KE Wilkins, LF Rogers and CA Rockwood; J. Bone Joint Surg. Am; 62:46-51, 1980.
2. Fracture-separation of the distal humeral epiphysis in young children
K Mizuno, K Hirohata & D Kashiwagi; J. Bone Joint Surg. Am; 61:570-573, 1979.
3. Traumatic separation of the Epiphyses
John Poland; London, Smith 1898.

Author Information

Ajay T. Karigiri

Senior House Officer, Department of Trauma & Orthopaedics, University Hospital of Wales

A. Manoj-Thomas

Specialist Registrar, Department of Trauma & Orthopaedics, University Hospital of Wales

D. Philip Thomas

Consultant, Department of Trauma & Orthopaedics, University Hospital of Wales