

Combination Irinotecan, Capecitabine And Celecoxib In Patients With Advanced Biliary Cancers

F Lee, G Parasher, M Roach, C Hunt, G Heywood

Citation

F Lee, G Parasher, M Roach, C Hunt, G Heywood. *Combination Irinotecan, Capecitabine And Celecoxib In Patients With Advanced Biliary Cancers*. The Internet Journal of Oncology. 2006 Volume 4 Number 2.

Abstract

Background: Patients with metastatic biliary cancers continue to face a very grim prognosis with no effective chemotherapy. Median survival is around 6-9 months. Irinotecan and capecitabine have modest activity against cholangiocarcinoma.

Cyclooxygenase-2 (COX-2) enzyme over expression is reported in many human cholangiocarcinoma cell line studies and is linked to tumor cell resistance to chemotherapy-induced apoptosis. We hypothesized that adding a COX-2 inhibitor would improve the therapeutic benefits in patients with biliary tumors.

Method: From 9/2003 to 2/2005, a total of 12 patients were treated with a combination regimen, delivered at a cycle interval of 21 days, that consisted of 120 mg/m² irinotecan given intravenously over 60 minutes on day 1, 1500 mg/m²/day capecitabine taken orally in divided doses on days 1 – 14 and 400 mg/day celecoxib taken orally in divided doses on days 1-21.

Results: A total of 117 treatments were administered to the 12 patients (9 females and 3 males; median age, 56 years; 10 cholangiocarcinoma and 2 gallbladder cancer). Based on the tumor marker CA19-9, 7 of the patients had a partial response (7/12, 58%). Of the seven patients for which sequential CT evaluation was available, the partial response rate was 43% (3/7) and two additional patients had stable disease. The median progression-free survival was 13 months and the median overall survival was 17 months. We encountered grade II neutropenia and anemia (2/12 each, 17%) and grade I diarrhea and hand-foot syndrome (33% and 7% respectively).

Conclusions: These data suggest that the combination of irinotecan, capecitabine and celecoxib is an effective palliative regimen for patients with metastatic biliary cancers. Further development of this regimen is hindered by the potential cardiovascular risk associated with long-term use of COX-2 inhibitor.

INTRODUCTION

The incidence of cholangiocarcinoma is estimated to be 2,000-3,000 cases per year in the United States. Significant progress has been made at the cellular and molecular level of carcinogenesis of this disease but an effective chemotherapy treatment remains elusive. ¹ Complete resection with negative margins remains the single most important prognostic factor for long-term survival. ² For patients with no chance of surgical cure, the choices of chemotherapy are very limited. Historically, fluorouracil (5-FU) is the foundation of combination chemotherapy regimens for unresectable and metastatic cholangiocarcinoma. The response rate of fluorouracil as a single agent is about 10%. ³ In combination regimens, Taieb et al. reported the use of two days of 5-FU combined with cisplatin on day 2 and showed an objective response rate of 34% and weight gain in 45% of the participants. ⁴ However, the median progression-free survival of 6.5 months and the median overall survival of 9.5

months do not represent a substantial improvement. An ECF (epirubicin, cisplatin, 5-FU) regimen showed only a 10% partial response rate among patients with cholangiocarcinoma. ⁵

Capecitabine is an oral pro-drug of 5-FU. Conversion to the active drug is dependent on thymidine phosphorylase, which is expressed at a higher level in tumor cells than in normal tissue. Results from a randomized trial indicate that single agent capecitabine is at least as effective as 5-FU in metastatic colorectal cancer. ⁶ As a single agent, capecitabine has modest activity in hepatobiliary tumors. ⁷ Knox et al. reported a median overall survival of 14 months using a combination of Gemcitabine and capecitabine in patients with biliary cancers. This indicates that oral capecitabine could replace infusional 5-FU for the treatment of biliary cancers. ⁸

Several clinical trials have shown that irinotecan has activity

against biliary cancers. Of the five patients that had a partial response in a phase I trial testing the combination of irinotecan and docetaxel in advanced solid tumors, one had cholangiocarcinoma.⁹ Two of 11 patients who had a partial response in another phase I trial using a combination of irinotecan, oxaliplatin and 5-FU in advanced tumors had cholangiocarcinoma.¹⁰ A case report indicated that single agent irinotecan given at a low weekly dose could produce a long-lasting response in metastatic cholangiocarcinoma.¹¹

COX-2 enzyme is constitutively expressed in normal hepatocytes but not in normal bile duct epithelium.¹² Studies performed in cell lines indicate that bile acids will induce COX-2 expression in cholangiocarcinoma cells. Therefore, COX-2 over-expression is a potentially important factor in promoting continued proliferation and progression of the tumor.¹³ The mechanisms by which COX-2 over-expression modulates other growth regulating factors in cholangiocarcinoma cells are not fully understood,¹⁴ but COX-2 over-expression in cholangiocarcinoma inhibits Fas-mediated apoptosis.¹⁵ Celecoxib has also been shown to induce apoptosis and inhibit cell proliferation in the human cholangiocarcinoma cell line QBC939.¹⁶ In two other cholangiocarcinoma cell lines, C611B ChC and LY294002, Celecoxib blocks phosphorylation of Akt and significantly reduces viability of the cells.¹⁷

We began offering patients with metastatic biliary cancers off-label treatment with a combination of irinotecan, capecitabine, and celecoxib. We report here our observations about this combination.

MATERIAL AND METHODS

PATIENT POPULATION

All patients had histologic confirmation of biliary cancer and all had performance status of 2 or less. Risks and benefits of chemotherapy were discussed in a standard manner with each patient before initiation of treatment. Institutional Board Review permission was received to perform a retrospective chart review of the patients treated with the reported regimen. Therefore there were no specific eligibility criteria. Demographics, pain scale and performance status, treatment doses and interval, response to therapy, and survival data were collected from the charts. Toxicity was scored using the National Cancer Institute Common Toxicity Criteria, Version 2.0.

TREATMENT PLAN AND TOXICITY

EVALUATION

Standard pretreatment evaluation always included a complete medical history with Eastern Cooperative Oncology Group (ECOG) performance status and physical examination. All patients had surgically proven locally advanced or metastatic biliary tumors. Baseline studies included complete blood count with differential, serum chemistry including creatinine and liver function tests (alkaline phosphatase, aspartate aminotransferase, alanine aminotransferase, bilirubin level). Tumor markers of CEA and CA19-9 were measured at baseline and before each treatment. A CAT scan was performed before chemotherapy initiation and repeated to assess patient response, as clinically indicated. Irinotecan was administered at 120 mg/m² intravenously over 60 minutes on day 1. Capecitabine was taken orally at 1500 mg/m²/day in divided doses on days 1-14 followed by a 7-day break. Celecoxib was taken continuously at a fixed dose of 200 mg orally twice a day without a break. The treatment was repeated every 21 days. Dose escalation of irinotecan of 20-mg/m² increments was done at the time of disease progression on a few patients. Growth factors were not used prophylactically. The leukocyte counts had to be > 1,000 cells/ μ L before starting the next cycle of treatment. Liberal use of anti-diarrheal agents was discussed with each patient and a prescription was given before initiating treatment.

RESPONSE CRITERIA

Tumor response evaluations were performed by physical examination, tumor markers (every cycle) and/or computerized tomography scan (CT scan) (every 9 weeks or every three cycles). A complete response (CR) was defined as the complete disappearance of all radiographic evidence of tumors and normalization of all tumor markers for a minimum of 6 weeks. A partial response (PR) was defined by a $\geq 20\%$ reduction of the sum of the longest diameters of representative tumors lasting at least 6 weeks, or by a reduction of CA19-9 by more than 50% lasting for more than 6 weeks. Progression was defined as an increase > 25% in tumor size, the appearance of any new lesion, or an increase > 25% in CA19-9 for more than 6 weeks.

STATISTICAL METHODS

Progression-free survival and overall survival were measured in months from the start of chemotherapy. Survival estimates were made using the product-limit method. All analyses were performed with SAS version 9.1.

RESULTS

Twelve patients were treated with this regimen. The patient characteristics are shown in table 1. The median age of the patients was 56 years (range, 31 to 62 years). Of the 12 patients, 9 were females and 3 were males. 10 patients had cholangiocarcinoma and 2 had gallbladder cancer. All patients were chemotherapy naïve when starting the treatment. All 12 patients had metastatic disease on presentation. The most common site of metastases was liver (10/12) followed by local lymph nodes (5/12).

A total of 117 treatment cycles were delivered, with a range of 1-21 per patient. Based on the tumor marker CA19-9, 7 of the patients had a PR (7/12), including 3 patients who had normalization of CA19-9 (table 1). In seven patients who had sequential CT scan evaluations, the partial response rate was 43% (3/7) and two more patients had stable disease. One example of CT scan response is shown in figure 1. No CR was observed by CT scan criteria. The response duration or progression-free survival, from the time of initiation of chemotherapy to the time of documented tumor progression, was 13 months (Figure 2). Median survival from the date of starting chemotherapy was 17 months (Figure 3). Four patients had irinotecan dosage increased upon disease progression but no further responses were observed.

TOXICITY

The treatment was well tolerated as shown in table 2. No grade III or IV toxicity were encountered. We observed no toxicity greater than grade 1 diarrhea (4/12, 33%) and hand-foot syndrome (1/12, 7%). No patients received transfusion of blood products and no patients required hematopoietic growth factor support. Grade II anemia (2/12, 17%) and neutropenia (2/12, 17%) developed in a small proportion of patients. There was no formal quality of life assessment, but prompt (within first month of initiating treatment) pain relief or subjective improvement in overall well-being was documented in 10/12 (83%) patients.

DISCUSSION

Lin et al reported that concurrent use of Celecoxib with capecitabine could attenuate the toxicity and increase the tumor response.¹⁸ This report and the knowledge of COX-2 over expression in biliary cancers prompted the use of the above described treatment. In 2004, COX-2 inhibitors were linked to an increased cardiovascular risk¹⁹ causing difficulties in obtaining insurance company approval for Celecoxib renewal. The dosage used in our regimen (400 mg daily) is clearly linked to an increased risk of cardiovascular

events compared to placebo (hazard ratio of 3.0) in the colorectal adenoma prevention trial.²⁰ However, because of the grim prognosis of biliary cancer, this should not be an issue when used as a chemotherapeutic agent. Indeed, in our study, patients died of their cancer, and none had cardiovascular events related to the use of Celecoxib. Despite recent data from the human cholangiocarcinoma cell line (CCCLP1) supports the suppression of the COX-2 pathway as a therapeutic target,²¹ it is highly unlikely that a randomized trial will ever be carried out to test COX-2 inhibition in biliary cancers.

Irinotecan in combination with capecitabine at low dose is effective and deserves further evaluation. The low toxicity profile is related to the low dose of both irinotecan and capecitabine. The dose intensity of irinotecan in our regimen is 40 mg/m²/week which is less than 50% of the most commonly used irinotecan dose in the treatment of metastatic colorectal cancer (FOLFIRI with irinotecan at 180 mg/m² every two weeks or dose intensity of 90 mg/m²/week). It raises the question of whether a lower dose of irinotecan, with a much-improved tolerability, may also be effective for other tumors. Furthermore, we cannot rule out the possibility that Celecoxib attenuates the toxicity of chemotherapy.

The Capecitabine, irinotecan, and celecoxib regimen, with its low toxicity and long duration of disease control, is ideal for palliation. The risk for cardiovascular events and the increasing difficulty in obtaining insurance approval for Celecoxib could prevent further development of this regimen.

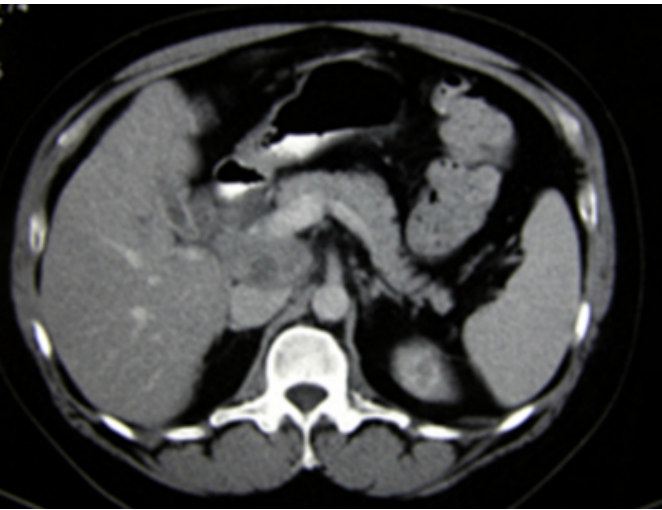
Figure 1

Figure 1a: CT response of one patient.

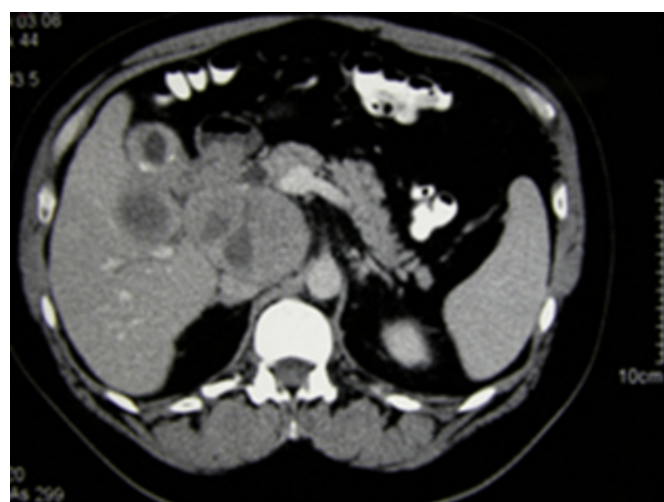

Figure 2

Figure 1b: CT response of one patient.

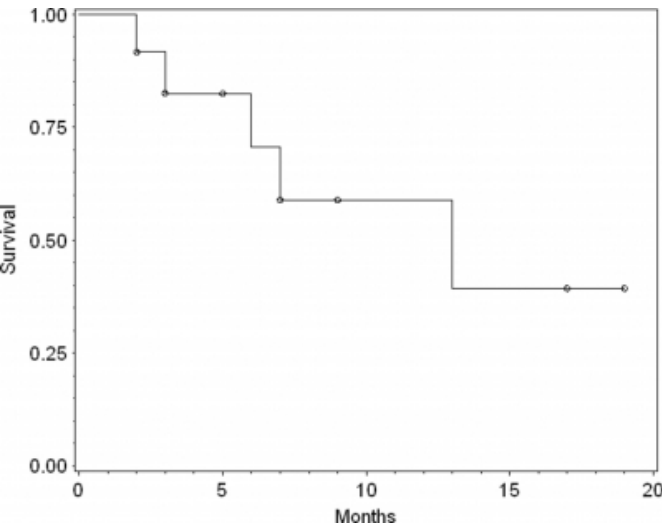


Before treatment showing large gallbladder mass with liver metastases.

B. 9 weeks after initiating treatment showing more than 50% reduction in the tumors.

Figure 3

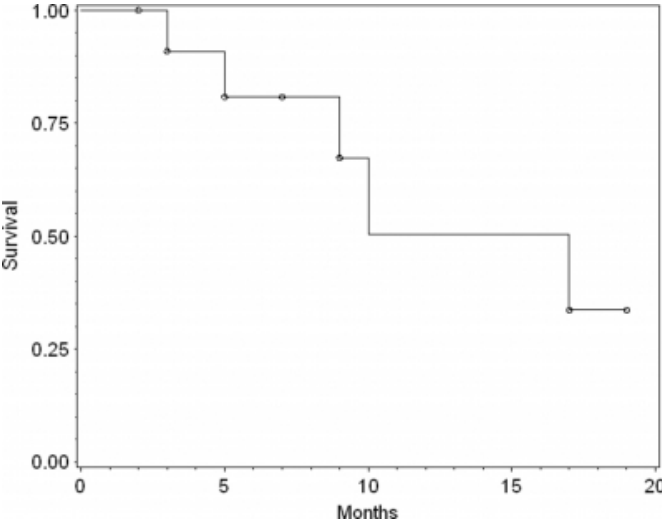
Figure 2: Progression-free survival after treatment for cholangiocarcinoma



Estimate of median time to progression from start of treatment is 13 months

Figure 4

Figure 3: Survival after treatment for cholangiocarcinoma



Estimate of median survival from start of treatment is 17 months

Figure 5

Table 1: Patients Characteristics

Age	Sex	Pathology	Metastatic sites	Pre-treatment CA19-9	Lowest CA19-9 achieved	% CA19-9 decline	Vital status at last follow-up	Survival in months from start of chemotherapy
62	F	Cholangiocarcinoma	Pentoneal carcinomatosis	6668.9	384	94.3	Died	3
59	F	Cholangiocarcinoma	Liver, peritoneum	4253.3	152.6	96.5	Alive	9
56	F	Cholangiocarcinoma	Regional lymph nodes	135	18.1	86.7	Alive	17
62	F	Cholangiocarcinoma	Liver, serosal implant	1362.7	263.9	80.1	Died	17
31	F	Cholangiocarcinoma	Liver, lymph nodes	6029	3301.4	45.3	Alive	5
56	F	Cholangiocarcinoma	Liver	294.9	166	43.8	Alive	7
58	M	Cholangiocarcinoma	Liver, peritoneum	4120.4	295.7	92.9	Alive	19
61	F	Cholangiocarcinoma	Liver, lymph nodes	86.9	7.3	91.6	Died	10
59	M	Cholangiocarcinoma	Liver	81.5	60.4	25.9	Died	9
49	F	Cholangiocarcinoma	Liver	60.6	37.3	37.9	Died	5
39	F	Gallbladder	Liver, lymph nodes	4190.2	6133	-31.7	Alive	2
48	M	Gallbladder	Liver, lymph nodes	47.3	13	72.6	Alive	3

Figure 6

Table 2: Toxicity

Toxicity	Grade		
	0	1	2
Diarrhea	8 (67%)	4 (33%)	0 (0%)
Hand-foot syndrome	11 (92%)	1 (8%)	0 (0%)
Anemia	4 (33%)	6 (50%)	2 (17%)
Neutropenia	9 (75%)	1 (8%)	2 (17%)

CORRESPONDENCE TO

Fa-Chyi Lee, MD UNM CRTC 900 Camino de Salud
Albuquerque NM 87131 e-mail: flee@salud.unm.edu

References

1. S Yalcin. Diagnosis and management of cholangiocarcinoma: a comprehensive review. *Hepatogastroenterology* 2004;51(55):43-50
2. WR Jarnagin, Y Fong, RP DeMatteo, et al. Staging, respectability, and outcome in 225 patients with hilar cholangiocarcinoma. *Ann Surg* 2001;234(4):517-519
3. VT DeVita et al. *Principle and Practice of Oncology* 2001. 6th edition, page 1184.
4. Taieb J, Mitry E, Boige V, et al. Optimization of 5-fluorouracil (5-FU)/cisplatin combination chemotherapy with a new schedule of leucovorin, 5-FU and cisplatin (LV5FU2-P regimen) in patients with biliary tract carcinoma. *Ann Oncol* 2002; 13(8):1192-1196
5. Lee MA, Woo IS, Kang JH, Hong YS, Lee KS. Epirubicin, cisplatin and protracted infusion of 5-FU (ECF) in advanced intrahepatic cholangiocarcinoma. *J Cancer Res Clin Oncol* 2004
6. EV Cutsem, M Findlay, B Osteralder, et al. Capecitabine, an oral fluoropyrimidine carbamate with substantial activity in advanced colorectal cancer: results of a randomized phase II study. *J Clin Oncol* 2000;18(6):1337-1345
7. Patt YZ, Hassan MM, Aguayo A, et al. Oral capecitabine for the treatment of hepatocellular carcinoma, cholangiocarcinoma, and gallbladder carcinoma. *Cancer* 2004;101(3):578-586

8. Knox JJ, Hedley D, Oza A, et al. Combining Gemcitabine and Capecitabine in Patients with Advanced Biliary Cancer: A Phase II Trial. *J Clin Oncol* 2005;23(1):2332-2338
9. Adjei AA, Klein CE, Kastrissios H, et al. Phase I and pharmacokinetics study of irinotecan and docetaxel in patients with advanced solid tumors: preliminary evidence of clinical activity. *J Clin Oncol* 2000;18(5):1116-1123
10. Ychou M, Conroy T, Seitz JF, et al. An open phase I study accessing the feasibility of the triple combination: oxaliplatin plus irinotecan plus leucovorin/5-fluorouracil every 2 weeks in patients with advanced solid tumors. *Ann Oncol* 2003;14(3):481-489
11. Kutomi G, Katsuramaki T, Mukaiya M, et al. Usefulness of low-dose irinotecan for multiple lung metastases of cholangiocellular carcinoma after operation-a case report. *Gan To Kagaku Ryoho* 2002;29(5):781-784
12. Chariyalertsak S, Sirikulchayanonta V, Mayer D, et al. Aberrant cyclooxygenase isoenzyme expression in human intrahepatic cholangiocarcinoma. *Gut* 2001;48(1):80-86
13. Wu GS, Zou SQ, Liu ZR, Wang DY. Bile from a patient with anomalous pancreaticobiliary ductal union promotes the proliferation of human cholangiocarcinoma cell via COX-2 pathway. *World J Gastroenterol* 2003;9(5):1094-1097
14. Han C, Leng J, Demetris AJ, Wu T. Cyclooxygenase-2 promotes human cholangiocarcinoma growth evidence for cyclooxygenase-2-independent mechanism in Celecoxib-mediated induction of P21waf1/cip1 and p27kip1 and cell cycle arrest. *Cancer Res* 2004;64(4):1369-1376
15. Nzeako UC, Guicciardi ME, Toon JH, Bronk SF, Gores GJ. COX-2 inhibits Fas-mediated apoptosis in cholangiocarcinoma cells. *Hepatology* 2002;35(3):552-559
16. Wu GS, Zou SQ, Liu ZR, Tang ZH, Wang JH. Celecoxib inhibits proliferation and induces apoptosis via prostaglandin E2 pathway in human cholangiocarcinoma cell lines. *World J Gastroenterol* 2003;9(6):1302-1306
17. Zhang Z, Lai GH, Sirica AE. Celecoxib-induced apoptosis in rat cholangiocarcinoma cells mediated by Akt inactivation and Bax translocation. *Hepatology* 2004;39(4):1028-1037
18. Lin EH, Morris J, Chau NK, et al. Celecoxib attenuated capecitabine induced hand-foot syndrome (HFS) and diarrhea and improved time to tumor progression in metastatic colorectal cancer (MCRC). *ASCO 2002 Annual Meeting abstract # 2364*
19. Finckh A, Aronson MD. Cardiovascular risks of cyclooxygenase-2 inhibitors: where we stand now. *Ann Int Med* 2005;142(3):212-214
20. Solomon SD, McMurray, Pfeffer MA, et al. Cardiovascular risk associated with Celecoxib in a clinical trial for colorectal adenoma prevention. *N Eng J Med* 2005;352(11):1071-1080
21. Han C, Wu T. Cyclooxygenase-2-derived prostaglandin E2 promotes human cholangiocarcinoma cell growth and invasion through EP1 receptor-mediated activation of epidermal growth factor receptor and Akt. *J Biol Chem* 2005;280(25):24053-24063

Author Information

Fa Chyi Lee

Division of Hematology Oncology, Cancer Research and Treatment Center, University of New Mexico

Gulshan Parasher

Division of Gastroenterology, Cancer Research and Treatment Center, University of New Mexico

Mary Roach

Division of Hematology Oncology, Cancer Research and Treatment Center, University of New Mexico

Curtis Hunt

Tumor Registry, Cancer Research and Treatment Center, University of New Mexico

Glenroy Heywood

Division of Surgical Oncology, Cancer Research and Treatment Center, University of New Mexico