

# Osseous Metaplasia In Adenocarcinoma Of The Rectum: A Case Report

S Agnihotri, N Sarma, N Jeebun, R Srivastava

## Citation

S Agnihotri, N Sarma, N Jeebun, R Srivastava. *Osseous Metaplasia In Adenocarcinoma Of The Rectum: A Case Report*. The Internet Journal of Gastroenterology. 2007 Volume 7 Number 1.

## Abstract

Osseous metaplasia is a rare feature to be seen in any type of tumor. Very few cases of osseous metaplasia in benign or malignant tumors of the gastrointestinal tract have been reported. Majority of these cases are mucin secreting adenocarcinomas. In all these cases osseous metaplasia is an incidental finding on microscopic examination and there are no specific clinical features or tests which will indicate osseous metaplasia. Etiopathogenesis of osseous metaplasia is not well known but Bone morphogenetic proteins(BMP) are known to play an important role in the pathogenesis of this condition. Awareness of this condition is necessary to avoid overdiagnosis of bone invasion in malignant tumors.

## INTRODUCTION

Necrotic areas of tumors often show dystrophic calcification, but mature bone formation also known as Osseous metaplasia or heterotopic bone formation is a rare phenomenon.

Osseous metaplasia refers to the formation of mature bone elements in the stroma of the neoplasm. This rare finding has been reported in both benign and malignant tumors of various organs. If malignant lesions only are to be considered osseous metaplasia has been observed mostly in adenocarcinomas occurring in the Gastrointestinal tract, lung, breast thyroid, parotid and pancreas<sup>1</sup>. Very few cases of adenocarcinoma of the rectum with osseous metaplasia are reported in the literature.

Although osseous metaplasia is clinically and prognostically insignificant and most of the times it is an incidental microscopic finding, yet the presence of bone fragments in a malignant tumor should be evaluated carefully before labeling the lesion as osseous metaplasia. Not much is known about the pathogenesis of osseous metaplasia though there are some evidences indicating the role of Bone morphogenetic proteins(BMP).

We present a case of adenocarcinoma of the rectum in an old lady with foci of osseous metaplasia and have reviewed the literature about osseous metaplasia in adenocarcinoma rectum.

## CASE REPORT

A 60 year old lady presented with bleeding per rectum and altered bowel habits of 2 months duration. The patient has lost weight recently. Routine investigations indicated iron deficiency anemia. Proctoscopy showed an irregular ulcerated mass in the rectum.

Preoperative CT Scan showed a 3X2 cms mass in the rectum invading the wall. Regional lymphnodes, adjacent viscera and liver did not show any sign of involvement. Anterior Posterior resection was performed and the tissue was sent for histopathological examination.

## GROSS APPEARANCE

The resected specimen consisted of part of sigmoid colon and rectum measuring 8X4X3 cms with perirectal fat covering. Cut surface showed an irregular ulcerated nodular mass of 2X1.5 cms in the rectum producing annular thickening of the wall producing the typical "Napkin ring" appearance. 10 Lymphnodes were identified in the perirectal fat. Sections were taken from the representative areas of the mass and all the 10 lymph nodes for HPE.

## MICROSCOPIC EXAMINATION

Sections from the growth showed the typical features of mucin secreting and infiltrating adenocarcinoma of the rectum. The tumor tissue is seen invading the wall and reaching the serosa at places. All the lymphnodes examined showed only reactive hyperplasia. In the wall of the rectum

where the tumor islands were seen invading, foci of osseous metaplasia were identified. These foci of mature bone were seen in the stroma surrounded by the tumor cells (Fig 1 and 2).

Figure 1

Figure 1: Low power view of Adeno carcinoma of the rectum with a focus of osseous metaplasia. H & E 10X

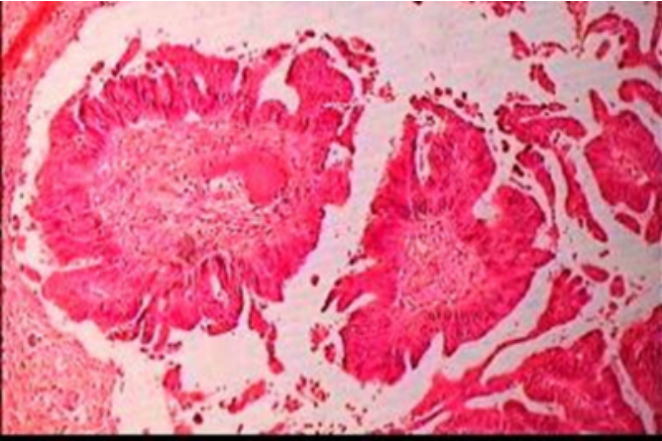
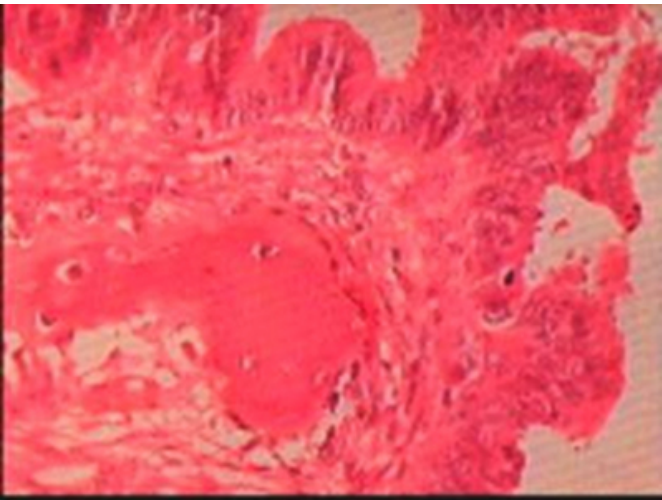


Figure 2

Figure 2: Higher power view showing the focus of osseous metaplasia with in a malignant glandular stroma.H & E 20 X



The tumor is seen mostly in the submucosa and at places invading through the muscularis propria.

In view of the presence of bony spicules with in the tumor the report was sent as Osseous metaplasia in well differentiated adenocarcinoma. The clinician was requested to look for direct invasion to pelvic bones. CT scan was done which did not show any evidence of tumor invasion of the adjacent pelvic bone.

DISCUSSION

Osseous metaplasia or heterotopic bone formation in adenocarcinomas of the GIT is considered as a rare event. Very few cases are reported so far in the literature and it is mostly considered as histopathological curiosity ( Table)

Figure 3

Table 1: Published cases of osseous metaplasia in colorectal carcinoma

References	Year	Age/ Sex	Primary site	Metastasis	Site of OM
Caluori et al <sup>2</sup>	1979	83/F	Sigmoid Colon	Lymph nodes	Primary & Lymph nodes
Byard et al <sup>1</sup>	1988	72/M	Rectum	No	Primary
Randall et al <sup>3</sup>	1989	69/M	Transverse colon	Lymph nodes	Lymph nodes
Lauwers et al <sup>4</sup>	1991	52/M	Rectum	Hepatic	Primary
Ansari et al <sup>5</sup>	1992	52/F	Rectum	No	Primary
Arnal Monveal et al <sup>6</sup>	1992	48/M	Rectum	No	Primary
		72/M	Sigmoid Colon	Lymph nodes	Primary
Valenska et al <sup>7</sup>	1993	62/M	Rectal	Pulmonary	Pulmonary
Papadopoulos et al <sup>8</sup>	1997	47/F	Caecum	Hepatic	Primary

Foci of ossification in rectal carcinoma was described by Dukes in 1939 for the first time in the English literature. The overall incidence of osseous metaplasia in malignant tumors is 0.4% approximately as suggested by Dukes<sup>9</sup>. Ossification can occur in both neoplastic and non neoplastic lesions of the GIT like in colonic polyps, mucocoele of the appendix, gastric carcinoids and adenocarcinomas<sup>5,10,11</sup>. Osseous metaplasia is seen more commonly in lower gastrointestinal tract lesions with rectum being the most common site. However cases have been reported from sigmoid, transverse colon and caecum also<sup>8</sup>. The average age of these patients was 56 yrs (range 36-72) and male to female ratio was 5:7<sup>5</sup>. Heterotopic bone formation is usually observed in tumors producing abundant mucin<sup>10</sup>. It is speculated that the extravasation of mucin may have a stimulatory role in ossification<sup>12</sup>.

Various studies have hypothesized that the Bone Morphogenic Proteins (BMP) play an important role in osseous metaplasia in colonic adenocarcinoma. Rhone and Horowitz<sup>13</sup> postulated that ossification might result from metaplasia of pluripotent mesenchymal cells into osteoblasts. Imai et al<sup>14</sup> studied the immunohistochemical expression of BMP in colonic carcinomas and found that BMP-5 and BMP-6 were prominent in the cytoplasm of the tumor cells, but were weakly expressed in the osteoblast like cells adjacent to the nearby bone. BMP-2 and BMP-4 were strongly expressed in the surrounding mesenchymal cells and weakly expressed in the tumor cells and osteoblast like cells. This pattern suggests that the tumor cells mainly produce BMP-5 and BMP-6 which may induce proliferation of surrounding mesenchymal cells into preosteoblast and

osteoblast expressing BMP-2 and BMP-4.(12).BMP-2 and BMP-4 are potent inducers of osteoblastic differentiation when compared with other BMPs <sup>15</sup> .

### CONCLUSION

Osseous metaplasia which is a very rare phenomenon may occur in both benign and malignant lesions of the GIT.The course and prognosis of adenocarcinoma with osseous metaplasia does not differ from that of adenocarcinoma without osseous metaplasia.Most of the times osseous metaplasia is an incidental finding on microscopic examination.Whenever mature bone fragments are found in the tumor tissue osseous metaplasia should be considered only after excluding invasion of adjacent bony tissue to the organ.The exact mechanism of osseous metaplasia is not known , but the recent evidences point out the role of BMPs.

### References

1. ByardRW,ThomasMJ. Osseous metaplasia with tumors:a review of 11 cases. Ann Pathol.1988;8:64-66.
2. Caluori D, Gallo P. Case report of heterotopic bone formation in metastatic carcinoma of the colon. Tumori 1979 June; 65:345-51.
3. Randall JC, Morris DC, Tomita T, Anderson HC. Heterotopic ossification: a case report of immunohistochemical observations. Hum Pathol. 1989 Jan; 20(1):86-8.
4. Lauwers GY, Wahl SJ, Richard Gk. osseous metaplasia in colonic adenocarcinoma. Am J Gastroenterol 1991 March; 86(3): 382-4.
5. Ansari MQ,Sachs IL,Max E,Alpert LC. Heterotopic bone formation in rectal carcinoma. Case report and literature review. Dig Dis Sci 1992;37:1624-9.
6. Arnal Monreal F, Lorenzo Patino MJ, Alvarez Garcia A. Bone metaplasia in carcinoma colorectal. Rev Esp Enf Digest 1992 August; 82(2) : 121-2.
7. Velenska Z, Povysil C, Skacel Z. Heterotopic ossification in endobronchial metastases of rectal adenocarcinoma. Cesk Patol 1993 Feb;29(1):30-1.
8. Papadopoulos MC, Weston J, Ball AB. Osseous metaplasia in caecal adenocarcinoma. J R Soc Med. 1998 August; 91(8):434-5.
9. DukesCE:Ossification in rectal cancer.Proc R Soc Med.1939;32:1489-94.
10. Haque S, Eisen RN, West AB. Heterotopic bone formation in the gastrointestinal tract.Arch Pathol Lab Med. 1996 July;120(7):666-70.
11. NaritaT,OhnumaH,YokoyamaS. Peutz-Jeghers syndrome with osseous metaplasia of the intestinal polyps.Pathol Int 1995 May 45(5):388-92.
12. AlperM,AkyurekN,PatirogluTE,YukselO,BelenliO.Scand j gastroenterol. 2000;35:556-8.
13. RhoneDP,HorowitzRN:Heterotopic ossification in the pulmonary metastases of gastric adenocarcinoma: report of a case and review of the literature. Cancer.1976;38:1773-80.
14. ImaiN,IwaiA,HatekeyamaS etal:Expression of bone morphogenic proteins in colon carcinoma with heterotopic ossification.Pathol Int.2001 August; 51(8):643-8.
15. YamaguchiA,IshizuyaT,KintouN etal:Effects of BMP-2,BMP-4 and BMP-6 on osteoblastic differentiation of bone marrow derived stromal cell lines,ST2 and MC3T3-G2/PA6.Biochem Biophys Res Commun.1996 March; 220(2):366-71.

**Author Information**

**Smitri Agnihotri, M.D.**

Reader, Department of Pathology, SSR Medical College

**N. Hariharanadha Sarma, M.D.**

Professor & HOD, Department of Pathology, SSR Medical College

**Nilima Jeebun, M.D.**

Associate Professor, Department of Pathology, SSR Medical College

**Rama Srivastava, M.D.**

Reader, Department of Pathology, SSR Medical College